Microbiology

Answer Papers

PROFESSOR & HOD
Department of Medical Microbiology
Sri Venkateswara Dental College & Hospital
Chennai - 600 130

21/30

M.G. Hamed Ibrahim

1. ~~Morp~~ Morphology, pathogenesis laboratory diagnosis and prophylaxis of clostridium tetani

C tetani is the Causactive ~~org~~ organism of tetanus.

tetanus has been known since very early times

Morphology

Gram positive, slender bacillus, about 4-8 x 0.5 μm in size

the spores are spherical, terminal and bulging, giving the bacillus the characteristic 'drumstick appearance'

Certified

pathogenesis

PRINCIPAL
SRI VENKATESWARA DENTAL COLLEGE & HOSPITAL
OFF. OMR NEAR - NAVALUR
THALAMBUR, CHENNAI-600 130.

Mech of Action

- Tetatonospasmin assembles strychnine in its effects

- it blocks synaptic inhibition in the spinal cord, ~~pop~~

→ the toxin act postsynaptically

→ this results in muscle rigidity and spasms due to the simultaneous contraction of agonists and antagonist in the absence of reciprocal inhibition

Lab diagnosis

- the diagnosis of tetanus should always be made on clinical grounds.
- Lab test only help in confirmation

Microscopy

Demonstration of the typical 'drumstick' bacilli in wound in itself is not diagnosis of tetanus

for in vitro identification and toxigenicity testing, blood agar plates spread over one half of the plate are used.

Prophylaxis

→ It is a preventable disease.

→ Surgical

Aims at removing foreign body, necrotic tissue and blood clots, to prevent an Anaerobic environment favourable for the tetanus bacillus

→ Antibiotics

Aim at destroying or inhibiting tetanus bacilli and pyogenic bacteria in wound so that the production of toxin is prevented.

→ Immunization

Passive immunization

is by injection of tetanus antitoxin. Anti-tetanus Serum from hyperimmune horses was the preparation originally used.

the dose employed was 1500 IU given subcutaneously or intramuscularly in non-immune person soon after receiving any tetanus prone injury.

Active immunization

is not only the most effective method of popoplyaxis but also the only means whereby persons following wounds injuries can be protected.

This is achieved by subcutaneous injections of formol toxoid, which is available either as plain toxoid.

Certified

A. Muthu

PRINCIPAL
SRI LENKATESWARA DENTAL COLLEGE & HOSPITAL
OFF. OMR NEAR NAVALUR
THALAMBUR, CHENNAI-600 130.

Short Notes

1. Viridans streptococci

it is a miscellany of streptococci normally dependent in the mouth and upper respiratory tract and typically producing greening on blood agar

they are ordinarily non-pathogenic but can on occasion cause disease.

In persons with pre existing cardiac disease, they may cause bacterial endocarditis. S. sanguis being most often responsible.

following tooth extraction or other dental procedures, they can trangle at bacteremia and get implanted on damaged or prosthetic valves or in a congenitally diseased heart and go on to form vegetation.

Prophylactic antibiotic cover is advisable in such persons before tooth extraction or similar procedures

1. Gonorrhea

- Bacterial infection caused by Neisseria gonorrhea causes Urogenital Anorectal.

- Urogenital tract infection are most common.

Risk factors for Gonococcal infection

Adult:
- Age younger than 25 yrs
- Black race
- History of gonococcal infection
- prostitution
- substance Abuse

Children
- Mothers with a history of STI or substance Abuse
- Mothers without prenatal care.
- Sexual Abuse.

Lab diagnosis

- Gram stain of a Urethral smear or cervical swab showing Gram negative intracellular diplococci

Treatment

→ patients sex partners within 60 days before symptom onset should also be treated

→ fluoroquinolones are not recommended in the US for treatment of Gonorrhea

---

8. Drug resistance

- though occasional resistant strains had been identified in the laboratory, resistance to chloramphenicol did not pose any problems in typhoid fever till 1972; when resistant strains emerged in Mexico and in Kenya.

In India, chloramphenical resistant typhyoid fever appeared in epidemic form first in Calcutta in early 1972.

By date 1980s. typhoid bacillus strain resistant to many or all of these drugs began to spread to most part of India.

The drugs useful in the treatment of such multi resistant typhoid cases were the later fluoroquinolones and the third generation cephalosporins ceftriaxone is still active against most isolates. Now several isolates of typhoid bacilli are once again sensitive to chloramphenicol.

Anaphylaxis

Anaphylaxis is acute potentially fatal systemic type I reaction

Features

Antigen e hapten can induce Anaphylaxis

Pathophysiology

First the body is sensitized when the drug is contacted with allergen / antigen

Lab diagnosis

Microscopy. D

5. Non Sporing Anaerobes

Anaerobes

Are bacteria which are able to live in aplatives or total Absence of oxygen.

Non Sporing Anaerobes

classified on the basis of DNA Base composition and Analysis of fatty acid prpoduct metabolism

classification

Cocci

Veillonella

Bacilli

Gram (+)

→ Eubacterium
→ Lactobacillus

Gram (−)

→ Bacteroids
→ Prevotella

Spirochetes

Treponema
Borrelia

Pathogenesis

- loss of integ of EM
- Concomitant bacterial infection

Virulence factors

- toxins
- enzymes
- Capsule

Disease produced by non sporing Anaerobes

- female genital tract infections
  - *) Vaginitis
  - *) Bartholin's Abscess
  - *) puerperal Sepsis
  - *) PIDS
- Abdominal infection
  - *) Appendicitis, SSIs, peritonitis
- ENT infection
  - otitis media, mastoiditis, Sinusitis
- orodental infection
  - Gingivitis
  - periodontal infections.

→ they are double stranded and in many ones, circular. plasmids usually occur naturally in bacteria but sometimes found in eukaryotic organisms.

5) widal test

→ typically, patient serum is diluted into a series of tubes or wells on a slide and reacted with bacterial antigen specific for the suspected disease.

→ the test measure agglutinating antibodies directed against a Salmonella somatic surface antigen and/or an H flagella antigen of the suspected organism

III. Short Answer

1) IgM

- Accounts for 5-10% of total Serum proteins
- polymer of five monomeric Units
- Half life: 5 days

function

- Agglutinates bacteria
- Causes opsonization and minimum Haemolysis

2) psychrophilic bacteria

- psychrophilic are extremophilic organisms that are capable of growth and reproduction in low temperatures ranging from -30°C to 10°C.
- they are found in places that are permanently cold.

3) plasmids

- A plasmid is a DNA molecules that is separate from, and can replicate independently of the chromosomal DNA.

Microbiology

PROFESSOR & HOD
Department of General Microbiology
Vivekanandha Dental College & Hospital
Chennai 600 103

AGALYA · J

20/30

① Clostridium tetani:

Causative Organ for tetani.

Morphology:-

* Gram positive bacillus
* Slender bacillus. It has straight across, parallel sides and rounded ends.
* Drumstick like appearance
* Non capsulated Ends & Motile.

Pathogenesis:-

Mechanism of action:-

Tetanospasmin.
(Tetanus toxin)
↓
Blocks synaptic Inhibition in spinal cord
↓
Toxin acts presynaptically.
↓
Abolition of final inhibition

↓
Uncontrolled spread of impulse anywhere in CNS

↓
Muscle rigidity and spasms

↓
In absence of reciprocal Inhibition

Laboratory Diagnosis :-

- Macroscopically - Drumstick appearance.
- Culture : One half of blood in agar plate.

↓
Clostridium tetani produces swarming growth detected in another half

- Invivo :

Toxigenicity Testing
- Blood agar plates having tetanus antitoxin spread over one half of the plate.

- Invivo toxigenicity :

* It is best tested in animals @ 2 - 4 days cocoon meat culture Inoculated

Prophylaxis :-

It is a preventable disease.

Surgical :-

* Removing - necrotic tissues
  - Foreign bodies
  - Blood clot to prevent an anaerobic environment.

Antibiotics :-

Aim at destroying (or) inhibiting tetanus bacilli and pyogenic bacteria.

- Immunization :-

Passive Immunization :-

Is by injection of tetanus antitoxin - Anti tetanus serum from hyperimmune horses. way the preparation originally used

The dose employed was 1500 IU given subcutaneously and intramuscularly in non-immune person soon after recovery. any tetanus prone injury.

Active Immunization:

* It is not only the most effective method of prophylaxis but also the only means whereby tetanus following wounded injuries can be prevented.

* This is achieved by spaced injections of formed toxoid, which is available either as a plain toxoid

---

Short notes

① Viridans Group:

* Also called Streptococci Viridans

Seen in (i) Upper respiratory tract
(ii) mouth

→ ~~(iii)~~ alpha lysis

Morphology:

* Nonpathogenic

→ In persons with pre cardiac lesion may cause

Risk factors for Gonoccal infection

Adults:
- Ages younger than 25 years
- Black race
- History of Gonococcal infection
- Prostitution
- Substance abuse

Children:
- Mothers with a history of sexual substance abuse
- Mothers without prenatal care
- Sexual abuse

Lab diagnosis

Gram stains of a urethral smear or cervical swab showing gram negative intracellular diplococci

Treatment

Patient to sex partners within 60 days before symtom observed should be treated.

* Flouroquinolones are not given in US for the treatment of Gonorrhea.

endocarditis

* Tooth Extraction / Other dental procedures can lead to bacteremia.
* Prophylactic antibiotic coverage is available.
* Streptococcus mutans - is an alpha hemolytic streptococci
  * seen in mouth.
  * Gram positive.
  * The bacterium has a polysaccharide coat that allows it to stick to tooth and also to the damaged heart valves which can lead to blood block.
  * It also produces acid from sugar in saliva.
  * It is prevented by good oral hygiene & antibiotic prophylaxis.

---

(2) Gonorrhea :-

Bacterial infection caused by Neisseria gonorrhea causes urogenital gonococcal

* urogenital tract infection are most common.

3) Drug resistance :-

PROFESSOR & HOD

Though occasional resistant strains had been identified in the laboratory, resistance to chloramphenicol did not pose any problems in typhoid fevers, when resistant strains emerged in Mexico & in Kerala

In India, chloramphenicol resistant typhoid fever appeared in epidemic form first in ~~Calcutta~~. Calcutta to many (or) all of these drugs began to spread to most part of India.

The drugs useful in the treatment of such multi resistant typhoid cases were the new fluoroquinolone and the third generation cephalosporins.

Thiazolidone is still active against most isolates. Now several isolates of typhoid bacilli are once again sensitive to chloramphenicol.

(4) Anaphylaxis

Anaphylaxis is acute potentially fatal systemic type I reaction

features:

Antigene haptem can induce anaphylaxis.

Pathophysiology:

Just the body is sensitized when there is contacted with allergen / Antigen.

---

(5) Non Spoing Anaerobes:

Classified on the basis of DNA. Base composition and analysis of fatty acid product metabolism.

Classification:

(i) Cocci

- Vellonella

(ii) Bacillin

(a) Gram (+ve)

- Eubacterium
- Lactobacilles.

(b) Gram (-ve)

- Bacteriodes.
- Peovotella.

Short answers

II.

1) Ig M :

* Accounts for 5-10% of total serum proteins.
* Polymer of five monomeric units.
* Half life : 5 days

Function :

- Agglutinates bacteria.
- Causes opsonization and minimum haemolysis.

---

(2) Psychophilic bacteria :

* They found in the places that are permanently cold.
* Extremophilic organisms that are capable of growth at (-30° to 10°C) low temperature.

(3.) Plasmid :

A plasmid is a DNA molecule that is separate from and can replicate independently

Classifications:-

Plasmids < Self transition
Non transition.

---

(5) Widal test :-

Patient serum is diluted into a series of tubes (or) wells on a slide and reacted with bacterial antigens specific for the suspected disease.

→ The tests measure agglutinating antibodies directed against a Salmonella osomatic.

PROFESSOR & HOD
Department of Mineral Microbiology
SRI Venkateswara Dental College & Hospital
Chennai 600 103

13/30

Micro Biology :

Shiva Priyadharshan.

II year.

1) clostridium tetani : It is causative agent for Tetanus

Morphology :

- Gram positive bacteria
- Slender bacillus
- It has straight axis, parallel sides and rounded ends.
- Drumstick like appearance.
- It is non-capsulated and motile.

Pathogenesis

Telanospasmin

(tetanus toxin)

⇓

Blocks synaptic inhibition in spinal cord

⇓

Toxin acts presyphically

⇓

Abolition of spinal inhibition

↓

Uncontrolled Spread of impulses anywhere in CNS

↓

Muscle rigidity & Spasm

↓

In absence of reciprocal inhibition.

Lab diagnosis

Microscopy : Drumstick appearance.

Culture : One half of the blood in agar plate

↓

Clostridium tetani produces Swarming growth

↓

diluted in other half after 1-2 days.

of anaerobic incubation

Invitro

- Toxigenicity testing
- Blood agar plate having tetanus antitoxin

Spread over one half of the plate.

Invivo

Is best tested in animal

A 2-4 day old cooked meat culture is inoculated.

Prophylaxis:

It is a preventable disease.

i) Surgical

-> Removing - foreign bodies
Necrotic tissues
Blood clots.

to prevent anaerobic environment.



Immunization:

Passive immunization - injection of tetanus antitoxin.

Antitetanus Serum - hyperimmune horses - 1500 IU

Subcutaneous.

Active immunization: plain toxoid, triple vaccine.

Shocks

i) Anaphylaxis:

Anaphylaxis is a acute, potentially fatal systemic type I reaction (Ig E dependent).

It is the classical immediate hypersensitivity reaction

Features

Antigens & haptens can induce Anaphylaxis.

Pathophysiology

-> First, the body is sensitized, When there is contacted with allergens / Antigens. It doesnot cause.

any reaction.

Sensitization Stage.

Antigen (allergens) invades body

↓

Plasma cell produce large amount of class Ig E antibodies against allergens.

↓

IgE antibodies attach to mast cell in body.

↓

Mast cell degranulates releases

↓

- Histamines
- Leukotriches
- Eosinophil chemotactic factor
- Slow reacting substance of Anaphylaxis (SRS-A).

↓

Involvement of skin (rashes)

Bronchoconstriction.

Treatment

Antihistamines Administration (25mg of diphenhydramine)

H_1 blockers.

Oxygen

Inhaled b-adrengic agents.

Streptococcus Viridins:

It a gram positive & facultative anaerobes.

They occur in pairs or short & long chains.

It is normally resident in mouth & upper respiratory tract & typically producing alpha lyses on blood agar.

They produce dextrans & levans Viridans are usually Penicillin Sensitive.

2) Gonorrhea:

Neisserhia Gonorrhea Causes Sexually transmitted disease gonorrhea.

Incidence highest among addescents & young adults.

Symptoms:

Burning sensation on urination.

Pus like creamy White or yellowish discharge from penis

Presence of unusual vaginal discharge.

Backache

Vaginal bleeding

Pain in lower abdomen

They usually appear within 2 to 7 days of infection & but this can take up to 30 days.

Complications

Infertility

Epididymitis

Pelvic Inflammatory diseases

Pregnancy morbidity.

→ proctitis.

Diagnosis of gonorrhea by Smear exam.

Demonstration of intracellular Gram negative diplococci

Selective culture medium

→ thayer - martin medium containing Vancomycin, Colistin & Nystatin.

Treatment

- Antibiotics like ampicillin or amoxicillin.
- use protective agent during sexually enter course.

5) Non- Sporing Anaerobes:

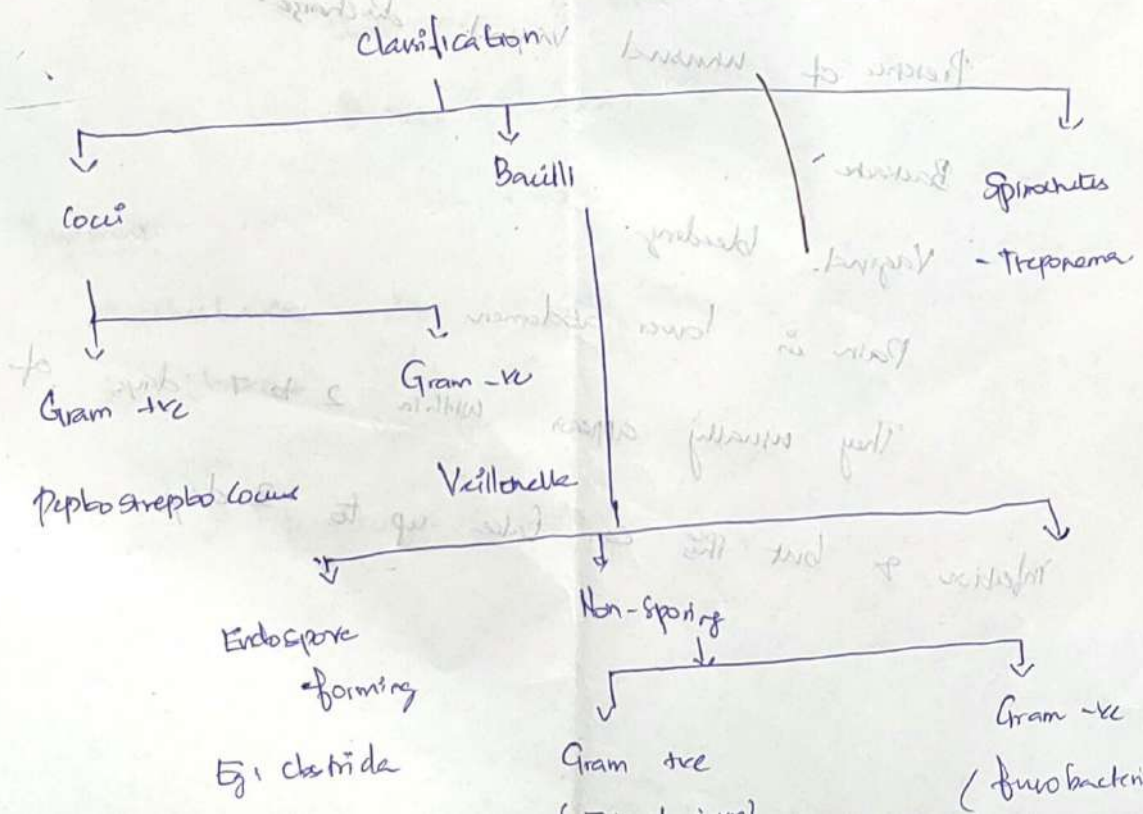

Microbiology

1) **Clostridium Tetani**: Causative Organ for Tetanus

Morphology:

- Gram positive bacillus
- Slender bacillus. It has straight access, parallel sides and rounded ends.
- Drumstick like appearance.
- Non capsulated ends. Eg Motile.

Pathogenesis:

Mechanism of action:

Tetanospasmin
(Tetanus toxin)
↓
Blocks synaptic inhibition in spinal cord
↓
Toxin acts presynaptically.
↓
Abolition of neural inhibition
↓
Uncontrolled spread of impulses anywhere in CNS
↓
Muscle rigidity and spasms.
↓
In absence of reciprocal inhibition

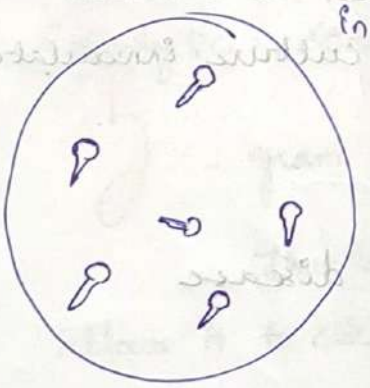

Laboratory diagnosis :

Microscopically - drumbstick appearance

culture - one half of blood in agar plate

↓

Clostridium tetani produces swarming growth deducted in another half after 1-2 days. of anaerobic inhibition

Invitro : Toxigenicity testing

- blood agar plates having tetanus antitoxin spread over one half of plate.

Invivo toxigenicity :

It is best tested in animals a 2-4 day coccoon meat culture innoculated.

Prophylaxis :

It is a preventable disease

Surgically :

Removing foreign bodies, necrotic tissues, blood clots to prevent anaerobic environment.

Short notes:

1. Viridians streptococci:

- It is also called streptococcus viridians seen in i) upper respiratory tract
ii) Mouth
iii) Alpha lyses.

Morphology

Non pathogenic

- In persons with precardiac lesion. may cause endocarditis other dental procedure can lead to bacteriemia.

- Prophylactic antibiotic covera is available.

Streptococcus mutans

- Streptococcus mutans is an alpha Hemolytic Streptococci seen in mouth

- gram positive

The bacterium uses polysaccharide coat that allows it to stick to tooth and also to the damaged heart valves which can lead to blood block.

It also produces acid from sugar and saliva.

It is prevented by good oral hygiene and antibiotic prophylaxis.

Antibiotics :

Aim at destroying or inhibiting tetanus bacilli and pyogenic bacilia

Immunoglobulin -

Passive immunization :- Is by reception of tetanus antibiotics serum for hyperimmune horses was the preparation originally used. The dose employed was subcutaneously and Intramuscularly In non immune person after recieving any tetanus prone injury.

Active Immunisation :

It is not only most effective method of prophylaxis but also the only means by tetanus following and unnoticed injuries can be prevented.

This is achieved by spaced injections of formed toxoid, which is available as plain toxoid.

Treatment

+ H2 blockers.

2. Gonorrhea :

- Bacterial infection caused by Neisseria gonorrhea causes urogenital anorectal
- urogenital tract infections are most common.

Risk factors of gonococcal infections

Adults :

- Age younger than 25 years
- black race
- History of gonococcal infections
- Prostitution
- Substance abuse

Children :

- Mothers with history of sex or substance abuse.
- Mothers without prenatal care.
- Sexual abuse

Lab diagnosis

- Gram staining of urulent- or cervical swab showing gram negative intracellular diplococci.

Treatment:

patient to sexc partners within 60 days before symptom observed should be treated. with fluroquinolones are not given in US for treatment of gonorrhea.

4. ANAPHYLAXIS

Anaphylaxis is acute, potentially fatal systemic type I hypersensitivity reaction (IgE dependant).

It is the classical immediate hypersensitivity reaction.

-Features

Antigens & haptens can induce anaphylaxis.

Pathophysiology

First, the body is sensitized when there is contacted with allergens/antigens

It does not cause any reaction.

PROFESSOR
Department of General
Madras Medical College
Chennai 600 003

Sensitization stage:

Antigen (allergens) invades body

↓

Plasma cell produce large amount of class IgE antibodies against allergens

↓

IgE antibodies attach to Mast cells in body.

↓

Mast cell degranulates releases

↓

Histamine
Leukotrienes
Eosinophil Chemotactic factor
Slow reacting substance of anaphylaxis (SRS-A)

↓

Involvement of skin (rashes)

Bronchoconstriction

Treatment:

1. Antihistamines administration (25mg of diphenhydramine)
2. H_2 blockers
3. oxygen
4. Inhaled β-adregenic agents.

3. Drug Resistance:

Though occasional resistant strains had been identified in laboratories.

Resistance to chloramphenicol did not pose any problems in typhoid fever when resistance strain emerged in mexico and canada.

In India, Chloromphenicol resistant typhoid fever appeared in epidemic form first at calcut.

Typhoid bacillus strain resistant to many or all of these drugs began to spread in most part of India

Drug useful in treatment of such multi resistant typhoid cases where we have fluroquinolones and 3rd generation cephalosporins.

Fluroquindones is still active against most isolates.

Now several isolates of typhoid bacilli are once again sensitive to chloromphenicol.

5. Non sporing anaerobes:

classified on the basis of DNA based composition and analysis of fatty acid product metabolism.

Classification

i) Cocci
- Vellomilla

ii) Bacillus
gram +ve
gram -ve.

gram +ve
- Eubacterium
- Lactobacillium

gram - ve
- Bacteriodes
- Prevotella

Short Answers:

1) IgM:
- Accounts of 5 - 10% of total serum Proteins.
- Pentamer of five monomeric units
- Half life - 5 days

Function:

- Agglutinates bacteria.

Causes

Opsonisation and minimum haemoglobin.

2. Cycrophilic bacteria

- They are found in placed permeable to cold.

- Cycrophilic bacteria are extremophilic organisms that are capable of growth.

- Found in places that are permanently cold (+30° to +10°C)

3. plasmid

- A plasmid is a DNA molecule that is seperate from and can replicate independently.

Plasmid → self transmissable
→ Non transmissable

PROFESSOR & HOD
Department of Clinical Microbiology
VIII Vaikeresvara Dental College & Hospital
Chennai 603 103

4. Coagulase test :

5. Widal test :

- Typically patients serum is diluted into a serious of tubes, on a slide and reacted with bacterial antigens specific for suspected disease.

- The test measures agglutinating antibodies directed against salmonella or osmotic.

Microbiology

Aakthy. G

19/2/20

1) Clostridium Tetani.

It is a Gram positive, Anaerobic spore forming Bacilli.

→ It has characteristic drumstick appearance on gram stain.

→ It is caused agent of tetanus.

→ It is usually present in soil.

→ It is usually ~~tra~~ transmitted through the injuries, road accidents, etc.

Cultural characteristics

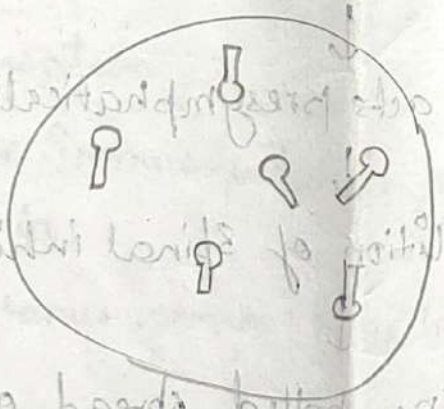

Clostridium tetani.

Optimum temperature : 37°C

PH : 7.4.

Oligate Anaerobe.

Cultural Medium : Robertson's cooked meat Broth.

Toxins produced by clostridium tetani:

C. tetani

- Tetanolysin (hemolysin) (Heat labile, oxygen labile hemolysin)
- Tetanospasmin (Neurotoxin) → Responsible for Tetanus

Pathogenesis.

Tetanospasmin
↓
Blocks synaptic inhibition in spinal cord.
↓
Toxin acts presymphatically
↓
Abolition of spinal inhibition
↓
Uncontrolled spread of impluses anywhere in CNS
↓
Muscle rigidity & Spasms
↓
In Absence of reciprocal inhibition.

Laboratory diagnosis

→ Microscopy: Demostration of typical 'drumstick' bacilli.

→ culture test is more dependable. Isolation from excised bits of tissues from necrotic depths of wounds.

→ Toxigenicity testing, invitro identification.

→ In vivo toxigenicity.

Prophylaxis

Surgical prophylaxis: Aims at removing foreign body, necrotic tissue & blood clots.

Antibiotic prophylaxis: Long acting penicillin injection is drug of choice.

Immunisation

Passive immunisation - injection of tetanus antitoxin.

Antitetanus serum from hyperimmune horses - 1500 IU Subcutaneous.

↓

Active immunisation: Plain toxoid, triple vaccine.

Short Notes

4) Anaphylaxis.

Anaphylaxis is acute, potentially fatal systemic type I reaction (IgE dependent).

It is the classical immediate hypersensitivity reaction.

Features

Antigens & haptens can induce Anaphylaxis.

Pathophysiology

* → first, the body is sensitized. When there is contacted with allergens / Antigens. It doesn't cause any reaction.

* Sensitization stage

Antigen (allergens) invades body

↓

Plasma cell produce large amounts of class IgE antibodies against allergens.

↓

IgE antibodies attach to mast cells in body.

↓

↓

Mast cell degranulates releases

↓

Histamine
leukotrienes
Eosinophil chemotactic factor
Slow reacting substance of
Anaphylaxis (SRS-A)

↓

Involvement of skin (rashes)
Bronchoconstriction.

Treatment.

Antihistamines Administration (25mg of diphenhydra. 5min)
H_2 Blockers.
Oxygen.
Inhaled β-adrenergic agents.

1) Streptococcus viridins.

It is gram positive facultative anaerobes.
They occur in pairs or short & long chains.
It is normally resident in the mouth & upper respiratory tract & typically producing alpha lysis on blood agar.

They produce dextrans & levans.

Viridans are usually penicillin sensitive.

2) Gonorrhea..

Neseria Gonorrhea causes sexually transmitted disease gonorrhoea.

Incidence highest among adolescents & young adults.

Symptoms: Burning sensation on urination.

Pus like creamy white or yellow discharge from penis.

Presence of unusual vaginal discharge.

Backache

Vaginal bleeding

Pain in lower abdomen.

They usually appear within 2 to 7 days of infection & but this can take up to 30 days.

Complications

- Infertility
- Epididymitis
- Pelvic Inflammatory disease.
- Pregnancy morbidity.
- Proctitis.

Diagnosis of gonorrhea by smear exam.

Demonstration of intracellular Gram negative diplococci.

Selective culture Medium

→ thayer-Martin medium containing Vancomycin, colistin & Nystatin.

Treatment

→ Antibiotics like ampicillin or amoxicillin.

→ Use protective Agent during sexual intercourse.

5) Non-sporing Anaerobes.

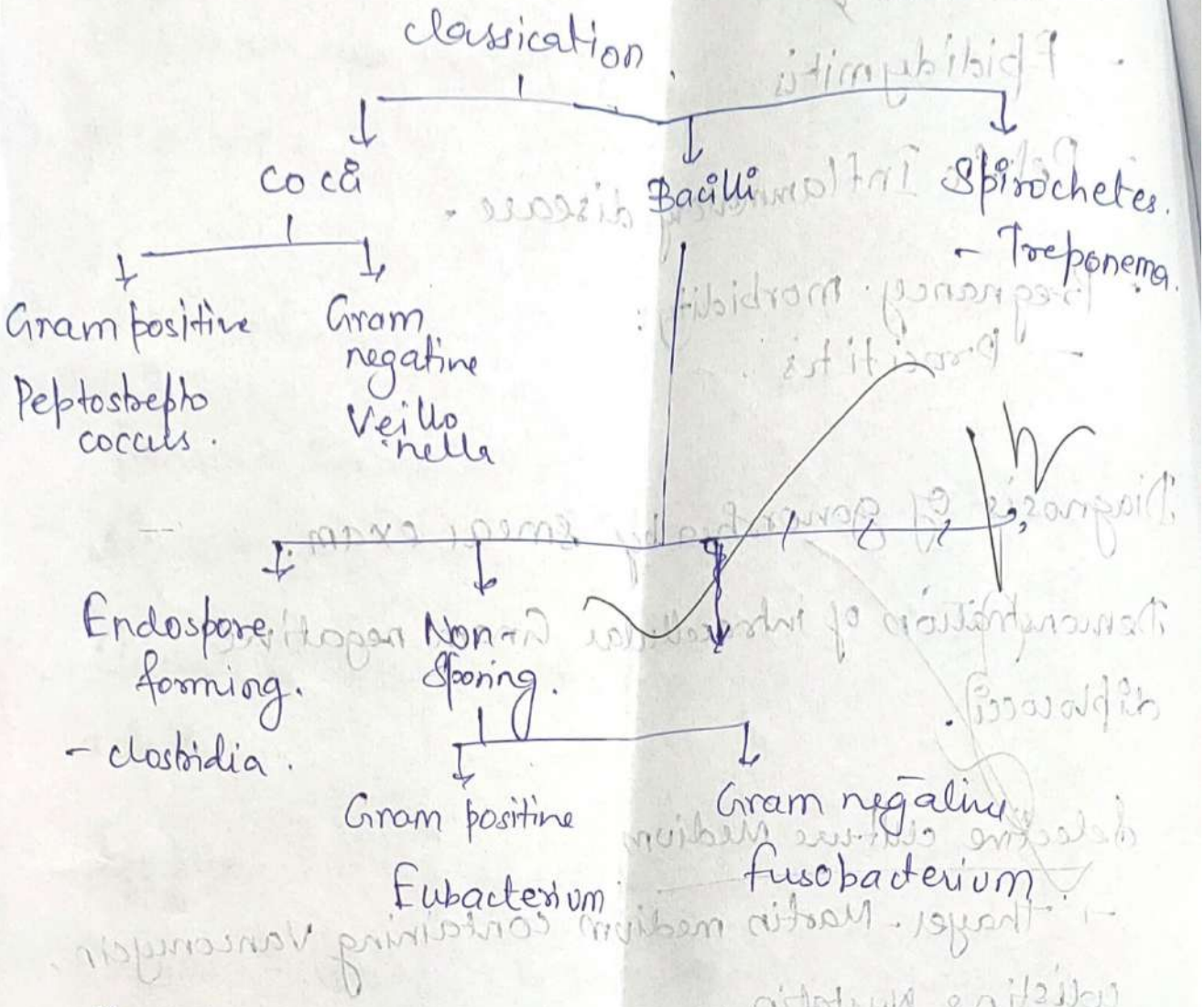

Short Answers

→ IgM : 1st Ig to be made by fetus and 1st Ig to be made by virgin B cells.

→ It has pentameric structure.

Half life is 5 days.

Plasmid : It is a DNA molecule that is separate from & can replicate independently of the chromosomal DNA.

1) Widal test.

Widal test is used for diagnosis of typhoid.

The tests measure agglutinating antibodies directed against salmonella O somatic surface antigen and/or an H flagella antigen of suspected organism.

4) Coagulase test

It is main lab test used to differentiate Staphylococcus aureus from other Staphylococcus.

clumping indicates positive reaction.

2) Psychrophilic bacteria: The microorganisms with optimal growth temperature of 15°C or lower, Maximum growth at 20°C & Minimum growth temperature of 0°C.

MICROBIOLOGY

PROFESSOR
G. ARTHITHEESWARAN

21/30

1. CLOSTRIDIUM TETANI:

Causative Organ for Tetani.

Morphology:

Gram +ve bacili

Slender bacilli. It has straight access, parallel sides and rounded ends.

Drumstick like appearance

Non capsulated ends & Motile.

PATHOGENESIS:

Mechanism of Action:



Tetanospasmin
(Tetanus toxin)

↓

Blocks synapse inhibition in spinal cord

↓

Toxin acts presynaptically

↓

Abolition of final inhibition

↓

Uncontrolled spread of impulses anywhere in CNS

↓

Muscle rigidity and spasms

↓

In absence of reciprocal inhibition

LABORATORY DIAGNOSIS:

Microscopically – Drumstick appearance

Culture - one half of Blood in agar plate

↓

Clostridium tetani produces swarming growth deducted in another 1-2 days.

Invivo - Toxigenicity testing - blood agar plates having tetanus antitoxin spread over one half of plate.

Invivo Toxigenicity:

It is test lested in guinea pig

animals a 2-4 day coccoon meat culture

innoculated

Prophylaxis:

It is a preventible disease

Surgically:

Removing foreign bodies, necrotic tissues, Blood clots to prevent anaerobic environment

Antibiotics:

Aim at destroying (or) inhibiting Tetanus bacilli and pyogenic bacilus

Immunization:

Passive Immunization:

Is by injection of tetanus antitoxin.

Antitetanus serum from hyperimmune horses was the preparation originally used

The dose employed was 1500 I.U given subcutaneously or intramuscularly in non-immune person soon after receiving any tetanus prone injury

ACTIVE IMMUNIZATION:

It is not only the most effective method of prophylaxis but also the means where by tetanus following unnoticed injuries can be prevented.

This is achieved by spaced injection of formed toxoid, which is available either as plain toxoid.

SHORT NOTES:

PROFESSOR & HOD
Department of Immunology & Biology
Venkateswara Dental College & Hospital
Chennai-603 102

4. ANAPHYLAXIS:

Anaphylaxis is acute, potentially fatal systemic type I hypersensitivity reaction (IgE dependant)

It is the classical immediate hypersensitivity reaction

FEATURES:

Antigens & haptens can induce anaphylaxis

PATHOPHYSIOLOGY:

First, the body is sensitized. When there is contacted with allugns) Antigens.

It does not cause any reaction

SENSITIZATION STAGE:

Antigen (allergens) invades body

↓

Plasma cell produce large amounts of class IgE antibodies (against allergens)

↓

IgE antibodies attach to Mast cells in body

↓

Mast cell degranulates releases

↓

Histamine
Leukotrienes
Eosinophil Chemotactic factor
Slow reacting substance of Anaphylaxis (SRS-A)

↓

Involvement of skin (rashes)
Bronchoconstriction

TREATMENT:

1. Antihistamines administration (25mg qid diphenhydramine

2. H_2 Blockers

3. Oxygen

4. Inhaled β-adrenic agents

1. VIRIDANS GROUP:

Also called Streptococci Viridans.

Seen in

(i) Upper respiratory tract

(ii) Mouth

(iii) Alpha lysis.

MORPHOLOGY:

* Non pathogenic

* In persons with pre cardiac lesion may cause endocarditis

* Tooth Extraction / other dental procedures can lead to bacteremia.

* Prophylactic antibiotic coverage is available

PROFESSOR & HOD
Department of [illegible]
[illegible]
Chennai - 603 102

STREPTOCOCCUS MUTANS: is an α- hemolytic strepto-cocci seen in mouth

Gram +ve.

The bacterium was polysaccharid coat that allows it to stick to tooth and also to the damaged heart valves which can lead to blood bloch

It produces acid from sugar and saliva

It is prevented by good oral hygiene and good prophylaxis.

2. GONORRHEA:

Bacterial infection caused by Neisseria gonorrhea causes urogenital Anorectal

Urogenital tract infection are most common

RISK FACTORS: Age younger than 25 years
Black race
History of gonococcal infection
Prostitution

CHILDREN:

Mothers with a history of sex (or) substance abuse.

LAB DIAGNOSIS:

Gram stain of a urethral smear (or) cervical swab showing gram -ve intracellular diplococci.

DRUG RESISTANCE:

PROFESSOR & HOD
Department of [illegible]
Chennai 600 102

Though occasional restraint strains had been identified in the laboratory, resistance to choloramphenicol did not pose any problems in typhoid fever, when resistant strain emerged in Mexico & Kerala.

In India, Chloro amphenicol resistant typhoid fever appeard in epidemic form. ~~fast~~ first in Calicut.

Typhoid Bacillus strain resistant to many (or) all of these drug began to spread to most part of India

The drug useful in the treatment of such multi resistant typhoid cases were the later fluoroquinolones and the 3rd generation cephalosporins.

Furazolidone is still active agent against most isolate

Now several isolate of typhoid bacilli are once again similar to chloramphenicol

SHORT ANSWERS:

1. **Ig M:**

Accounts for 5 - 10 % of serum proteins

Polymer of five monomeric units

5 - Days: Half life

FUNCTION:

Agglutination of bacteria

Cause aponization and minimum hemolysis

Furazolidone is still active agent most isolates

Now several isolates of typhoid bacilli are once again sensitive to Chloramphenicol,

2.

3. PLASMIDS:

They are circular DNA molecules present in cytoplasm of bacteria

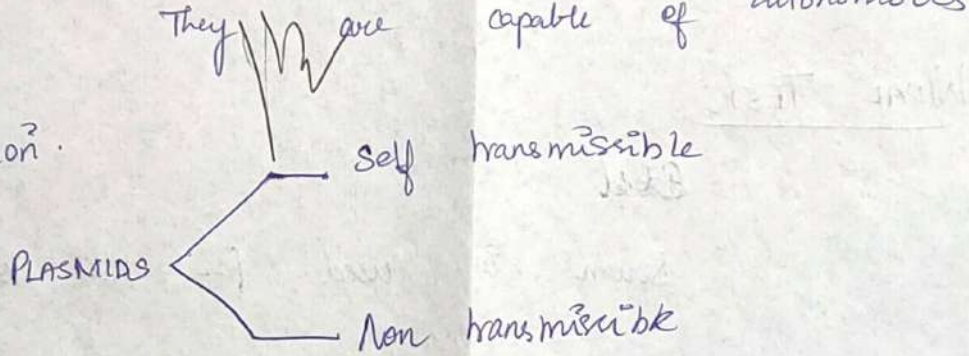

4. COAGULASE TEST:

(a) TUBE coagulase test

(b) SLIDE test

(a) TUBE COAGULASE:

About 0.1 ml of broth culture or agar culture suspension of Isolate is added to about 0.5ml of human or rabbit plasma in narrow test tube.

(b) SLIDE TEST:

Detecting bound coagulase is much simpler and usually gives results parallel with the tube test.

Prompt clumping indicates the test.

5. WIDAL TEST:

~~Blood~~

Serum is used for this test.

TYPE OF TECHNIQUE: Direct agglutination

ANTIBODIES DETECTED: Antibodies against O and H antigens are detected

Two serum samples are collected at an interval of 7-10 days are obtained

MICROBIOLOGY

PROFESSOR & HOD
Department of General Microbiology
Tamilnadu Govt. Dental College & Hospital
Chennai - 600 003

21/30

Devimeenakshi K
BDS II Year

ESSAY:

CLOSTRIDIUM TETANI

- Causes tetanus.
- Found in soil and intestine of man and animals.

Morphology

- Gram positive, slender bacillus with spherical, terminal spores (give characteristic drumstick appearance).
- Non-capsulated and motile.
- Have peritrichate flagella.

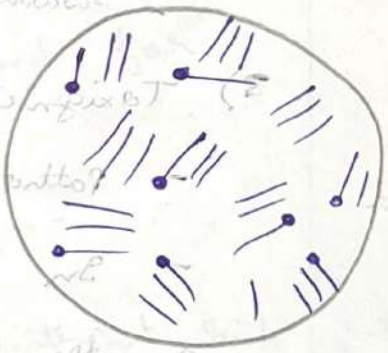

Pathogenesis

Contamination of wound with Cl. tetani spores.

↓

Localized in the wound.

↓

During favourable condition [Germination of spores and toxin production]

↓

Pathogenic effect due to tetanospasmin.

Laboratory Diagnosis

- Done by demonstration of bacilli by microscopy, culture or by animal inoculation
- Specimen collected from wound swab, exudate or tissue from the wound.

1) Microscopy
   - Gram positive bacilli with drumstick appearance.

2) Culture.
   - Specimen inoculated on freshly prepared blood agar
   - Incubated at 37°C for 24-48 hrs. under anaerobic conditions.
   - Swarming growth seen.

3) Toxigenicity Test
   - Pathogenicity established with toxin production.
   - In positive case, the test animal develops symptoms within 12-24 hrs. beginning with stiffness of tail of mouse.

Prophylaxis

1) Surgical [Removal of foreign body, blood clots, etc]

2) Antibiotics
   - Destroy or inhibit tetanus bacilli and other pyogenic bacteria in wounds and prevent

toxin production

- Long acting penicillin injection or erythromycin given.

3) Immunisation

- Tetanus is preventable disease.

a) Active immunisation.

* Tetanus toxoid available as 'plain toxoid' or adsorbed on aluminium hydroxide or phosphate (APT) is commonly used.
* Given IM with an interval of 4-6 weeks.
* Gap of 6-12 months between the second and third dose.

b) Passive immunisation

* Antitetanus serum has been used for preventing tetanus.
* Dose: 1500 IU by IM route.
* HTIG is being used now without risk of hypersensitivity.

c) Combined prophylaxis

* Used in non-immune person.
* First dose in one site along with ATS or HTIG in another arm.
* Second and third doses at monthly interval.

11 SHORT NOTES

1) VIRIDANS STREPTOCOCCI

- Produce alpha haemolysis on blood agar [greenish discoloyration On blood agar].
- Commensals of mouth and upper respiratory tract.
- This group includes Str. mitis group, Str. anginosus group and Str. bovis group.
- Non-pathogenic but occassionally cause disease.
- Associated with dental caries and subacute bacterial endocarditis.

* Dental caries is caused by Str. mutans as it breaks down dietary sucrose, producing acid and a tough adhesive dextran.

* The acid damages dentine while the dextran binds together, food debris, mucus, epithelial cells and bacteria to form dental plaques.

- Cause transient bacteraemia after some dental procedures such as tooth extraction.
- Prophylactic antibiotic should be given in such persons before tooth extraction or other procedures.
- Penicillin sensitive but some strains are resistant

GONORRHOEA

PROFESSOR & HOD
Department of ...
University ...

N. gonorrhoeae cause STD gonorrhoea.

- Gonorrhoea is a STD involving urethra in both sexes but in females, the endocervix is the primary site of infection.
- Incubation period 2-8 days.
- Acute urethritis characterized by purulent urethral discharge.
- In males, acute urethritis may extend to the prostate, testes, seminal vesicles and epididymis.
- In females primary infection may spread from urethra and cervix to Bartholin's glands, uterus, fallopian tube, ovaries.
- N gonorrhoeae.

* Gram negative oval cocci arranged in pairs with pear or bean shaped

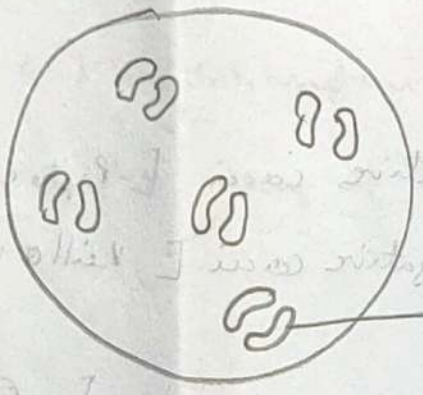

* Colonies are small round, grey, transl convex with finely granular surface.

Treatment

→ The organism ~~is~~ is sensitive to large doses of penicillin or doxycycline.

→ Two types of penicillin resistance observed:

1) Low Level Resistance
   - Sensitive to high conc. of penicillin and are not related to beta-lactamase production.

2) High Level Resistance
   - Due to production of enzyme beta-lactamase and is plasmid coded.

* In penicillin resistant gonorrhoea, cefotaxime, ceftriaxone, tetracycline or spectinomycin are used.

3) NON SPORING ANAEROBES

Cause human and animal infections.

Classification

A) Cocci
   1) Gram positive cocci [Peptococcus, Peptostreptococcus]
   2) Gram negative cocci [Veillonella].

B) Bacilli
   1) Gram positive bacilli [Eubacterium, Lactobacillus]
   2) Gram negative bacilli [Bacteroides, Prevotella]

(c) Spirochaetes [Treponema, Borrelia]

* These are usually endogenous and cause anaerobic infection
* They produce disease when the host's resistance is lowered.

Laboratory Diagnosis

A) Specimens: Eg aspiration ~~collected~~ in case of lung abscess is done to collect the material - but not ~~this~~ in the case of sputum.

B) Direct Microscopy: Examination of gram stained smear is useful. Examination of specimen under UV light may show the bright red fluorescence in cases of P. melaninogenica.

c) Culture: Freshly prepared blood agar is a suitable culture medium. Culture plates are incubated at 37°C in anaerobic jar with 10% CO_2.

Treatment

* Penicillin is effective against most anaerobes except B fragilis.
* Tetracycline and chloramphenicol are also used.
* Metronidazole is the drug of choice

III SHORT ANSWERS

1) IgM

- Chemical nature of antibodies is globulin and are named as immunoglobulins.
- Pentamer consisting of 5 immunoglobulin subunits and one molecule of J chain, which joins Fc region.
- Half life is five days.
- Heavy molecule with molecular weight of 900,000 to 1,000,000 [millionaire molecule]
- Constitutes 5-8% of total serum immunoglobulin.
- Normal level 0.5-2 mg/ml in serum and distributed intravascularly.
- Appears early in response to infection before Ig G.
- Provides protection against blood invasion by micro organisms.

IgM Molecule

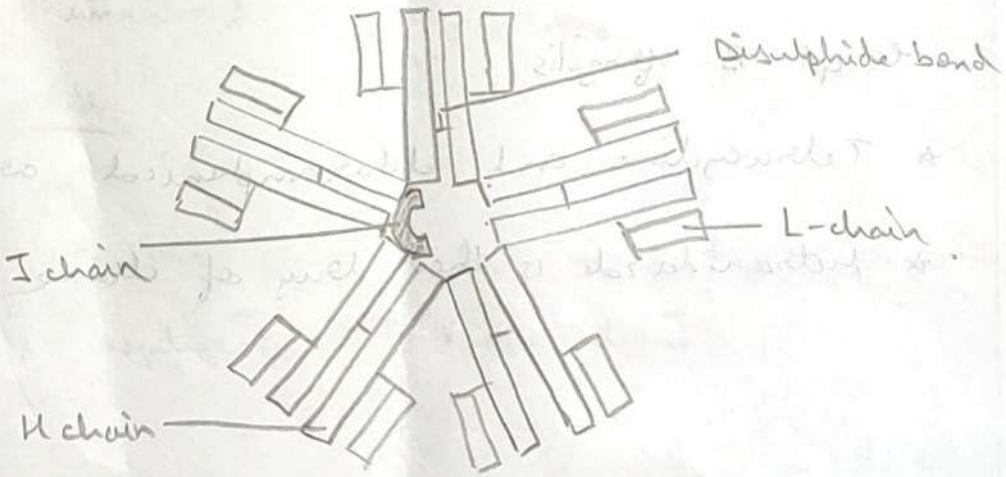

PSYCHROPHILIC BACTERIA

- These are bacteria that are capable of growth and reproduction in low temperatures ranging from -20°C to 20°C.
- Optimal growth temperature ~~of growth~~ is 15°C
- They are mainly found in polar regions and deep sea.
- Gram negative genera include Pseudoalteromonas, Psychrobacter, Flavobacterium, Moritella and Vibrio, etc.
- Gram positive genera includes, arthrobacter, bacillus, etc.

3) ## PLASMIDS

- It is a small, extrachromosomal DNA molecule within the bacterial cell which can replicate independently.
- Found as circular, double stranded DNA also present in eukaryotic organisms and archaea.
- Carry genes that benefit survival of organisms and offer antibiotic resistance.

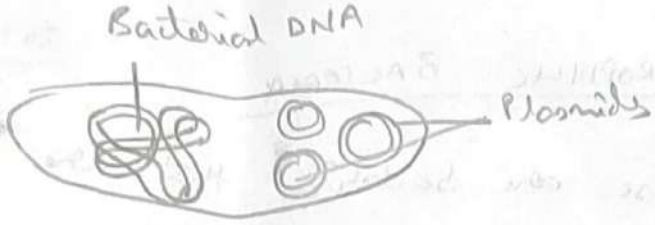

- Types of Plasmids
  - Fertility F- plasmids
  - Resistance (R) plasmids
  - Col plasmids
  - Degradative plasmids
  - Virulence plasmids

4) COAGULASE TEST

- Staph. aureus produces an enzyme coagulase. There are eight (A-H) antigenic types of coagulase.
- Most humans produce coagulase type A.
- Coagulase is heat labile and is secreted free into culture medium.
- Coagulase converts fibrinogen into fibrin.
- Test is done by slide and tube method.
- Slide test detects ~~cell~~ bound coagulase whereas tube test detects extracellular free coagulase.

* Citrated plasma should not be used because it gives false positive test.

5) WIDAL TEST

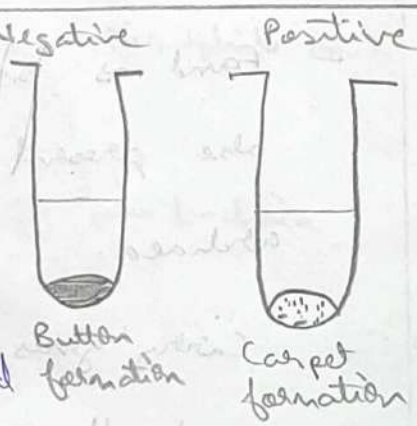

- Agglutination test for detection of agglutinins (H and O) in patients with enteric fever.
- Two specimens of sera at an interval of 7-10 days are preferred to demonstrate a rising antibody titre.



Monisha

1) Clostridium Tetani :-

Cl. Tetani is the causative agent of tetanus.
It is widely distributed in soil and intestine of man and animals.

Morphology

It is a gram positive, slender bacillus. (4-8 μm x 0.5 μm)
Spherical, terminal spores giving the bacillus characteristic drumstick appearance.
It is non-capsulated and motile.

Pathogenesis

→ It has little invasive power.
→ Tetanus develops following the contamination of wound with Cl. tetani spores.
→ The source of infection may be soil, dust, faeces etc.,
→ Infection strictly remains localized in the wound.
→ Pathogenic effects are mainly due to tetanospasmin (neurotoxin) of Cl. tetani.

Gonor...

Lab. diagnosis

The diagnosis of Tetanus should be made clinically and lab. test are done only to confirm it.

Lab. diagnosis may be made by demonstration of bacilli by microscopy, culture or by animal inoculation.

Specimens generally collected are,

Wound swab
exudate/tissue from wound

Prophylaxis

The available methods are,

Surgical
Antibiotics
Immunization.

(1) Active immunization.
(2) Passive immunization
(3) Combined prophylaxis.

Short notes

(1) Gonorrhoea

→ Niesseria gonorrhoea causes the sexually transmitted disease, gonorrhoea.

→ they are gram -ve oval cocci arranged in pairs with adjacent side concave..

→ In smear from purulent material, they are intracellular within polymorphs.

Gonorrhoea Pathogenesis -

It is a sexually transmitted disease involving urethra in both sexes but in females, the endocervix is the primary site of infection.

The disease is an acute urethritis characterised by purulent urethral discharge.

Asymptomatic infection is common in women.

In males, acute urethritis may extend to the prostate, testes, seminal vesicles.

The infection may spread to periurethral tissues, causing abscesses and multiple discharging sinuses. (Watercan perineum).

In females, the primary infection may spread from urethra and cervix to Bartholin's glands, uterus, fallopian tubes.

It may cause pelvic inflammatory disease resulting in sterility.

In some patients who develop pelvic inflammatory disease, is inflammation of liver capsule. (Fitz-Hugh-Curtis syndrome).

Short

2) Viridian streptococci:

This group of streptococci produce alpha haemolysis on blood agar. they are known as viridian streptococci. Streptococci due to greenish discolouration on blood agar.
They are commensals of mouth and upper respiratory tract.
Str. viridian include Str. mitis, St. bovis group.
each group contains many species.
This group can possess Lancefield group A, C, F, G or none at all.
They are ordinarily non-pathogenic but on occasion cause disease.
These are associated with dental caries and subacute endocarditis.
Dental caries is caused by Str. mutans.
It break down dietary sucrose, producing acid and a tough adhesive dextran.
About 40% of SABE is caused by viridians group of streptococci.
following some dental procedure such as tooth extraction.
Prophylactic antibiotics should be given in such persons.
Hence, antibiotic sensitivity of these bacteria must be determined for appropriate treatment of endocarditis

Short answers :-

① IgM :-

It is a pentamer consisting of Immunoglobulin subunits.
It provide protection against blood invasion by microorganisms.
Half life is about 5 days.
It is mainly distributed intravascularly.

② Psychrophilic bacteria :-

these are extremophilic organisms that are capable of growth and reproduction in low temperatures ranging between -30°C to 10°C
they are found in places that are permanently cold.

③ Plasmid :-

A plasmid is a DNA molecules that is seperate from and can replicate independently of the chromosomal DNA.
they are double stranded.
they occur naturally bacteria but are sometimes found in eukaryotic organism.

④ WIDAL TEST :-

Typically, patient serum is diluted into a series of tubes or wells on a slide.
the test measure agglutinating antibodies directed against Salmonella.

3) Anaphylaxis :-

It occurs when a sensitized individual comes in contact with a shocking dose of antigen.

Sensitization may occur by any route such as, parental, inhalation or ingestion but the most effective route is parental.

An interval of 2-3 weeks, is required between sensitising and shocking dose during while cytotrophic antibody IgE.

when a shocking dose of the same or immunologically related antigen is given,

the antigen combines with cell bound IgE antibody on mast cells rapidly.

Types

(1) Anaphylaxis in vitro
(Schultz-Dale phenomenon)

(2) Cutaneous anaphylaxis.

It is type type I hypersensitivity reaction

Micro biology



Vishnu priya. V

1 Essay:

1 Clostridium tetani

Clostridium tetani is the causative agent of tetanus. It is widely distributed in soil and intestine of man and animals

A. Morphology.

It is a Gram positive, slender bacillus with spherical, terminal spores giving the bacillus the characteristic drumstick appearance. It is non-capsulated and motile with peritrichate flagella.

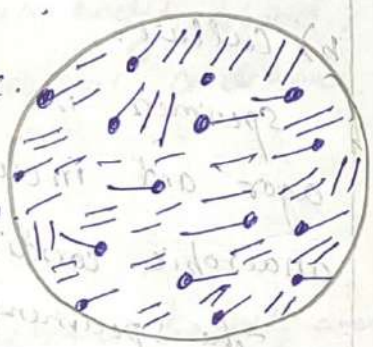

→ Pathogenesis.

Cl. tetani has little invasive power. Tetanus develops following the contamination of wound with cl. tetani spores. Infection strictly remains localized in the wound.

⇒ Laboratory Diagnosis:

The diagnosis of Tetanus should always be made clinically and laboratory tests are done only to confirm it.

→ It can made by demonstration of bacilli by microscopy, culture or by animal inoculation.

a) Microscopy:

Gram stains may show Gram positive bacilli with drumstick appearance.

b) Culture:

Specimen is inoculated on freshly prepared blood agar and incubated at 37°C for 24 -48 hours under anaerobic conditions.

→ The specimens is also inoculated in Three tubes of cooked meat broth (CMB).

→ Gram stained smear from culture shows typical gram positive bacilli with drumstick appearance.

c) Toxigenicity test:

Pathogenicity of the isolated organism is established with demonstration of toxin production.

In positive case, the test animal develops symptoms with in 12 - 24 hours, beginning with stiffness of the tail

Rigidity proceeds to the leg on the inoculated side, the another leg, trunk and forelimbs, [illegible] order. Death occurs within two days, but may be killed earlier as the ascending tetanus is very much diagnostic. The control animal does not show any changes due to neutralisation of toxin by antitoxin.

→ prophylaxis.

* The methods.

1) surgical
2) Antibiotics
3) Immunisation

1) surgical

→ It aims at removal of foreign body, blood clots etc. in order to prevent anaerobic conditions favourable for the bacillus.

2) Antibiotics.

Antibiotics destroy or inhibit tetanus bacilli and other pyogenic bacteria in wounds and thus the production of toxin is prevented.

3) Immunisation.

→ Tetatus is a preventable disease

(a) Active immunisation.

It is the most effective method of prophylaxis

APT is commonly used for active immunisation.

Tetanus toxoid is given along with diphtheria toxoid and pertusis vaccine in children.
Three doses are given intramuscularly at interval of 4-6 weeks staring at age as early.

(b) Passive immunisation.

ATS prepared by immunising horses with toxoid has been used for preventing tetanus.
Homologous serum prepared from humans, human antitetanus immunoglobulins is now being used without the risk of hypersensitivity dose of 250 units used in prophylaxis

c) Combined prophylaxis.

In non-immune person, it is ideal to immunise with first dose of tetanus toxoid in one site along with administration of ATS or HTIG in another arm, followed by the second and third doses of tetanus toxoid at monthly interval.

II Short note

1. Viridans streptococci

This group of streptococci produce alpha haemolysis on blood agar.
They are known as viridans streptococci due to greenish discolouration on blood agar.
- They are commensal of mouth and upper respiratory tract.

Each group contains many species. str. [redacted] and Group F streptococci are now [redacted]
str. anginosous group.

They are ordinarily non-pathogenic but on occasions cause disease.

→ Dental caries is caused by str. mutans.
The acid damages dentine while the dextran binds together food debris, mucus, epithelial cells and bacteria to form dental plaque.

The cause endocarditis in person with predisposing factors such as valvular disease of heart, Congenital heart disease and cardiac surgery.

Prophylactic antibiotic should be given in such persons before tooth extraction or other procedure.

Viridans streptococci are genially penicillin sensitive but some strains may be resistant, hence antibiotic sensitivity of these bacteria must be determined for appropriate treatment of endocarditis.

Some dental procedure such as tooth extraction, they may cause transient bacteraemia and get implanted on damaged or prosthetic valves or in a congenitally diseased heart

(ii) Gonorrhoea.

Gonorrhoea is a sexually transmitted disease caused by Neisseria Gonorrhoeae

They are gram negative oval cocci arranged in pairs with adjacent sides concave.

It is sexually transmitted disease involving urethra in both sexes but in females, the endocervix is the primary site of infection

→ The incubation period is 2-8 days. The disease is an acute urethritis characterised by purulent urethral discharge.

Asymptomatic infection is common in women.

In males the acute urethritis may extend to the prostate, testes, seminal vesicles and epididymis.

The infection may spread to the periurethral glands causing abscess and multiple discharging sinuses. In females, the primary infection may spread from urethra and cervix to Bartholin's glands, uterus, fallopian tubes, ovaries and may cause pelvic inflammatory disease resulting in sterility. In some patients who develop pelvic inflammatory disease, there is inflammation of liver capsules. (Fitz-Hugh-Curtis syndrome).

Short Answer:

IgM

The Role of IgM is to protects the blood stream.

IgM is a pentamer consisting of 5 immunoglobulin subunits and one molecules of J chain, which joins the basic subunits. It constitutes about 5-8 per cent of total serum immunoglobulins. It is heavy molecules with a molecular weight 900,000 to 1,000,000 hence also called the millionaire molecules.

IgM is mainly distributed intravascularly. It appears early in response to infection or infection before IgG. It can not cross the placenta, presence of IgM antibody in serum of newborn indicates congenital infection.



2 Psychrophillic bacteria.

Psychrophilic bacteria include Gram negative genera such as Pseudoalteromonas, Moraxella, Psychrobacter, Flavobacterium, vibrio and Pseudomonas.

Deversity of Psychrophilic Bacteria in sea and Glacier Terenvironments.

It is defined as cold loving bacteria. Their cardinal temperature are 20°C for maximal growth 15°C or lower. for optimal growth

3 plasmid

A plasmid is a small, circular, double-stranded DNA molecule that is distinct from a cell's chromosomal DNA.

Plasmids naturally exist in bacterial cells, and they also occur in some eukaryotes. often, the genes carried in plasmids provide bacteria with genetic advantages, such as antibiotic resistance.

5) widal test:

The widal test is an advanced way to check for antibodies that your body makes against the salmonella bacteria that causes typhoid fever. It looks for O and H antibodies in a patient's sample blood (serum) This test helps detect life threatening illnesses like typhoid fever.

MICROBIOLOGY

PROFESSOR & HOD
Department of General Microbiology
Dr. Venkateswara Dental College & Hospital
Chennai 600 103

19/30

ZENOBIA. H

I. 1. Clostridium tetani :-

Clostridium tetani is the causative agent of tetanus. It is widely distributed in soil & intestine of man & animals.

Morphology:-

- It is gram positive
- Slender bacillus with spherical
- terminal spores (drumstick appearance)
- non-capsulated and motile with pentachrote flagella.

Pathogenesis:-

- It has little invasive power.
- It develops following the contamination of wound with Cl. tetani spores.
- The sources of infection may be soil, dust, faeces etc.
- Infection strictly remains localized in the wound

Laboratory Diagnosis:-

The diagnosis is made clinically and laboratory tests only to confirm it.

Microscopy:-

Gram staining may show Gram positive bacilli with drumstick appearance.

(ii) culture:

Specimen is inoculated on freshly prepared blood, agar and incubated at 37°c for 24-48 hrs under anaerobic conditions.

Cl. tetani produces a swarming growth.

The specimen is also inoculated in three tubes of cooked meat broth (CMB)

1 tube is heated at 80°C for 15 minutes, the 2nd tube is heated at 80°c for 15 minutes and third kept unheated.

Heating for different periods is to kill vegetative bacteria, while leaving tetanus spores undamaged.

These cooked meat broths are incubated at 37°c. and subcultured on blood agar plates daily for upto 4 days.

(iii) toxigenicity test:-

It is best tested in animals. 0.5 ml of 2 to 4 days old cooked meat culture is injected into foot of tail of one mouse, same amount is injected into another animal (control) that has received tetanus antitoxin (1000 units) an hour earlier.

prophylaxis:-

The available methods are

(i) Surgical

(ii) Antibiotics

(iii) Immunisation.

(i) Surgical :-

It aims at removal of foreign body, blood clots etc. in order to prevent anaerobic conditions favourable for the bacillus.

Depending on the type of wound, surgical prophylaxis may vary from simple cleansing to radical excision.

(ii) Antibiotics :-

Antibiotics destroy or inhibit tetanus bacilli & other pyogenic bacteria in wounds and the production of toxin is prevented.

Long acting penicillin injection or erythromycin may given.

(iii) Immunisation :-

Tetanus is a prevental disease

a) Active immunisation

b) passive immunisation

c) combined prophylaxis

II.

1. Viridans Streptococci :-

This type of streptococci produce alpha haemolysis on blood agar, they are known as viridans streptococci due to greenish discoloration on blood agar.

They are commensals of mouth and upper respiratory tract.

This group can possess Lancefield group D, C, F, G (or) none at all.

They are ordinarily non-pathogenic but on occasion cause disease.

The viridans streptococci bacterial endocarditis and dental caries. Dental caries is caused by streptococci mutans. It breaks down dietary sucrose, producing acid and a tough adhesive dextran.

The acid damages dentine while the dextran binds together food debris, mucus, epithelial cells and bacteria to form dental plaques.

These plaques lead to dental caries.

About 40% of subacute bacterial endocarditis is caused by viridans group of streptococci. They cause endocarditis in persons with predisposing factor such as valvular disease of the heart, congenital heart disease and cardiac surgery.

Some dental procedures such as tooth extraction, they may cause transient bacteraemia and get implanted on damaged (or) prosthetic valves (or) in a congenitally diseased heart and grow to form vegetations.

Antibiotic sensitivity of these bacteria must be determined for appropriate treatment of endocarditis.

2. Gonorrhoea:-

It is sexually transmitted disease involving urethra in both sexes but in females, the endocervix is the primary site of infection.

The incubation period is 3-8 days. The disease is an acute urethritis characterized by purulent urethral discharge

Asymptomatic infection is common in women.

In males, the acute urethritis may extend to the prostate, testes, seminal vesicles and epididymis.

the infection may spread to the periurethral tissues, causing abscesses and multiple discharging sinuses (watercan perineum)

In females, the primary infection may spread from urethra and cervix to Bartholin's glands, uterus, fallopian tubes, ovaries and may cause pelvic inflammatory disease resulting in sterility.

In some patients, who develop pelvic inflammatory disease, there is inflammation of liver capsule.
(Fitz-Hugh-curtis syndrome)

III.

1. IgM:-

IgM is a pentamer consisting of 5 immunoglobulin subunits and one molecule of J chain, which joins the basic subunits

It constitutes about 5-8 percent of total serum immunoglobulins. It is heavy molecule with a molecular weight 900,000 to 1,000,000 hence also called millionaire molecule. IgM is mainly distributed intravascularly.

It appears early in response to infection before IgG.

2. plasmid:-

A plasmid is a small, circular, double stranded DNA molecule that is distinct from a cell's chromosomal DNA.

Plasmids naturally exist in bacterial cells and they also occur in some eukaryotes.

often the genes carried in plasmids provide bacteria with genetic advantages, such as antibiotic resistance.

3. WIDAL TEST:-

The widal test is an advanced way to check for antibodies that your body makes against the salmonella bacteria that causes typhoid fever.

It looks for O and H antibodies in a patient's sample blood (serum).

This test helps detect life-threatening illness like typhoid fever.

1

MICROBIOLOGY.

16

John Joshua.

10 Clostridium Tetani:

Cl. tetani is the causative agent of tetanus. It is widely distributed in soil and intestine of man and animals.

Morphology

It is a gram positive, slender bacillus with spherical, terminal spores giving the bacillus characteristic drumstic appearance.

Culture

It is an obligate anaerobe which grows on ordinary media. Growth is improved by the addition of blood or serum.

The optimum temp is 37 °C.

Biochemical Reactions

Cl. tetani has slight proteolytic, but no saccharolytic property.

Gelatin liquefaction occurs very slowly. It does not fermant any sugar.

Resistance

Most of the strains are killed by boiling for 10 - 15 mts but some resist boiling for 3 hrs.

Pathogenesis:

It has little invasive power.

It develops following the contamination of wound with cl. tetani spores.

The sources of infection may be soil, dust faeces etc.

Lab diagnosis:

The diagnosis is made clinically and lab tests only to confirm it.

Toxigenicity test:

It is best tested in animals 0.2 ml of 2 to 4 days old cooked meat culture is injected into root of tail of one mouse, same amount is injected into another animal.

~~Prophylaxis~~.

Culture:

Specimen is inoculated on freshly prepared blood, agar and incubated at 37°C for 24-48 hrs under anaerobic conditions.

cl. tetani produces a swarming growth.

The specimen is also inoculated in three tubes of cooked meat broth.

02. Viridans staepto cocci:

This group of streptococci alpha haemolysis on blood sugar. They are known as viridans staeptococci due to greenish discolouration on blood agar.

They are commensals of mouth and upper respiratory tract. str. viridans includes str. mitis group, str. anginosus group and str. bovis group.

They are ordinarily non-pathogenic but on occasions cause disease. The viridans streptococci are associated with dental caries and subacute bacterial endocarditis.

Dental caries is caused by str. mutans

It breaks down dietary sucrose, producing acid and a tough adhesive dextran.

The acid damages dentin while the dextran binds together food debris, mucus, epithelial cells and bacteria to form dental plaques.

Viridians streptococci are generally penicillin sensitive but some strains may be resistant.

Hence, antibiotic sensitivity of these bacteria must be determined for appropriate treatment of endocarditis.

Heating for different periods is to kill vegetative bacteria, while leaving tetanus spores damaged.

These cooked meat brothe are incubated at 37°C and subcultured on blood agar plates daily for upto 4 days.

Prophylaxis

The available methods are

1. surgical
2. Antibiotics
3. Immunisation.

Surgical:

It aims at removal of foreign body, blood clots etc; in order to prevent anaerobic conditions favourable for the bacillus.

Antibiotics:

Antibiotics destroy or inhibit tetanus bacilli and other pyogenic bacteria in wounds & thus the production of toxin is prevented.

Immunisation:

Tetanus is a preventable disease.

a) Active Immunisation
b) Passive Immunisation
c) Combined prophylaxis.

2. Neisseria Gonorrhoeae.

Morphology:

They are gram negative diplococci arranged in pairs with adjacent sides concave.

In smear from purulent material, they are intracellular within polymorphs, some cells containing as many as hundred cocci.

Culture:

This organism is more difficult to grow than N. meningitidis.

They are aerobic but may grow anaerobically as well.

C. Biochemical Reactions:

N. gonorrhoeae is oxidase positive. Gonococci ferment glucose and not maltose.

D. Antigenic structure:

The antigenic structure is complex. The surface structures of N. gonorrhoeae include the following.

- capsule
- Pili
- Lepopolysaccharide
- proteins
  - protein I
  - Protein II
  - Protein III.

Treatment.

Sensitive to large doses of penicillin or doxycyclin.

1. Ig M:

Ig M is a pentamer consisting of 5 immunoglobulin subunits and one molecule of J chain, which joins the basic subunits.

It constitutes about 5-8 percent of total serum immunoglobulins. It is heavy molecule with a molecular weight 900,000 to 1,000,000 hence also called millioniare molecule.

2. Plasmid:

A plasmid is a small, circular, double stranded DNA molecule that is distinct from a cell's chromosomal DNA.

Plasmids naturally exist in bacterial cells and they also occur in some eukaryotes.

often, the genes carried in plasmids provide bacteria with genetic advantages, such as antibiotic resistance.

3. Widal test:

The widal test is an advanced way to check for antibodies that your body makes against the salmonella bacteria that causes typhoid fever. It looks for O & H antibodies in a patient's sample blood. This test helps detect life threatening illness like typhoid fever.

General Pathology

Answer Papers

GENERAL PATHOLOGY

PROFESSOR & HEAD
Department of General Pathology
Sri Venkateswara Dental College
Chennai 603 103

22/35

AKSHAY PAKKI

① Inflammation :-

Inflammation is defined as the local response of living vascularized tissue to anyway from any agent.

It is a body defense reaction in order to eliminate (or) limit the spread of injury (or) agent.

→ Cellular Events :-

Cellular phase of inflammation consists of 2 processes.

1. Exudation of Leucocytes.
2. Phagocytosis.

① Exudation of Leucocytes :-

The escape of leucocytes from the lumen of microvasculature to the interstitial tissue is the most important feature of inflammation.

(i) Changes in the formed elements of Blood

In the early stage of inflammation the rate of flow of Blood is increased.

Certified
PRINCIPAL
SRI VENKATESWARA DENTAL COLLEGE & HOSPITAL
OFF: OMR NEAR - NAVALUR
THALAMBUR, CHENNAI-600 130

due to Vasodilation. But subsequently there is slowing (or) Stasis of Blood stream.

with Stasis changes in the normal axial flow of Blood in the micro circulation take place.

(12) Rolling and Adhesion:-

Peripherally marginated and pavemented neutrophils slowly roll over the endothelial cells lining the vessel wall.

(a) Selectins:-

These are group of CAM's expressed on the cells and are structurally composed of lectins (or) lectin like proteins molecules the most important of which is S-Lewis x molecule.

- P-selectin
- E-selectin
- L-Selectin

(b) Integins:-

These are a family of Endothelial cell surface proteins having alpha

Certified
PRINCIPAL
SRI SENKATESWARA DENTAL COLLEGE & HOSPITAL
OFF. OMR NEAR - NAVALUR
THALAMBUR, CHENNAI-600 130

Short notes

Department of General Pathology
Venkateswara Dental College & Hospital
Chennai 603 103

(1) Granuloma:

It has the following structural composition.

(i) Epithelial cells:

They are modified macrophages which are somewhat elongated cells having slipper shaped nucleus.

(ii) Multinucleated giant cells:

They are formed by fusion of adjacent epithelial cells & may have 20 (or) more nuclei. These nuclei maybe arranged at the periphery.

(iii) Lymphoid cells:

As a cell mediated immune reaction to antigen, the host response by lymphocytes is integral to composition of a granuloma.

(iv) Necrosis

(v) Fibrosis

and bet a sub units, which are active during the process of loose and transient adhesions b/w endothelial cells and leucoytes.

(c) Immunoglobulins gene superfamily adhesion molecules:

* Intercellular adhesion molecule - I also called CD54 and vascular cell adhesion molecules called: CD106.

* Platelet endothelial cell adhesion molecule I (or) CD31 is involved in leucoyte migration from endothelial surface.

Phagocytosis:

It is defined as the process of engulfment of solid particulate material by the cells. these cells performing this function are called phagocytosis..

Example of Granuloma:

Bacterial

1. Tuberculosis
2. Syphilis
3. Granuloma Inguinale
4. Brucellosis

Fungal:

1. Actinomycosis
2. Blastomycosis

Parasite:

- Schistosomiosis

---

(2) Apoptosis:

Is a form of co-ordinated and intrinsically programmed cell death having significance in a variety of physiologic and pathologic condition.

Pathologic changes:

1. Cell death in tumours exposed to chemotherapeutic agent.
2. Cell death by cytotoxic T cells in.

in immune mechanism such as in graft versus host disease and rejection reaction.

3. Progressive depletion of CD_4^+ cells in the pathogenesis of AIDS

4. Cell death in viral infection

5. Heart disease:
   Eg: In acute myocardial infection

6. In degenerative disease of CNS

---

(3) Pathologic Calcification:

Defi:- Abnormal deposits of calcium salts occur in any tissues except bones and teeth

Dystrophic calcification:

Characterised by deposition of calcium salts in dead (or) degenerated tissues with normal calcium metabolism.

Morphological feature:

Etiology & pathogenesis of two are different.

Short Answers

1. Vascular changes in Acute inflammation:

Alteration in the microvasculature is the earliest response to tissue injury.

Haemodynamic changes:-

* Transient vasoconstriction -
* Persistent progressive vasodilation
* Hydrostatic pressure
* Slowing
* Leucocyte margination.

Triple Response:-

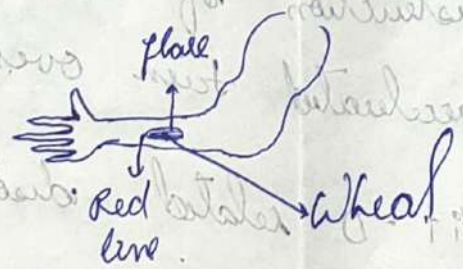

(2) Two causes for fatty change:- like:-

- Drinking too much Alcohol
- Obesity.

H and E stained sections:

- Calcium salts appear as deeply Basophilic irregular.
- Calcium deposits can be confirmed by specific stains.
  - Silver impregnation
  - Alizarin Reds

Metastatic Calcification:

- Can occur in normal tissue whenever there is hypercalcemia
  - → Main cause of hypercalemia.
    - (i) Increase secretion of parathyroid hormone.
    - (ii) Destruction of Bone due to the effect of accelerated turn over
    - (iii) Vit-D related disorder
    - (iv) Renal failure.

PROFESSOR & HEAD
Department of General Medicine
Sri Venkateswara Dental College & Hospital
Chennai - 603 103

→ Type 1 diabetes
- Metabolic syndrome
- Insulin resistance

(3) Diff b/w Transudate / Exudate:

Transudate:	Exudate
- Usually seen in congestive states.	- Seen in Inflammatory states
- Increased H P	- Increased vascular permeability.
- Sp Gr: <1.020	- S P G : >1.020
- Protein: <2 gm/dl	- > 2 gm/dl

(5) Two oxygen free radical:
- Superoxide Anion radical.
- Singlet oxygen

- Two Anti oxidants:
  - Selenium
  - Carotenoids

PROFESSOR & HOD
Department of General Pathology,
Sri Venkateswara Dental College & Hospital
Chennai- 603 103

22/35

S. Prakash raj

Inflammation is defined as the local response of living mammalian tissues to injury due to any agent.

→ The agents are.

1) Infective agents
2) Immunological agents
3) physical agents
4) chemical agents
5) Inert Materials.

Cellular events:-

Cellular phase of inflammation

1) Exudation of Leucocytes
2) phagocytosis

Exudation of Leucocyte:-

1) Changes in the formed elements of Blood.

The rate of flow of Blood is increased due to varodilatation.

→ But sequently there is slowing or stasis of Bloodstream with stasis, changes in Normal axil flow of Blood in Microcirculation takes place.

Rolling and Adhesion:-

- peripherally Margination and pavementing
Neutrophils slowly roll over the endothelial cells
lining the vessel wall.

i) selectins
ii) Integrins
iii) Immunoglobin gene superfamily adhesion Molecule.

3) Emigration

After sticking of Neutrophils to endothelium the former move along the endothelial surface till a suitable site between the endothelial cells is found where the Neutrophils throw out cytoplasmic pseudopods.

→ Simultaneous to emigration of leucocytes, escape of red cells through gaps b/w the endothelial cells diapedesis takes place.

→ It's a passive phenomenon - RBC being forced out either by raised hydrostatic pressure or may escape through the endothelial defects left after emigration of leucocytes.

→ Diapedesis gives haemorrhagic appearance to the inflammatory exudate.

PROFESSOR & HOD
Department of General Pathology
Sri Venkateswara Dental College & Hospital
Chennai - 603 103

4) Chemotaxis:-

The chemotactic factor mediated transmigration of leucocytes after crossing several barriers to reach the interstitial tissues is called chemotaxis.

i) Leukotrieve B4.

ii) complement system

iii) cytokines.

iv) soluble bacterial products

Phagocytosis:-

is defined as the process of engulfment of solid particulate material by the cells. The cells performing this function is called phagocytosis.

1) Recognition and attachment

2) Engulfment

3) Killing and degradation.

2) phagocytosis:-

Is defined as the process of engulfment of solid particulate material by the cells. The cells performing this function are called phagocytes.

There are two types of phagocytic cells

1) polymorphonuclear Neutrophils.

2) circulating Monocytes.

1) Recognition and attachment

2) Engulfment

3) Killing and degradation.

1) Recognition and attachment:-

Is initiated by the expression of surface receptors on Macrophages which recognise Micro-organisms; Mannose receptor and Scavenger receptor.

→ The process of phagocytosis is further enhanced when the Microorganisms are coated with specific proteins, opsonins from the serum or by self opsonised.

i) IgG opsonin.

ii) C3b opsonin.

PROFESSOR & HOD
Department of General Pathology,
Sri Venkateswara Dental College & Hospital,
Chennai- 603 102

2) Engulfment:-

The opsonized particle bound to the surface of phagocyte is ready to engulfed.

→ This is accomplished by formation of cytoplasmic pseudopods around the particle due to activation of actin filaments beneath cell wall.

Killing and degradation:-

Disposal of microorganisms can proceed by following mechanisms

Intracellular Mechanisms:-

i) oxidative bactericidal mechanism by oxygen free radicals.

a) MPO-dependent

b) MPO-independent

ii) Oxidative bactericidal mechanism

iii) Non-oxidative bactericidal mechanism.

b/A) · Intracellular Mechanisms.

B) Extracellular Mechanisms.

i) Granules.

ii) Immune Mechanisms.

II

1) Granuloma:

is defined as a circumscribed, tiny lesion, about 1mm in diameter.

→ Composed predominantly of collection of Modified Macrophages called ep: Reloid cells and rimmed at the periphery by Lymphoid cells.

Pathogenesis of Granuloma:

Formation of granuloma is a type IV granulomatous hypersensitivity reaction.

1) Ensultment of Macrophages:-

Macrophages and monocytes engulf the antigen and try to destroy it.

→ But since the antigen is poorly degradable, then cells fail to digest and degrade the antigen.

2) · CD4+T cells.

cytokines:-

activated by CD4 T cells also by Macropha

i) IL-1 and IC-2.

ii) Interferon γ activate macrophage.

iii) TNF-α.

iv) Growth factor.

comparison

1) - Epithelioid cells

2) Multinucleate giant cells.

3) Lymphoid cells

4) Necrosis.

5) Fibrosis.

2) Atrophy:-

Reduction in the number and size of parenchymal cells of an organ or its parts which was once normal is called atrophy.

→ Atrophy may occurs from physiologic or pathologic causes.

A) physiologic atrophy.

i) Atrophy of lymphoid tissue in lymph Nodes - appendix and thymus.

ii) Atrophy of gonads after Menopause

iii) Atrophy of brain - with ageing.

b) pathologic atrophy:-

1) Starvation atrophy

2) Ischaemic atrophy
   i) small atrophic kidney.
   ii) Atrophy of brain.

3) Disuse atrophy.
   i) wasting of Muscle of limb immobilized in cast
   ii) Atrophy of the pancreas in obstruction of pancreatic duct.

4) Neuropathic atrophy.

5) Endocrine atrophy.

6) pressure atrophy.
   i) erosion of spine.
   ii) erosion of skull
   iii) erosion of sternum.

7) Idiopathic atrophy.
   i) Myopathies.
   ii) Testicular atrophy.

3) Pathologic calcification:

Deposition of calcium salts in tissues other than osteoid or enamel is called pathologic or heterotopic calcification.

1) Dystrophic calcification:-

Occurs in 2 types,

1) Calcification in dead tissue.

2) Calcification of degenerated tissue.

Feature.	Dystrophic calcification	Metastatic calcification.
Calcium Metabolism	Normal	Deranged
Serum calcium level.	Normal	Hypercalcemia
Reversibility	Generally irreversible	Hypercalcemia
Causes.	Necrosis	Hyperparathyroidism
Pathogenesis-	Increased binding of phosphate.	Increased precipitation of calcium phosphate.

Vascular event.

Alteration in the microvasculature is the earliest response to tissue injury.

→ These alterations include hemodynamic changes of vascular permeability -

Imp

2). Cause of Fatty liver.

Two types of cause

1) conditions with excess fat, exceeding the capacity of the liver to metabolize it

2) - Liver cell damage, when fat cannot be Metabolized in it.

3) 1).

Difference b/w Transudate & exudate

Transudate	Exudate
Filtration of blood plasma without changes in endothelial permeability.	Oedema or inflammed tissue associated with increased vascular permeability.
Non inflammatory oedema.	Inflammatory oedema.
Gluco. content is same as plasma.	Low (less than 3gm/dl)

Department of General Pathology
Sri Venkateswara Dental College & Hospital

22/35.

General Pathology

Shruthi. T

Inflammation:

Inflammation is defined as the local response of living mammalian tissue to anyway from any agent.

It is a body defense reaction in order to eliminate (or) limit the spread of injury (or) agent.

Cellular events:

Cellular phase of inflammation consists of 2 processes.

- Exudation of leucocytes
- Phagocytosis
- Immunoglobulins gene superfamily
- Adhesion molecule.

Exudation of Leucocytes:

The escape of leucocytes from the lumen of microvasculature to the interstitial tissue is the most important feature of inflammation

(i) Changes in the formed elements of Blood
(ii) Rolling and adhesion

Selections:

These are group of CAM's expressed on the cells and all structurally composed of lectins like protein molecules the most important of which is S-lewis x molecules.

- P- selection
- E- selection
- L- selection

Integrins:

These are a family of Endothelial Cell surface proteins having alpha and beta sub units, which are activated during the process of loose and transient adhesions b/w endothelial cells & Leucocytes.

Phagocytosis:

It is defined as the engulfment of solid particulate material by the cells these cells performing this function are called Phagocytosis.

2. Short notes:

1) Granuloma:

It has the following structural composition:

(i) Epithelial cells:

They are modified macrophages which are somewhat elongated cells having slipper shaped nucleus.

(ii) Multinucleated Giant Cells:

They are formed by fusion of adjacent epithelial cells & may have 20 or more nuclei. These nuclei maybe arranged at the periphery.

(iii) Lymphoid cells:

As a cell mediated immune reaction antigens, the host response by

Lymphocyte & integrated to composition of granuloma

(iv) Necrosis

(v) Fibrosis

2) Apoptosis:

It is a form of coordinated and internally programmed cell death having significance in a variety of Physiologic and Pathologic condition

Pathologic changes:

1. Cell Death in Tumours exposed to chemotherapeutic agents.
2. Cell Death by Cytotoxic T cells in Immune mechanism such as in graft versus host disease & rejection reaction.
3. Progressive depletion of CD4+ cells in the pathogenesis of HIS.

A. Cell Death in viral infection

5. Heart Disease. eg: In Acute myocardial infection.

5. Pathological calcification

It is defined as abnormal deposits of Calcium salts occur in any tissue except bones and teeth.

- Dystrophic calcification:

Characterized by deposition of calcium salts in death (or) degenerated tissue with normal Calcium metabolism

Morphological feature:

Etiology & Pathogenesis of Tuo are different

Haud E stained sections:

- Calcium salts appear as deeply Basophilic irregular
- Calcium deposits can be confirmed by specific stains

- Silver impregnation
- Alizarin Reds

Metastic Calcification:

- Can occur in normal tissue whenever there is hypercalcemia
- Main cause of hypercalcemia
  (i) Increase secretion of parathyroid hormone
  (ii) Destruction of bone due to the effect of accelerated turnover.
  (iii) Vit-D related disorder.
  (iv) Renal failure.

iv. Short answer:

i) Vascular changes in Acute Inflammation:

Dilation in the microvasculature is the earliest response to tissue injury

Haemodynamic changes:

- Transient vasoconstriction
- Persistent progressive vasodilation
- Hydrostatic pressure.
- Slowing.
- Leucocyte margination

2) Two causes for fatty change:

- Drinking too much alcohol.
- Obesity

Department of General Pathology, Sri Venkateswara Dental College, Tirupati

3) Different b/w Transudate & Exudate.

Transudate	Exudate
- Usually seen in congestive state	- Seen in inflammatory states.
- Increased HP	- Increased vascular permeability
- Sp Gr: < 1.020	- SPG: > 1.020
- Proteins: < 2gm/dl	- > 2gm/dl

(4). Two oxygen free Radical.

Radical

- Superoxide Anion
- Singlet oxygen.

Two anti-oxidants:

- Selenium
- Carotenoids

GENERAL PATHOLOGY

Name: Vedhakarthigh. N
Year: II nd year.

20/35

ESSAY:

1. INFLAMMATION:

- Inflammation is defined as the local response of living being tissue to anyway from any agent.

- It is the reaction of the body in order to eliminate (or) limit the spread of an injury (or) an agent.

i) Cellular Events:

Cellular phase of inflammation consists of 2 processes:

- Exudation of leucocytes
- Phagocytosis
- Immunoglobulins gene superfamily adhesion molecule.

⇒ Exudation of Leucocytes.

The escape of leucocytes from the lumen of microvasculature to the interstitial tissue is the most important feature of inflammation:

I. Changes in the formed elements of blood:

In the early stage of inflammation, the rate of flow of blood is increased due to vasodilation, but subsequently there is slowing or stasis of blood stream.

II. Rolling & Adhesion

Peripherally marginated and pavemented neutrophils slowly roll over the endothelial cells lining the vessel wall.

i) Selectins:

These are a group of CAMS expressed on the cells and are structurally composed of lectins or lectin like protein molecules, the most important of which is sialyl Lewis x molecules.

- P selectin
- E selectin
- L selectin

ii) Integrins:

They are a family of endothelial cell surface proteins having alpha and beta subunits, which are activated during the process of loose and transient adhesions b/w endothelial

cells and leucocytes.

iii) Immunoglobulin gene superfamily adhesion molecules

- Intercellular adhesion molecules-I also called CD-54 and vascular cell adhesion molecules called CD106.

- Platelet endothelial cell adhesion molecule I or CD31 is involved in leucocyte migration from endothelial suface.

II. Phagocytosis:

It is defined as the process of engulfment of solid particulate material by the cells.

These cells performing this function are called phagocytes.

Department of General Pathology.
Sri Venkateswara Dental College & Hospital
Chennai - 600 078

1. SHORT NOTES

1. GRANULOMA

Granuloma has the following structural composition.

i) Epithelial cells.

They are modified macrophages which are somewhat elongated cells having slipper shaped nucleus.

ii) Multinucleated Giant cells

They are formed by fusion of adjacent epitheloid cells. and may have 20 or more nuclei. These nuclei maybe arranged at the periphery.

iii) Lymphoid cells

As a cell mediated immune reaction to antigen, the host response by lymphocytes is integral to composition of a granuloma.

iv) Necrosis

v) Fibrosis.

Example for Granuloma

Bacterial

- Tuberculosis
- Syphilis
- Granuloma inguinale
- Brucellosis.

Fungal

- Actinomycosis
- Blastomycosis

Parasite

- Schistosomiasis

2. APOPTOSIS:

It is a form of coordinated and internally programmed cell death having significance in a variety of physiologic and pathologic condition.

PROFESSOR & HOD
Department of General Pathology,
Sri Venkateswara Dental College & Hospital

i) Pathologic Changes

- Cell death in tumors exposed to chemo-therapeutic agents.

- Cell death by cytotoxic cells in immune mechanisms, such as in graft versus host disease and rejection reaction.

- Progressive depletion of CD4 cells in the pathogenesis of AIDS.

- Cell death in viral infection.

- Heart disease
  Eg: Acute myocardial infarction.

- In degenerative disease of CNS.

3. PATHOLOGIC CALCIFICATION

Abnormal deposits of calcium salts occur in any tissues except bones and teeth.

Dystrophic Calcification

Characterised by deposition of calcium salts in dead or degenerated tissues within normal

Calcium metabolism.

Morphological Feature

- Calcium salts are deeply staind basophilic irregular.
- Calcium deposits can be confirmed by special stains.
  - ⇒ Silver impregnation
  - ⇒ Alizarin Red S.

Metastatic Calcification

- Can occur in normal tissues whenever there is hypercalcemia.
- Causes of hypercalcemia:
  - increased secretion of parathyroid hormone.
  - destruction of bone due to the effect of accelerated turnover.
  - Vit D related disorder
  - Renal Failure

SHORT ANSWERS

Department of General Pathology
Sri Venkateswara Dental College

1. Vascular Changes in Acute Inflammation:

Alteration in the microvasculature in the earliest response to tissue injury.

Hemodynamic changes:

- transient vasoconstriction
- Persistent progressive vasodilatation
- hydrostatic pressure.
- slowing
- leucocytic margination.

2. TWO CAUSES FOR FATTY CHANGE LIVER

- Drinking too much alcohol.
- Obesity.

3. DIFFERENTIATE B/W

TRANSUDATE	EXUDATE
- Usually seen in congestive states	- Seen in inflammatory states.
- increased ~~HP~~	- increase vascular permeability
- Sp Gr : <1.020	- Sp Gr : ≥1.020
- Proteins : < 20gm/dl	- Proteins : >2gm/dl.

5. TWO OXYGEN FREE RADICAL

- Superoxide anion ~~radical~~.
- Singlet oxygen.

GENERAL PATHOLOGY

Dr. [illegible]
Department of [illegible]
Sri Venkateswara Dental College & [illegible]
Chennai - 600 130

ABIRAMI

22/35

1) INFLAMMATION:

Inflammation is defined as local response of living mammalian tissue to anyway from any agent. It is a body defense reaction in order to eliminate or limit the spread of injury to or agent

CELLULAR AGENTS:

Cellular phase of inflammation consists of 2 phases

1 → Exudation of leucocytes

2 → Phagocytosis

EXUDATION OF LEUCOCYTES:

The escape of leucocytes from the lumen of the micro vasculature to the interstitial tissue, It is the most important feature of inflammation

⇒ CHANGE IN FORMED ELEMENTS OF BLOOD:

In the early stage of Inflammation the rate of flow of blood is increased due to vasodilatation, but subsequently there is slowing of or Stasis of blood stream

With Stasis, changes in the normal axial flow of blood in the micro circulation takes place.

⇒ ROLLING AND ADHESION:

Peripherally marginated and pavemented neutrophils slowly roll over the endothelial cells lining the vessel wall.

⇒(a) SELECTINS:

They are group of CAM's expressed on the cells and are structurally composed of lectins (or) lectin like protein molecules the most important of which is S-Lewis x molecules

P - selectin

E - selectin

L - selectin

PROFESSOR & HOD
Department of General Pathology
Sri Venkateswara Dental College & Hospital
Chennai - 600 103

(B) INTEGRINS:

These are a family of endothelial cell surface proteins having alpha and beta subunits, which are activated during the process of loose and transient adhesions b/w endothelial cells and leucocytes

(C) IMMUNOGLOBULINS GENE SUPRAFAMILY ADHESION MOLECULES:

Intercellular adhesion molecules. I also called CD54 and vascular cell adhesion molecules called CD, 06.

Platelet endothelial cell adhesion molecule I (or) CO_3 is involved in leucocyte migration from endothelial surface

PHAGOCYTOSIS:

It is defined as the process of engulfment of solid particulate material by the cells these cells performing this function are called phagocytes.

SHORT NOTES

1. GRANULOMA:

It has the following structural composition.

(i) EPITHELIAL CELLS:

They are modified macrophages which are somewhat elongated cells having sliper shaped nucleus

(ii) MULTI NUCLEATED GIANT CELLS:

They are formed by fusion of adjacent epithelial cells and may have 20 (or) more nuclei.

maybe arranged at the periphery

(iii) LYMPHOID CELLS:

As a cell mediated immune reaction to antigen, the host response by lymphocytes is integrated to composition of a granuloma

(iv) Necrosis

(v) Fibrosis

EXAMPLE OF GRANULOMA:

BACTERIAL:

1. Tuberculosis
2. Syphylis
3. Granuloma ingunale
4. Brucellosis

FUNGAL:

1. Actinomycosis
2. Blastomycosis

PARASITE:

Chistosomiasis

(2) APOPTOSIS:

It is a form of co-ordinated programmed cell death having significance in a variety of physiologic and pathologic condition

PATHOLOGIC CHANGES:

1. Cell death in tumorous, exposed to chemotherapeutic agents
2. Cell death by cytotoxic + cells in immune mechanism such as in graft versus host disease and rejection reaction
3. Progressive depletion of $CD4^+$ cells in the pathogenesis of AIDS
4. Cell death in viral infection
5. Heart disease:

   Eg: In acute myocardial infection
6. In degenerative disease of CNS

Dr. [illegible]
Department of General Pathology
Sri Venkateswara Dental College & Hospital
Chennai - 603 103

(3) PATHOLOGIC CALCIFICATION:

Abnormal deposition of calcium salt occurs in any tissue except bones & teeth

DYSTROPHIC CALCIFICATION:

Characterised by deposition of calcium salts in dead (or) degenerated tissues with normal calcium metabolism

MORPHOLOGICAL FEATURE:

Etiology and pathogenesis of two are different

IN H AND E STAINED SECTIONS:

Calcium salts appear as deeply basophilic irregular.

Calcium deposits can be confirmed by specific stains.

Silver impregnation

Alizarin Red S.

METASTATIC CALCIFICATION:

- Can occur in normal tissue whenever there is hypercalcemia

→ Main cause of hypercalcemia

(a) Increased secretion of parathyroid hormone

(b) Destruction of bone due to the effect of accelerated turn over

(c) Vit - D related disorder

(d) Renal failure.

III SHORT ANSWERS:

2. VASCULAR CHANGES IN ACUTE INFLAMMATION:

Acceleration in the microvasculature is the earliest response to tissue injury

HAEMODYNAMIC CHANGES:

1. Transient vasoconstriction
2. Persistent progressive vasodilation
3. Hydrostatic pressure
4. Slowing

TRIPLE RESPONSE:

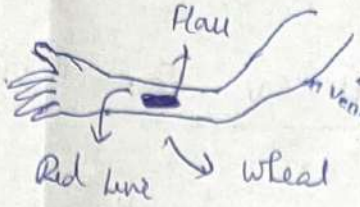

TWO CAUSES FOR FATTY CHANGE:

1) Drinking too much Alcohol
2) Obesity
3) Type 1 Diabetis
4) Metabolic syndome
5) Insulin resistance.

3. DIFFERENCE BETWEEN TRANSUDATE / EXUDATE

TRANSUDATE	EXUDATE
Usually seen in congestive states	Seen in inflammatory state
Increased Hp	Increased vascular permeability
SPGr : < 1.020	SPG : > 1.020
Proteins : < 2gm/dl	Proteins > 2gm/ml

5. Two Oxygen Free Radicals:

Superoxide anion radical

singlet oxygen

Two Antioxidants:

Selenium

PROFESSOR & HOD
Department of General Pathology
Sri Venkateswara Dental College
Chennai - 603 103

20/35

Aravind Kumar

I

Inflammation :-

Inflammation is defined as the local response of living mammalian tissues to any agent. It is a body defense reaction in order to eliminate or limit the spread of injurious agent.

Cellular events

Cellular phase of inflammation consists of 2 processes.

1. Exudation of leucocytes
2. phagocytosis

Exudation of leucocytes

The escape of leucocytes from the lumen of microvasculature to the interstitial tissue is the most important feature of inflammation.

1. changes in the formed elements of Blood

In the early stage of inflammation ii)
the rate of flow of Blood is increased
due to Vasodilatation, But subsequently
there is slowing or stasis of Blood stream

with stasis, changes in the normal
axial flow of Blood in the micro-
circulation take place.

2. Rolling and Adhesion

Peripherally marginated and
Pavemented Neutrophils slowly
roll over the endothelial cells lining
the Vessel wall.

i) Selectins

These are a group of CAMs
expressed on the cell and are
structurally composed of lectins or
lectin like protein Molecules the
most important of which is 8-lewis
x molecules:-

* P Selectin
* E Selectin
* L Selectin

ii) Integrins

These are family of endothelial cell surface proteins having alpha and beta sub units. which are activated during the process of loose and transient adhesions b/w endothelial cells and leucocytes.

iii) Immunoglobulin gene superfamily Adhesion Molecules.

*) Intercellular Adhesion Molecules-I also called CD54 and Vascular cell Adhesion molecules I called CD106.

*) platelet endothelial cell Adhesion molecule I or CD31 is involved in leucocyte migration from endothelial surface.

phagocytosis

is defined as the process of engulfment of solid particulate material by the cells. these cells performing this function are called phagocytes.

II. S'N

1. Granuloma

Granuloma has the following structural composition.

1) Epithelial cells

they are modified macrophages which are somewhat elongated cells having slipper shaped nucleus.

2) Multinucleate giant cells

they are formed by fusion of adjacent epithelioid cells and may have 20 or more nuclei these nuclei may be arranged at the periphery.

3) Lymphocytes

As a cell mediated immune reaction to antigen, the host response by lymphocytes is essential to composition of a granuloma.

4) Necrosis

5) fibrosis.

Example for Granuloma

Bacterial

1. Tuberculosis
2. Syphilis
3. Granuloma inguinale
4. Brucellosis.

fungal

1. Actinomycosis
2. Blastomycosis

parasite

Schistosomiasis

2. Apoptosis:

is a form of coordinated and intrinsically programmed cell death having significance in a variety of physiologic and pathologic condition.

pathologic changes.

1. cell death in tumour exposed to chemotherapeutic Agents.
2. cell death by cytotoxic T cells in immune mechanisms such as in graft versus host disease and rejection reaction.

3. progressive depletion of CD4+ T cells in the pathogenesis of AIDS
4. Cell death in viral infection
5. Heart disease eg: In acute myocardial infarction.
6. In degenerative disease of CNS.

8. pathologic ~~classification~~ Calcification

Definition

Abnormal deposits of Calcium salts occur in any tissues except bones and teeth

Dystrophic calcification

characterised by deposition of Calcium salts in dead or degenerated tissues with normal Calcium metabolism.

Morphological feature

→ Etiology and pathogenesis of two are different.

H and E stained sections

- Calcium salts appear as deeply Basophilic irregular

- Calcium deposits can be confirmed by special stains.
  → Silver impregnation
  → Alizarin Red S

Metastatic Calcification

→ Can occur in normal tissues whenever there is hypocalcemia.

→ Main cause of hypocalcemia
1. Increase Secretion of parathyroid hormone
2. Destruction of Bone due to the effect of Accelerated turn over.
3. Vit-D related disorders.
4. Renal failure

II. Short Answer

1. Vascular changes in Acute inflammation.

Alteration in the microvasculature is the earliest response to tissue injury

Haemodynamic changes

* transient vasoconstriction
* persistent progressive vasodilatation
* hydrostatic pressure
* slowing
* leucocytic margination.

Triple response

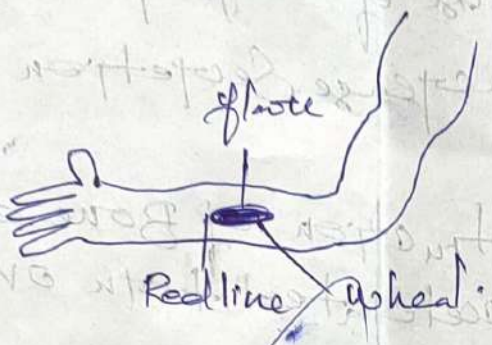

2. two Causes for fatty change liver

→ Drinking too much Alcohol.
→ obesity
→ type 1 diabeter
→ Metabolic Syndrome
→ angulia Resistance

3. Dif b/w

Transudate	Exudate
→ Usually seen in Congestive states	→ Seen in inflammatory states
→ increased HP	→ increase Vascular Permeability
→ Sp Gr: < 1.020	Sp G: > 1.020
→ Proteins: < 2gm/dl	> 2gm/dl.

5. two Oxygen free radical
   - → Superoxide Anion Radical
   - → Singlet Oxygen

   two Antioxidants
   - → Selenium
   - → Carotenoids.

General Pathology.

PROFESSOR & HOD
Department of General Pathology
Sri Venkateswara Dental College
Chennai-600 048

18/35

01. Inflammation:

Inflammation is defined as the local response of living mammalian tissues to injury from any agent.

It is a body defense reaction in order to eliminate or limit the ~~respon~~ spread of injurious agent, followed by removal of the necrosed cell and tissues.

Cellular Events.

The cellular phase of inflammation of 2 process.

1. Exudation of leucocytes
2. Phagocytosis.

Exudation of Leucocytes.

1. Changes in the formed elements of Blood.
2. Rolling and Adhesion.
3. Emigration
4. Chemotaxis.

Phagocytosis:

Phagocytosis is defined as the process of engulfment of solid particle material by the cells.

The cells performing this function are called phagocytes.

There are two types of phagocytic cells.

(i) Polymorphonuclear neutrophils (PMNs) appear early in acute inflammatory resp. sometimes called as microphages.

(ii) Circulating monocytes and fixed tissues mononuclear phagocytes, called as macrophages.

Phagocytosis of the microbe by polymorphs and macrophages involves 3 steps

Recognition and attachment

Engulfment

Killing and degradation.

Recognition and Attachment.

Phagocytosis is initiated by the expression of cell surface receptors on macrophages which recognise microorganisms. mannose receptor and scavange receptor.

opsonins. establish a bond between bacteria and the cell membrane of phagocytic cell.

1) IgG opsonin: is the Fc fragment of immunoglobul of it is the naturally-occuring antibody in the serum that coats the bacteria while the PMNs possess receptors for the same.

(ii) C3b opsonin is the fragment generated by activation of complement pathway. It is strongly chemotactic for attracting PMNs to bacteria.

lectins are carbohydrate binding proteins in re plasma which bind to bacterial cell wall.

2. Engulfment.

The opsonised particle or microbe bound to the surface of the phagocyte is ready to be engulfed this is accomplished by formation of cytoplasmic pseudopods around the particle due to formation of cytoplasmic pseudopods around the particle due to activation of actin filaments beneath cell wall, enveloping in a phagocytic vacuole.

3. Killing and Degradation.

Next is the stage of killing and degradation of microorganism to despose it off which is the major function of phagocytes as scavenger cells.

Intracellular mechanism.

(i) Oxidation bactericidal mechanism by oxygen free radicals.

a) MPO - dependent.

b) MPO - independent.

(ii) Oxidative bactericidal mechanism by lysosomal granules.

(iii) Non - oxedative bactericidal mechanism.

B. extracellular mechanism.

1. Granuloma.

It is defined as circumscribed tiny lesions about 1mm in diameter, composed predominantly of collection of modified macrophages called epitheloid cells & rimmed at periphery by lymphoid cells.

Pathogenesis of granuloma.

Cell injury
↓
Failure to digest agent.
↓
Weak acute inflammatory response
↓
Engulfment by marophages
↓
Persistence of injurious agent.

T-cell mediated response → Activation of CD_4^+ T cells monocyte chemotactic factor.

Poorly digestive agent.

↓

Accumulation of tissue marophages
Proliferation of T cells
↓
Macrophages activated IFN-γ

Transformation to epitheloid cells giant cells

secretion of fiproplastic proliferating cytokinis

↓

Granuloma.

Eg: TB, HIV associated leprosy.

2. Apoptosis: Pathologic calcification

Deposition of calcium salts, in tissues other than osteoid or enamel is called pathologic calcification.

Dystrophic calcification

Metastatic calcification

Dystrophic calcification:

characterized by deposition of Ca^{2+} salts in dead or degenerated tissues with normal calcium metabolism & normal serum Ca^{2+} level.

Metastatic calcification:

occurs in normal tissues & deranged Ca^{2+} metabolism.

Dystrophic calcification:

calcification in dead tissues

Liquefaction necrosis

Caseous necrosis

Fat necrosis

Infarts.

calcification in degenerated tissues

Dense old scars.

Atheromas.

3. Apoptosis

Apoptosis: It is a form of coordinated & internally programmed cell death.

Physiological processes

(i) organised cell destruction in sculting of tissues during development of embryo.

(ii) physiologic involution of cells in thormone dependent tissues: Eg: Endometrial shedding.

(iii) Normal cell destruction followed by replacement proliferation such as intestinal epithelial.

Pathologic processes.

(i) cell death in tumours exposed to chemotherapeutic agents.

(ii) cell death in viral infection.

II 1. Vascular changes in Acute inflammation.

Transient constriction

persistent progressive vasolation

↑ Local Hydrostatic pressure

stasis of blood.

2. Fatty change liver.

causes:

Starvation

Alcoholic liver disease

obesity.

Diabetes mellitus.

Protein calories malnutrition.

4. Pathologic Atrophy.

Starvation atrophy

Ischaemic atrophy.

Disease atrophy.

Eg: Myopathies

Neurophathic atrophy.

Eg: paliomyelitis.

Physiological Atrophy:

Atrophy of thymus in adult life.

Atrophy of brain with ageing

GENERAL PATHOLOGY

23/35

PROFESSOR & HOD
Department of General Pathology,
Sri Venkateswara Dental College & Hospital
Chennai- 603 103

HARIHARAN K.

ESSAY

1) INFLAMMATION

It is defined as the local response of living mammalian tissues to injury from any agent. It is defense reaction in order to eliminate or limit the spread of injurious agent, followed by removal of the necrosed cells and tissues.

CELLULAR EVENTS

Consists of 2 processes:

1) Exudation of leucocytes;
2) Phagocytosis.

1) Exudation of leucocytes.

- Escape of leucocytes from lumen to the intestinal tissue.
- PMNS compromise first line of defense followed later on by monocytes and macrophages.
- Changes leading to migration of leucocytes are as follows.

★ Changes in the formed elements of blood.

- Rate of blood flow increased due to vasodilatation, subsequently followed by stasis of bloodstream.

- Due to stasis central stream of cells widens and peripheral plasma zone becomes narrower because of loss of plasma by exudation. This phenomenon is known as margination.
- Pavementing is the coming close of neutrophils to the vessel wall.

★ Rolling And Adhesion

- Pavemented neutrophils slowly roll over the endothelial cells lining the vessel wall.
- Adhesion phase is the bond between the leucocytes and endothelial cells becoming firmer.
- The following cells bring about rolling and adhesion: Selectins [P-selectin, E-selectin, L-selectin] integrins, immunoglobulin gene superfamily adhesion molecules.

★ Emigration:

- Neutrophils lodged between the basement membrane by damaging it locally with secreted collagenases and escape out into the extravascular space
- Diapedesis is the ~~simultaneous exit~~ escape of red cells through gaps between the endothelial cells.

★ Chemotaxis.

- It is the transmigration of leucocytes after crossing several barriers to reach interstitial tissues is a chemotactic - factor mediated process

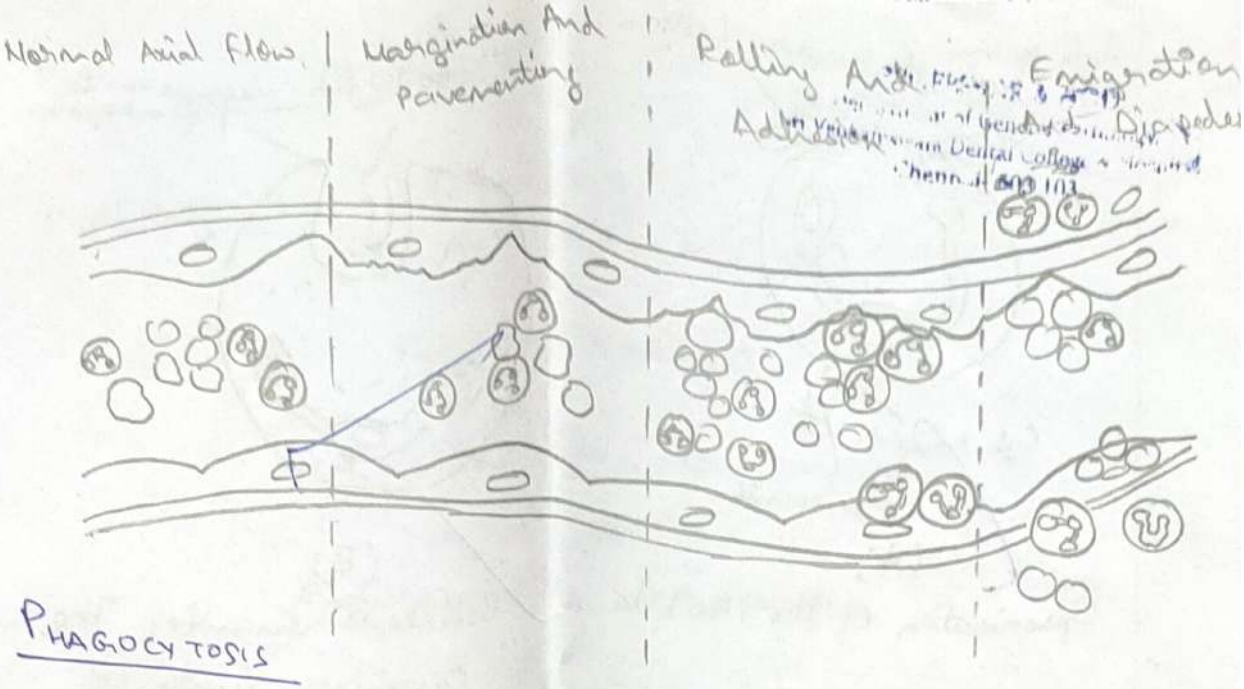

PHAGOCYTOSIS

- It is defined as the process of engulfment of solid particulate material by the cells (cell-eating)
- The cells performing this function are called as phagocytes. [PMNs and circulating monocytes, macrophages]
- PMNs → appear early in acute inflammatory response.
- ~~Monocytes~~ Macrophages and neutrophils produce several proteolytic enzymes – lysozyme, protease, collagenase, elastase, lipase, proteinase, gelatinase, and acid hydrolases.
- The steps involved are:

a) Recognition and attachment
b) Engulfment
c) Killing and degradation

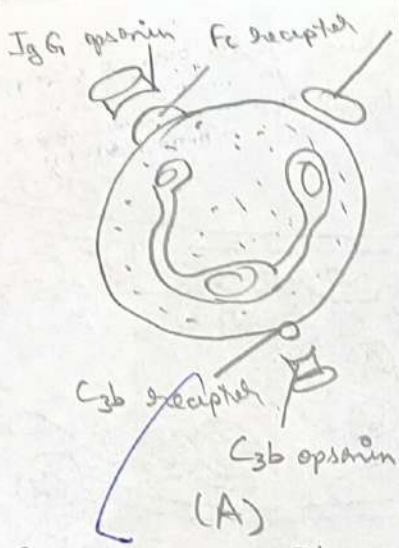

(A)

Opsonisation Of The Particle

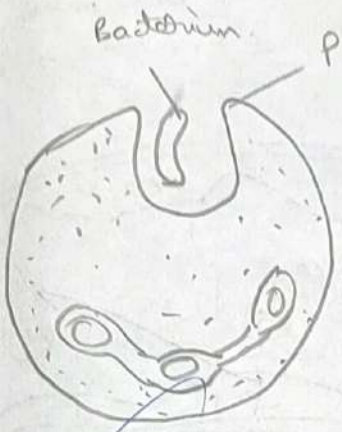

(B)

Pseudopod engulfing The Opsonised Particle.



(C)

Incorporation within The Cell And Degranulation

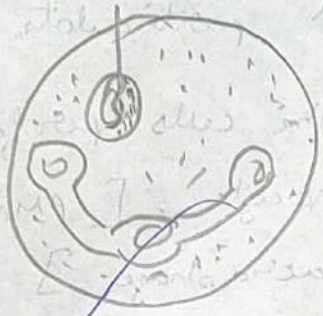

(D)

Phagolysosome formation After fusion of Lysosome Of The Cell

SHORT NOTES

1) **GRANULOMA.**

- It is defined as a circumscribed, tiny lesion, about 1mm in diameter, composed predominantly of collection of modified macrophages called epithelioid cells and rimmed at the periphery by lymphoid cells.

Pathogenesis Of Granuloma

Department of General Pathology
Sri Venkateswara Dental College & Hospital
Chennai- 603 103

Cell injury
(eg. by M-tuberculosis, talc)
↓
Failure to digest agent
↓
Weak acute inflammatory response
↓
Engulfment by macrophages
↓
Persistence of injurious agent

↙ ↘

Tcell-mediated immune response

Poorly digestible agent

↘ ↙

- Activation of CD_4+ T cells
(release of lymphokines IL-1, IL-2, growth factors IFN-γ and TNF-α)
- Monocyte chemotactic factor

↓

- Accumulation of tissue macrophages.
- (Proliferation of T cells

↓

Macrophages activated by IFN-γ

↙ ↘

Transformation to epithelioid cells, giant cells.

Secretion of fibroblastic proliferating cytokines (TGF-β, PDGF)

↘ ↙

GRANULOMA

Composition

- Epithelioid cells
- Multinucleate giant cells
- Lymphoid cells
- Necrosis
- Fibrosis

Examples

Tuberculosis, leprosy, fungal infections, schistosomiasis, foreign particles, etc.

2) Apoptosis

- It is a form of 'coordinated and internally programmed cell death'.

Apoptosis Morphologic features

- Involvement of single cells or small clusters of cells in the background of viable cells.
- Nuclear chromatin is condensed under the nuclear membrane ie pyknosis.
- Cell membrane may show blebs or projections on the surface.
- No acute inflammatory reaction around apoptosis.

Causes

a) Physiologic Processes:

- Organised cell destruction in tissues during development of embryo.
- Physiologic involution of cells in hormone-dependent

Department of General ...
Vankateswara Dental College ...
Chennai - 603 103

tissues.

- Normal cell destruction followed by replacement proliferation such as in intestinal epithelium.

b) Pathologic Processes:

- Cell death in tumors exposed to chemotherapeutic agents.
- Cell death in viral infections eg: formation of Councilman bodies in viral hepatitis.
- Pathologic atrophy of organs and tissues.

Molecular Mechanism

- Initiators of apoptosis
  - Withdrawal of normal cell survival signals. Eg absence of certain hormones, growth factors.
  - Agents of cell injury eg, heat, radiation, hypoxia, free radicals.
- Initial steps in apoptosis.
  - Intrinsic pathway.
  - Extrinsic pathway.
- Final phase of apoptosis.
  - Activation of caspases
  - Activation of death receptors.
  - Cell death.
- Phagocytosis

3) Pathologic Calcification

- Deposition of calcium salts in tissues other than osteoid or enamel is called pathologic or heterotopic calcification.
- Two types:

a) Dystrophic calcification:

- Deposition of calcium salts in dead or degenerated tissues with normal calcium metabolism and normal serum calcium level.
- 2 types of causes: → Calcification in dead tissue
  → Calcification of degenerated tissue.

b) Metastatic Calcification:

- Occurs in apparently normal tissues and is associated with deranged calcium metabolism and hypercalcaemia.
- 2 group of causes: → Excessive mobilisation of calcium from the bone.
  → Excessive absorption of calcium from the gut.

Histologically

- In routine H and E stained sections, calcium salts appear as deeply basophilic, irregular and granular clumps.
- Prussian blue reaction in Perls stain.

SHORT ANSWERS

PROFESSOR & HOD
Department of General Pathology,
Sri Venkateswara Dental College & Hospital,
Chennai- 603 103

1) Vascular changes in acute inflammation

1) Transient vasoconstriction
2) Persistent progressive vasodilatation
3) local hydrostatic pressure.
4) Slowing or stasis of microcirculation.
5) leucocytic margination.

2) Two Causes

1) Conditions with excess fat.
ie conditions in which the capacity of the liver to metabolise fat is exceeded eg.
- Obesity
- Diabetes mellitus
- Congenital hyperlipidaemia

2) Liver cell damage
ie conditions in which fat cannot be metabolised due to liver cell injury.
eg.:
- Alcoholic liver disease
- Starvation
- Chronic illnesses
- Hypoxia
- Hepatotoxins
- Reye's syndrome.
- Drug - induced liver cell injury.

3) Transudate and Exudate.

Transudate	Exudate
• Filtrate of blood plasma without changes in endothelial permeability	• Oedema of inflamed tissue associated with increased vascular permeability
• Non-inflammatory oedema	• Inflammatory oedema
• pH > 7.3	• pH < 7.3
• LDH low	• LDH High
• Glucose same as in plasma	• Glucose content is low (less than 60mg/dl)
• Protein content is low	• Protein content is high

5) 2 oxygen free radicals.
- Anion radical. (O_2^-)
- Hydroxyl radical

Antioxidants —
- Vitamin C.
- Beta carotene
- Carotenoids
- Vitamin E

General Pathology

DR. [illegible]
Department of General Pathology
Sri Venkateswara Dental College & Hospital
Chennai- 603 103

29/35 HEMA. S.M
II-BDS.

I. Essay:

1. Define Inflammation. Discuss the cellular events of acute inflammation with special emphasis on phagocytosis.

Inflammation: It is defined as the local response of living mammalian tissues to injury from any agent.

The agents causing inflammation are,

a) Infective agents - Bacteria, virus, fungi.

b) Immunological agents - cell-mediated & antigen-antibody reactions.

c) physical agents - heat, cold, radiation.

d) chemical agents - organic & inorganic poisons.

e) Foreign materials.

Signs of inflammation:

a) Rubor (Redness)

b) Tumor (Swelling)

c) Calor (heat).

d) Dolar (pain).

Types of Inflammation:

A) Acute inflammation. It is of short duration and represents the early body reaction, resolves quickly and is followed by healing.

B) Chronic inflammation: It is of longer duration and occurs after delay, either after the causative agent of acute inflammation persists for a long time.

Cellular events of Acute Inflammatory response.

It consists of 2 processes:

A) Exudation of leukocytes.

B) Phagocytosis.

Exudation of leukocytes:

The escape of leukocytes from the lumen of microvasculature to the interstitial tissue is the most important feature of inflammatory response.

Sequence of changes in the exudation of leukocytes:-

A) Changes in the formed elements of blood.
B) Rolling & adhesion.
C) Emigration.
D) Chemotaxis.

Normal Axial flow

Department of General Pathology.
Sri Venkateswara Dental College & Hospital
Chennai- 603 103



Migration & parementing.



Rolling and adhesion.



Emigration and diapedesis.



Chemotaxis:

The transmigration of leukocytes after crossing several barriers to reach the interstitial tissues is a chemotactic factor-mediated called chemotaxis.

The following agents acts as potent chemotactic substances for neutrophils:

a) Leukotriene B4.
b) C5a & C3a.
c) Cytokines.
d) Soluble bacterial products.

Phagocytosis:

→ It is defined as the process of engulfment of solid particulate material by the cells.

→ The cells performing this function are called phagocytes. There are 2 main types of phagocytic cells:

a) polymorphonuclear neutrophils (PMNs) (Microphages)
b) Circulating monocytes & fixed tissue mononuclear phagocytes (Macrophages).

Phagocytosis of the microbe by polymorphs and macrophages involves the following 3 steps :-

A) Recognition & attachment

B) Engulfment.

C) Killing & degradation.

Stages of phagocytosis of a foreign particle :-

A). Opsonisation of the particle.

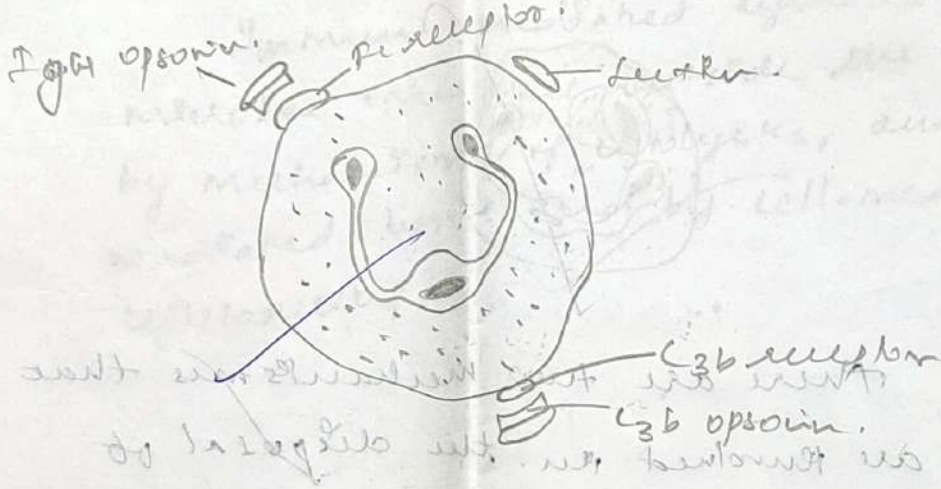

B). Pseudopod engulfing the opsonised particle.

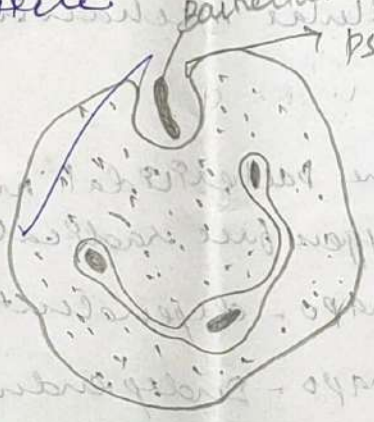

c) Incorporation within the cell.

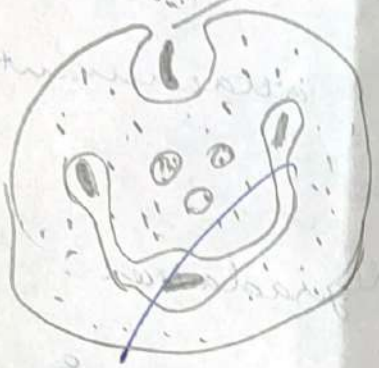

D). phago lysosome formation after fusion of lysosome to the cell.

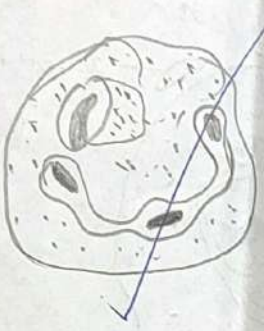

There are two mechanisms that are involved in the disposal of microorganisms.

A) Intracellular mechanisms.

~~B) Other~~

B) Oxidative bactericidal mechanism by oxygen free radicals.

a) NADPO - dependent.

b) NADPO - Independent.

PROFESSOR & HOD
Department of General Pathology
Sri Venkateswara Dental College & Hospital
Chennai - 600 078

ii) oxidative bactericidal mechanism by lysosomal granules.

iii) Non-oxidative bactericidal mechanism.

b). Extracellular mechanism.

i) Granules: Degranulation of macrophages and neutrophils explained above continues to exert its effects of proteolysis outside the cells as well.

ii) Immune mechanism:-

Immune mediated lysis of microbes takes place outside the cells by mechanisms of cytolysis; antibody-mediated lysis and by cell-mediated cytotoxicity.

II. Short notes:

1. Granuloma.

It is defined as a circumscribed, tiny lesion, about 1mm in diameter, composed predominantly of collection of modified macrophages called epithelioid cells, and rimmed at the periphery by lymphoid cells.

Mechanism of evolution of a granuloma:-

Cell injury.

↓

Failure to digest agent

↓

Weak acute inflammatory response.

↓

Engulfment by macrophages.

↓

persistence of injurious agents.

↙ T-cell mediated immune response.

↘ Poorly digestible agent.

↓ Activation of CD4+ T cells. Monocyte chemotactic factor.

Monocyte chemotactic factor

↓

Accumulation of tissue macrophages.

↓ proliferation of T cells.

↓

Macrophages activated by IFN-γ

→ Transformation to epithelioid cells, giant cells.

→ Secretion of fibroblastic proliferating cytokines.

→ Granuloma.

Composition of Granuloma :-

1). Epithelioid cells.

2) Multinucleate giant cells.

3). Lymphoid cells.

4) Necrosis.

5) Fibrosis

Example :-

1) Tuberculosis.

2) HIV associated tuberculosis.

3) Leprosy.

4) Syphilis.

2) Apoptosis :-

Apoptosis is a form of "coordinated and intrinsically programmed cell death" having significance in a variety of physiologic and pathologic conditions.

Physiologic Process :-

1) Organised cell destruction in sculpting of tissues during development of embryo.
2) physiologic involution of cells in hormone-dependent tissues.
3) Normal cell destruction followed by replacement proliferation such as in intestinal epithelium.
4) Involution of the thymus in early age.

Pathologic process :-

1) cell death in tumors exposed to chemotherapeutic agents.
2) cell death in viral infection.

pathologic calcification :-

Department of General Pathology
Dr. Venkataswara Dental College
Chennai-603 103

Deposition of calcium salts in tissues other than osteoid or enamel is called pathologic calcification.

There are two types :-

a) Dystrophic calcification

b) Metastatic calcification.

Dystrophic calcification :-

Characterised by deposition of Ca^{2+} salts in dead or degenerated tissues with normal calcium metabolism and normal serum Ca^{2+} level.

Metastatic calcification :-

Occurs in normal tissues and deranged Ca^{2+} metabolism.

Dystrophic calcification.

↙ ↘

Calcification in dead tissues.

→ Liquefactive necrosis.
→ Caseous necrosis.
→ Fat necrosis.
→ Infarcts.

Calcification in degenerated tissues.

→ Dense old scars.
→ Atheromas.

II.

1. Vascular changes in Acute Inflammation :-

a) Transient constriction.
b) Persistent progressive vasolation.
c) Increased local hydrostatic pressure.
d) Stasis of blood.

2. Fatty change liver.

Causes :- Starvation
Alcoholic liver disease
Obesity.
Diabetes mellitus.
Protein calories malnutrition.

PROFESSOR & HOD
Department of General Pathology,
Sri Venkateswara Dental College & Hospital,
Chennai- 603 103

4). Pathologic Atrophy:

-> Starvation atrophy
-> Ischaemic atrophy
-> Disuse atrophy
-> Neuropathic atrophy.

Physiological atrophy:-

-> Atrophy of thymus in adult life.
-> Atrophy of brain with ageing.

5) 2 oxygen free radicals - Anion radical
(O_2^-)
hyroxyl oradical.

Anti oxidants - Vitamin C
Beta carotene
Carotenoids.
Vitamin E.

General Pathology

JANANI. D
Dept. of General Pathology
Department of General Pathology
Sri Venkateswara Dental College & Hospital
Chennai - 600 127

87/95

I.

1. Inflammation:

Inflammation is defined as the local response of living mammalian tissues to injury from any agent. It is a body defense reaction in order to eliminate or limit the spread of injurious agent, followed by removal of the necrosed cells and tissues.

Cellular events of Acute inflammation:-

The cellular phase of inflammation consists of 2 processes

i) Exudation of leucocyte

ii) phagocytosis

Exudation of leucocyte

1. changes in the formed elements of blood
2. Rolling adhesion
3. EMIGRATION
4. Chemotaxis

phagocytosis:-

phagocytosis is defined as the process of engulfment of solid particulate material by the cells.

The cells performing this function are called phagocytes. There are 2 main types of phagocytic cells:

(i) polymorphonuclear neutrophils (PMNs) which appear early in acute inflammatory response, sometimes called as microphages.

(ii) Circulating monocytes and fixed tissue mononuclear phagocytes, commonly called as macrophages.

phagocytosis of the microbe by polymorphs and macrophages involves the following 3 steps.

1. Recognition and attachment
2. Engulfment
3. Killing and degradation

1. Recognition and attachment :-

phagocytosis is initiated by the expression of cell surface receptors on macrophages which recognise microorganisms mannose receptor & Scavenger receptor.

The process of phagocytosis is further enhanced when microorganism are coated with specific proteins, opsonins, from the serum and the process is called opsonisation.

The main opsonins present in the serum and their corresponding receptors on the surface of phagocytic cells are

(i) IgG opsonin is the Fc fragment of immunoglobulin G; it is naturally occurring antibody in the serum that coats the bacteria while the PMN is possess receptors for the same.

(ii) C3b opsonin is the fragment generated by activation of complement pathway. It is strongly chemotactic for attracting PMN to bacteria

(iii) Lectins are carbohydrate binding proteins in plasma which bind to bacterial cell wall.

Department of General Pathology
Sri Venkateswara Dental College & Hospital
Chennai-600 103

2. ENGULFMENT:

The opsonised particle or microbe bound to the surface of phagocyte is ready to be engulfed. This is accompanied by formation of cytoplasmic pseudopods around the particle, due to activation of actin filaments beneath cell wall, enveloping it in a phagocytic vacuole.

Eventually, plasma membrane enclosing the particle breaks from cell surface so that membrane-lined phagocytic vacuole (or) phagosome becomes internalised in the cell and lies free in cell cytoplasm. The phagosome fuses with one or more lysosomes of the cell and form bigger vacuoles called phagolysosome.

3. Killing and degradation

Next is the stage of killing and degradation of microorganism to dispose it off which is major function of phagocytes as scavenger cells.

The microorganism after being killed by antibacterial substances are degraded by hydrolytic enzymes.

In general, following mechanisms are involved in disposal of microorganisms

A. Intracellular mechanism

(i) Oxidative bactericidal mechanism by oxygen free radicals

a) MPO - dependent

b) MPO - independent

(ii) Oxidative bactericidal mechanism by cytoplasmic granules

(iii) Non-oxidative bactericidal mechanism.

B. Extracellular mechanism.

Department of General Pathology
Sri Venkateswara Dental College
Chennai-603 103

Granuloma :-

It is defined as circumscribed, tiny lesion about 1mm in diameter, composed predominantly of collection of modified macrophages called epithelioid cells and limited at periphery by lymphoid cells.

Pathogenesis of granuloma :-

cell injury

↓

Failure to digest agent

↓

weak acute inflammatory response

↓

engulfment by macrophages

↓

persistence of injurious agent

T-cell mediated immuno response

poorly digestible agent

↓

Activation of CD_4 T cells

monocyte chemotactic factor

↓

Accumulation of tissue macrophages. proliferation of T-cells

↓

macrophages activated

IFN-γ

↓

transformation to epithelioid cells giant cells

secretion of fibroblastic proliferating cytokines

Examples of granuloma:-

Tuberculosis, HIV associated tuberculosis, leprosy, Syphilis, Cat scratch disease.

2) Apoptosis:-

It is a form of coordinated and internally programmed cell death.

physiological processes:-

(i) Organised cell destruction in sculting of tissues during development of embryo

(ii) physiologic involution of cells in hormone-dependent tissues eg: endometrial shedding

(iii) Normal cell destruction followed by replacement proliferation such as intestinal epithelia

pathologic processes:-

1. cell death in tumors exposed to chemotherapeutic agents.

2 cell death in Viral infections.

Department of General ...
Sri Venkateswara Dental College ...
Chennai- 600 103

3. pathologic calcification:-

Deposition of calcium salts in tissue other than osteoid or enamel is called pathologic calcification

→ Dystrophic calcification

→ metastatic calcification.

Dystrophic calcification:-

characterized by deposition of Ca^{2+} salts on dead or degenerated tissues with normal calcium metabolism and normal serum Ca^{2+} level.

Metastatic calcification:-

Occurs in normal tissues and deranged Ca^{2+} metabolism.

Dystrophic calcification

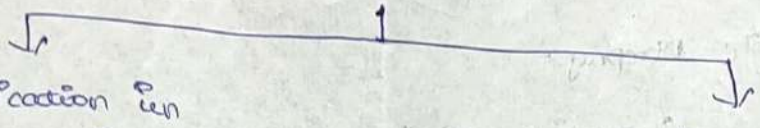

Calcification in dead tissues

→ Liquefaction necrosis
→ caseous necrosis
→ Fat necrosis
→ Infarcts

Calcification in degenerated tissues

→ dense ds scars
→ Atheromas.

III.

1. Vascular changes in acute inflammation:-

→ transient constriction

→ persistent progressive vasodilation

→ ↑ hydrostatic pressure

→ stasis of blood

2. Fatty change liver:-

Causes - Starvation

Alcoholic liver disease

Obesity

Diabetes mellitus

protein calories malnutrition

4. pathologic Atrophy -

Starvation atrophy

Ischaemic atrophy

disuse atrophy eg. myopathies

Neuropathic atrophy

eg. polio myelitis

Physiological Atrophy - Atrophy of thymus in adult life

Atrophy of brain with ageing

General pathology

PROFESSOR & HOD
Department of General Pathology,
Sri Venkateswara Dental College & Hospital
Chennai - 603 103

22/3c

Kamarikayan.

I. Essay.

1) Inflammation.

It is defined as the local response of living mammalian tissues to injury from any agent. It is a body defense reaction in order to eliminate or limit the spread of injurious agent, followed by removal of the removed cells & tissues.

Acute inflammation

→ It is of short duration and represent the early body reaction, resolves quickly and is usually followed by healing.

Features:

→ accumulation of fluid & plasma at the affected site.

→ Intravascular activation of platelets

→ Polymorphonuclear neutrophils as inflammatory cells

Events of acute inflammation

→ Vascular events

→ cellular events

Vascular event:

→ Alteration in the microvascular is the earliest response to tissue injury.

Hemodynamic changes

→ change in vascular flow & calibre of small blood vessel in injured tissue.

Sequence of change

Transient vasoconstriction

↓

persistent progressive vasodilatation

↓

Hydrostatic pressure

↓

slowing or stasis of microcirculation

↓

leucocytic margination or peripheral orientation of leucocytes.

Tripe response

↳ lewis experiment.

↓

Change in skin of inner aspect of forearm by firm stroking with a blunt point. The reaction is called tripe response or red wire response

Red line → few seconds after showing due to local vasodilatation capillaries & venules

PROFESSOR & ...
Department of General ...
Sri Venkateswara Dental College & Hospital
Chennai- 603 103

Flare → bright reddish appearance of fluid surrounding the red line seen from vasodilatation of adjacent arterioles.

Wheal → swelling or edema of surrounding skin owing due to transudation of fluid into the extravascular space.

Clinical sign of inflammation
↳ redness, heat, swelling, pain

Pathogenesis

Starling hypothesis → appearance of inflammatory edema due to increased vascular permeability of microvascular bed.

→ outward movement of fluid from microcirculation
↓
Intervascular hydrostatic pressure.
↓
Colloid osmotic pressure of interstitial fluid

→ Inward movement of interstitial fluid into circulation

Pattern of increased vascular permeability

↓

Contraction of endothelial cell.

↓

Contraction or mild endothelial damage.

Direct injury to endothelial cells.

↓

Leukocyte - mediated endothelial injury

↓

Leakage in neovasculature



Normal axial blood flow

↓

marginalization & paravascular

↓

Rolling & adherence

↓

Emigration & Diapedesis

PROFESSOR & HOD
Department of General Pathology,
Sri Venkateswara Dental College & Hospital
Chennai-603 103

Cellular events

→ exudation of leucocytes.

↓

① Change in formed elements of blood

↓

② rolling phase & adhesion

Selectin

↓

P selectin

E selectin

L selectin

preformed & stored in endothelial cells & platelets called CD62.

Ligokine activated endothelial cells (ECAM) → rolling & adhesion.

Integrins

↓

CD11

CD18.

Immunoglobulin gene superfamily adhesion molecules.

↓

ICAM-1 (CD54)

PECAM-1 (CD31)

LCAM (lymphocyte & neuropilin) → homing of circulating lymphocytes to endothelial cells.

③ Emigration

↓

Diapedesis.

↓

escape of red cells through

gap between the endothelial cells

↓

passive phenomenon

↓

RBC forced through endothelial defect left after emigration of leucocytes

↓

hemorrhagic appearance to inflammatory exudate

(4) chemotaxis

↓

emigration of leucocytes after crossing several barriers to reach the interstitial tissue in chemotactic-factor mediated process.

↓

Boyden's chamber experiment

↓

Millipore filter (3 μm pore)

↓

separate the suspension of leucocyte from test solution in tissue culture chamber.

Agents are as chemotactic potent substances

→ leukotriene B4 (LT-B4) is in a product of lipoxygenase pathway of arachidonic acid metabolites

→ Component of complement system (C5a, C3a)

→ Cytokines (IL-8)

→ Lipid derived products

Dept. of Periodontology & Implantology
Department of General Medicine
Sri Venkateswara Dental College & Hospital
Chennai - 600 103

Phagocytosis

Process of engulfment of solid particulate material by the cells.

↓

Phagocytes

↓

PMNs → early in acute inflammatory response (microphages).

circulating monocytes → fixed tissue mononuclear phagocytes → macrophages

↓

Neutrophils & macrophages → reach tissue space produce proteolytic enzyme (hyaluronidase, collagenase, protease).

↓

degrade wall & extracellular matrix.

3 Steps

① Recognition & attachment.

↓

Phagocytic cells expression of cell surface receptor on macrophage.

↓

Opsonic receptor or Scavenger receptor

↓

enhanced when microgranium coated with protein opsonin.

↓

opsonization

↓

IgG opsonin → Fc fragment of IgG.

↓

C3b opsonin (fragment generated by activation of complement pathway).

↓

lectin (carbohydrate binding protein).

② Engulfment

↓

opsonized particle sounded to surface of phagocyte.

↓

formation of cytoplasmic pseudopods around particle

↓

activation of actin filaments

↓

phagosome fuses with lysosomes of cells & former bigger vanish

↓

phagolysosome.

PROFESSOR & HOD
Department of General Pathology
Sri Venkateswara Dental College & Hospital
Chennai- 603 103.

(3) Killing & degradation

Intracellular mechanism → Extracellular mechanism

(1) Oxidative bactericidal mechanism by oxygen free radicals:

MPO dependent → MPO independent

(2) Oxidative bactericidal mechanism by hypochlorous granules

(3) Non oxidative bactericidal mechanism

Respiratory burst
↓ NADPH oxidase.
Activated by phagocytic leucocyte.

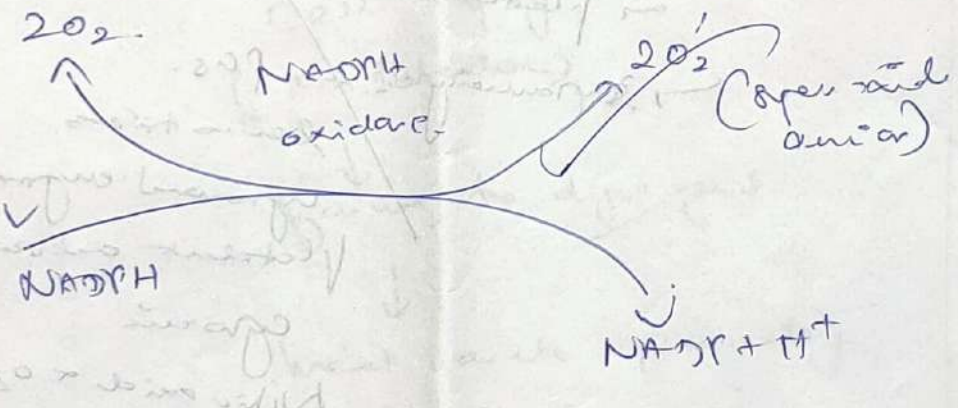

$2O_2' + 2H^+ \rightarrow H_2O_2$
(Hydrogen peroxide)

$H_2O_2 \xrightarrow[Cl^-, Br^-, I^-]{MPO} HOCl + H_2O$ (Hypochlorous acid)

$H_2O_2 \xrightarrow[\text{Haber-Weiss rxn}]{O_2^-} OH^-$

$\xrightarrow[\text{Fenton reaction}]{Fe^{++}} OH^-$ (hydroxyl radical)

Extracellular mechanism.

Granules → Degranulation of mastophages & neurophils

Immune mechanism → Immune mediated lysis of microbes.

Mediation of inflammation

cell derived → mast cells → Histamine → ↑ permeability

→ platelets → Serotonin → ↑ permeability

→ Inflammatory cells → PGs.

leukotrienes

lysosomal enzyme

platelet activating factor.

cytokine

Nitric oxide & O_2 metabolite

Plasma protein derived → clotting & fibrinolytic system

→ kinin system

→ Complement system.

II. Q-A note

PROFESSOR & HOD
Department of General Pathology,
Sri Venkateswara Dental College
Chennai

1) Granuloma :-

Defined a circumscribed tiny lesion about 1mm in diameter, composed predominantly of collection of modified macrophages called epithelioid cells, & rimmed at periphery by lymphoid cells.

↓

Localised inflammatory mass.

Pathogenesis :-

type II granulomatous hypersensitivity reaction

↓

cell injury.
(M. tuberculosis)

↓

failure to digest agent

↓

weak acute inflammatory response

↓

Engulfment by macrophages

↓

persistence of injurious agent

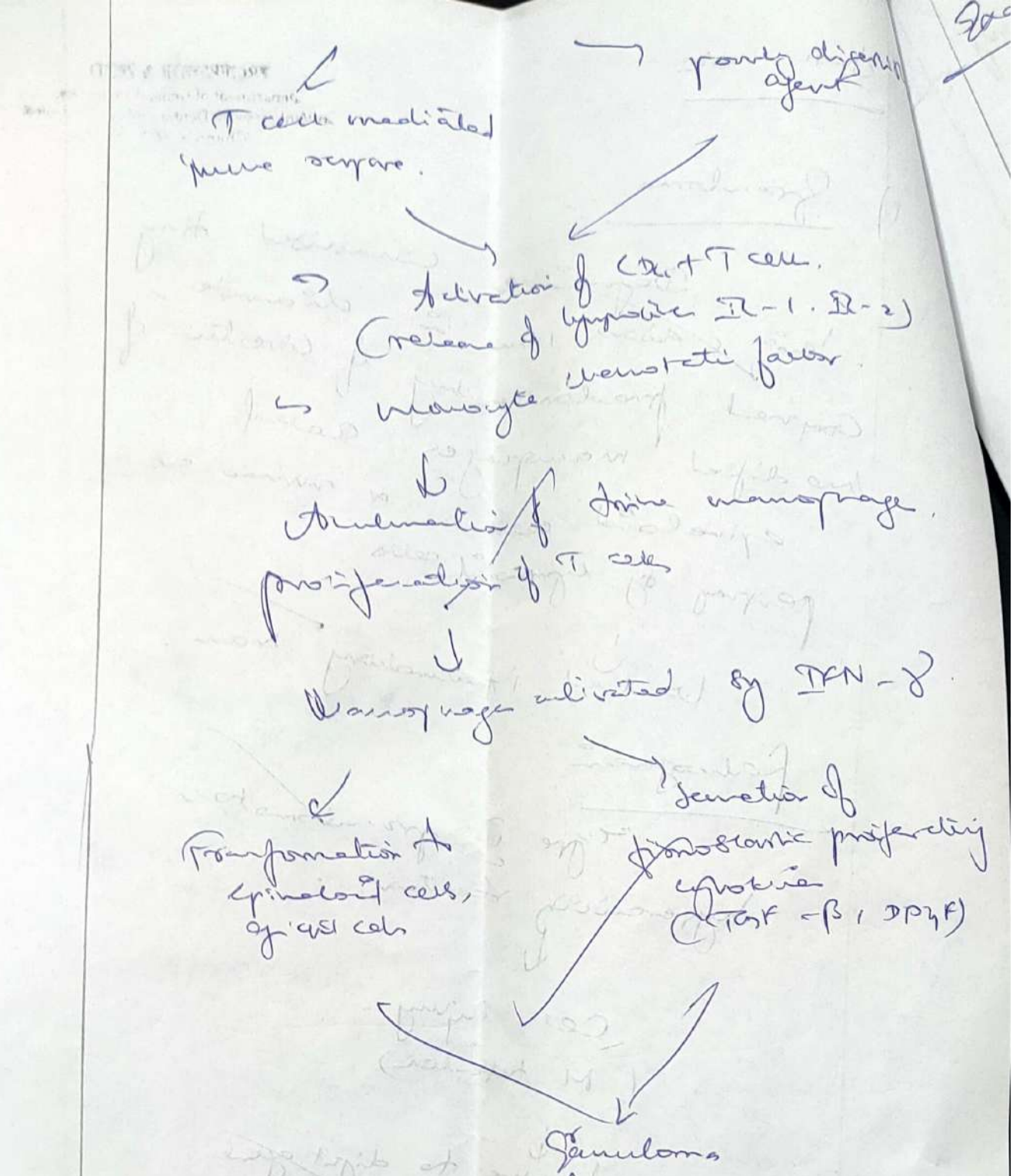

T cell mediated
pure scrape.

→ poorly digestible agent

→ Activation of CD4 + T cells.
(release of lymphokine IL-1, IL-2)
→ monocyte chemotactic factor.

↓

Accumulation of fine macrophage.
proliferation of T cells

↓

Macrophage activated by IFN-γ.

→ Transformation to epithelioid cells, giant cells

→ Secretion of fibroblastic proliferating lymphokine (TGF-β, DPGF)

↓

Granuloma

Comparison of granuloma

→ Epithelioid cells.
→ mononucleate giant cells
→ lymphoid cells
→ neurin
→ fibrosis

PROFESSOR & HOD
Department of General Pathology
Dr Venkateswara Dental College & Hospital
Chennai- 603 103

Example

Tuberculosis

↓

Tubercle bacilli (Koch's bacilli).

↓

Mycobacterium tuberculosis

↓

Mode of transmission.

↓

Inhalation of gamma

Ingestion of gamma

Inoculation of gamma

Transplacental route.

↓

Pathogenesis

↓

Myocide (Cord factor)

Sulfuric acids.

1° Ingestion 2° Ingestion

↓

Tuberculin (Mantoux) skin test

↓

Evaluation of tubercle.

↓

Injected into guinea pig

↓

Phagocytosing the tubercle.

↓

B cells form antibodies

↓

2 - 3 days (epithelioid cells)

↓

Tight cluster of granulomas

↓

multinucleated giant cells.

↓

Langhans type
(horse & ring).

↓

10–14 days. center of cellular mass → caseation necrosis

chalky appearance & high lipid content

↓

development of caseation necrosis due to interaction of mycobacteria with activated T-cells.

(2) Apoptosis

— form of coordinated & internally programmed cell death → having a significance in variety of physiologic & pathologic conditions. (cell suicide).

↓

Apoptosis in silicosis process

(1) Physiologic process

→ organized cell destruction in sculpting of tissue during development of embryo

→ physiologic involution of cells in
hormone - dependent tissue

→ normal cell deletion followed by
replacement proliferation such as in
intestinal epithelium

→ Involution of thymus.

Pathologic process

→ cell death in tissue exposed to
chemotherapeutic agent.

→ cell death by cytotoxic T cells in
tissue mechanism (graph vs host disease)

→ cell death in viral infection.

→ progressive depletion of cells
→ pathologic atrophy of organ & tissues

→ cell death in response to low
dose of injurious agent.

→ In degenerative disease of CNS

→ Heart diseases (MI)

Biochemical changes

→ proteolysis of cytoskeletal proteins

→ protein - protein cross linkage.

→ After initial formation of nuclear,
there is a fragmentation of
chromatin by activation of
nuclease.

→ Appearance of phosphatidylinositol on the outer surface of cell membrane.

→ Some form of apoptosis appearance of adhesion glycoprotein thrombospodin

→ Appearance of phosphatidylinositol

Molecular mechanism

① Initiation of apoptosis

Transmission
Intracellular
Extracellular

→ Target of cell injury.

Withdrawal of normal cell survival signal

② Initial step in apoptosis

↓

Activation

↓

Pressure of programmed cell death

↓

Activation of Caspases

Activation of death receptor (CD95)

Activation of pointer connecting genes

cell death

in

phagocytosis

3) pathologic calcification

Deposition of calcium salts in tissue other than osteoid or enamel.

→ Dystrophic calcification

↓

Characterised by deposition of Ca^{2+} salts in dead or degenerated tissue with normal calcium metabolism & normal serum Ca^{2+} level

→ Metastatic calcification

↓

Occur in normal tissue & changes Ca^{2+} metabolism.

dystrophic calcification

Calcification in dead tissue
- Liquefaction necrosis
- Caseous necrosis
- fat necrosis
- Infarct

Calcification in degenerated tissue
- dense old scars
- Atheromas.

PROFESSOR & HOD
Department of General Pathology,
Dr Venkateswara Dental College & Hospital
Chennai-600 103

(1) Fatty change liver

Cause — Starvation
of alcoholic liver disease
obesity
diabetes mellitus.
protein calorie malnutrition

(2) Pathological Atrophy → Senile atrophy
Ischemic atrophy
Pressure atrophy
& myopathies
— neuropathic atrophy
poliomyelitis

Physiological atrophy — Atrophy of thymus in adult life
Atrophy of brain with ageing.

(3) 2 oxygen free radicals — Superoxide radical (O_2^-)
Hydroxyl radical

Antioxidants — Vitamin C
β-carotene
Superoxide dismutase
Vitamin-E.

General pathology

Kaviya. P.

Department of General Pathology,
Sri Venkateswara Dental College & Hospital,
Chennai - 603 103

1. Inflammation : Inflammation is defined as the local response of living mammalian tissues to injury from any agent. It is a body defence reaction in order to eliminate or limit spread of injurious agent, followed by removal of necrosed cells & tissues.

Signs of Inflammation : rubor
tumor
calor
dolor

Acute Inflammation : It is divided into 2 Main events

- Vascular events
- Cellular events
  - Exudation of leucocytes
    - changes in formed elements of Blood
    - Rolling & Adhesion
    - Emmigration
    - chemotaxis
  - Phagocytosis
    - Recognition & Attachment
    - Engulfment
    - killing & degradati

1) Vascular events.

Earliest response to injury is Alteration in microvascula

Sequence of changes is

i) Transient Vasoconstriction.

ii) Persistent progressive Vasodilatation.

iii) Increase in local hydrostatic pressure results in transudation of fluid into Extracellular space.

iv) Stasis of blood followed by leucocytic margination or peripheral orientation of leucocytes.

2) Cellular events

i) Exudation of leucocytes: Polymorphonuclear neutrophils comprise 1st line of body defence in acute Inflamatio

A) changes in formed elements of Blood.

→ In early stage of inflammation, rate of flow of blood increases due to vasodilatation. Then stasis of blood occurs, due to this, central stream of cells widens e Peripheral plasma zone becomes narrower due to loss of plasma by exudation → called Margination.

So, Neutrophils come close to vessel wall, known as Pavementing.

ling & Adhesion

Department of Genetics
Sri Venkateswara Dental College & Hospital
Chennai- 603 103

→ Marginated & pavemented neutrophils roll ove the endothelial cells lining tining vascular wall.

Cell adhesion Molecules bring about rolling & adhesion.

→ Selectins → P selectin - involves rolling
→ E-selectin - involves rolling & adhesion
→ L-Selectin - homing of circulating lymphocytes to endothelial cells in lymph nodes.

→ Integrins

→ Immunoglobulin gene superfamily adhesion molecules.

Emigration: Neutrophils move out into the intracellular fluid through gaps in endothelial cells.

Chemotaxis: It is the signalling for the transmigration of leucocytes.

Phagocytosis: The process of engulfment of solid or particulate material by cells.

2 types of phagocytic cells

Polymorphonuclear Neutrophils	Circulating Monocyte - Macrophages.

Patho

Steps in phagocytosis

→ Recognition & Attachment.

Cell surface receptors on macrophages which recognise Microorganisms : Mannose receptor & Scavenger receptor.

The phagocytosis is by coating organism with opsonins.

- IgG opsonin
- C3b opsonin
- Lectins.

- Engulfment : Opsonised particle bound to surface of phagocyte is ready to be engulfed.

Killing & degradation : Intracellular & Extracellular Mechanism.

II Short notes :

1) Granuloma :. It is defined as circumscribed, tiny lesions about 1mm in diameter. composed Predominantly of collection of modified macrophages called epithelioid cells & rimmed at periphery by lymphoid cells

Pathogenesis of granuloma

PROFESSOR & HOD
Department of General Pathology
Sri Venkateswara Dental College

cell injury
↓
failure to digest agent
↓
Weak acute inflammatory response
↓
Engulfment by macrophages.
↓
Persistence of injurious agent

T-cell mediated immune response	Poorly digestible agent

↓
Activation of CD_4+T cells.
monocyte chemotactic factor
↓
Accumulation of tissue macrophages.
Proliferation of T-cells.
↓
Macrophages activated IFN-γ.

Transformation to epitheloid cells giant cells.	Secretion of Fibroblasti proliferating cytokines

↓
Granuloma

Examples of Granuloma: Tuberculosis, HIV Associated Tuberculosis, Leprosy, & Syphilis, cat scratch disease.

2) Apoptosis.

Apoptosis: It is a form of coordinated & internally Programmed cell death.

Physiological processes

i) Organised cell destruction in sculting of tissues during development of embryo

ii) Physiologic involution of cells in hormone-dependent tissues eg: endometrial shedding

iii) Normal cell destruction followed by replacement proliferation such as intestinal epithelial.

Pathologic processes

1) cell death in tumors exposed to chemotherapeutic agents.

ii) cell death in viral infections.

3) Pathologic calcification

Deposition of calcium salts in tissues other than osteoid or enamel is called pathologic calcification.

→ Dystrophic calcification

→ Metastatic calcification

Department of General Pathology
Sri Venkateswara Dental College & Hospital

Dystrophic calcification :- characterised by deposition of Ca^{2+} salts in dead or degenerated tissues with normal calcium metabolism & normal Serum Ca^{2+} level.

Metastatic calcification : Occurs in normal tissues & deranged Ca^{2+} metabolism.

Dystrophic calcification

- Calcification in dead tissues
  - → liquefaction necrosis
  - Caseous necrosis.
  - Fat necrosis.
  - → Infarks
- Calcification in degenerated tissues
  - dense old scars
  - Atheromas

III.

1) Vascular changes in Acute Inflammation
   - → Transient constriction
   - → Persistent progressive vasodilation.
     - → ↑ Local hydrostatic pressure
     - → Stasis of blood.

2) Fatty change liver.

causes: Starvation.
Alcoholic liver disease
Obesity
Diabetes mellitus.
Protein calories malnutrition

4) PAthologic Atrophy - starvation atrophy.
Ischaemic atrophy.
disuse atrophy
eg: Myopathies
Neuropathic atrophy
eg: poliomyelitis.

Physiological Atrophy - Atrophy of thymus in adult life.
Atrophy of brain with ageing.

5) 2 oxygen free radicals - Anion radical (O_2^-)
hydroxyl radical

Anti oxidants - Vitamin C
beta carotene.
Carotenoids
Vitamin E.

GENERAL PATHOLOGY

Kiruba sahari

Department of General Pathology
Sri Venkateswara Dental College & Hospital
Chennai- 603 103

22/35

① Inflammation:

Inflammation is defined as the local response of living mamalian tissue to anyway from any agent. It is the body's defense reaction in order to eliminate or limit the spread of injury or agent.

Cellular events:

Cellular phase of inflammation consists of 2 processes.

1. Enucleation of leucocytes
2. Phagocytosis.

1. Enucleation of Leucocytes

The escape of leucocytes from the lumen of microvasculature to the interstial tissue in the most important feature of inflammation.

i) Changes in the formed elements of blood:

In the early stage of inflammation, the rate of flow of blood is increased due to vasodilation, But subsequently there is showing or stages of blood stream.

With stasis, changes in the normal axial flow of blood in the microcirculation takes place.

ii) Rolling and Adhesion:

Peripherally marginated and pavemented neutrophils slowly roll over the endothelial cells living the vessel wall.

2, Selectins:

These are group of CAM's expressed on the cells and are structurally composed of lectins or lection like Protein molecules the most important of which is 3 liver x molecules.

P- selection
E- selection
L- selection.

Integrins

These are a family of endothelial cell surface Proteins having alpha and beta, subunits, which are activated during the process of loose and transient adhesions b/w endothelial cells and leucocytes.

Immunoglobulins gene Superfamily adhesion molecules.

Intercellular adhesion molecular-1 also called CD54 and vascular cell adhesion molecules called CD106.

Platelet endothelial cell adhesion molecule 1. or CD31 is involved in leucocyte migration from endothelial surface.

mated
lls.

ample of granuloma

Bacterial:
- Tuberculosis
- Syphilis
- granuloma
- Brucellosis

Fungal:
- Actinomycosis
- Blastomycosis

Parasite:
- Chistosomiosis

2. Apoptosis

It is a form of co-ordinated and automated programmed cell death having significance in a variety of physiologic and pathologic condition.

Pathologic changes:

1. cell death in tumours, exposed to chemotherapeutic agents.
2. cell death by cytotoxic and cells in immune mechanism such as in graft versus host disease and rejection reaction.
3. Progressive depletion of CD_4^+ cell in the Pathogenesis of AIDs
4. cell death in viral injection
5. Heart disease eg: in acute MI.
6. In degenerative disease of CNS.

Phagocytosis:

It is defined as the process of engulfment of solid particulate material by the cells these cells performing this function are called phagocytosis

Short Notes

1) granuloma:

It has following composition

i) epithelial cells:

They are modified Macrophages which are somewhat elongated cell having slipper shaped nucleus.

ii) Multinucleated giant cells

They are formed by fusion of adjacent epithelial cells & may have 20 (or) more nuclei. These nuclei may be arranged at the periphery.

iii) lymphoid cells:

As a cell mediated immune reaction to antigen, the host response by lymphocyte is integrated to composition of granuloma

iv) Necrosis

v) Fibrosis

3. Pathologic calcification

Professor & Head
Department of General ...
Sri Venkateswara Dental College ...
Chennai ...

Definition

Abnormal deposits of calcium salts occur in any tissues except bones and teeth.

Dystrophic calcification

Characterised by deposition of calcium salts in dead or degenerated tissue with normal calcium metabolism.

Morphological features

Etiology & pathogenesis of two are different

H and E stained sections

calcium salts appear as deeply basophilic irregular

Calcium deposits can be confirmed by specific stains.

Silver impregnation

Alizarin reds.

Metastatic calcification

can occur in normal tissue whenever there is hypercalcium.

Main cause of hypercalcemia.

i) Increase secretion of parathyroid hormone.

ii) Destruction of bone due to effect of accelerated turn over.

iii) vit. D related disorders.

iv) Renal failure.

IV. Short Answers

1) Vascular changes in Acute inflammation

Microvasculature is the earliest response to tissue injury.

Haemodynamic changes

- Transient vasoconstriction
- Persistent progressive vasodilation
- Hydrostatic pressure.
- Slowing.
- Leucocyte margination.

Triple response



2. Two causes for fatty change

- Drinking too much alcohol.
- Obesity
- Type 1 diabetes
- Metabolic syndrome.
- Insulin existance.

Department of General ...
Sri Venkateswara Dental College ...

3. Diff b/w Transudate / exudate :

Transudate	Exudate
Usually seen in congestive states	seen in inflammatory ratio.
Increased Hp	Increased vascular Permeability.
Sp gr : < 1.020	Sp g : > 1.020.
Proteins : < 2 gm/dl	> 2 gm/dl.

(5) Two oxygen free radical

- Superoxide anion radical
- Singlet oxygen

Two antioxidants

- selenium
- Carbonides

GENERAL PATHOLOGY

A. MANISH
SELVANAYAGAM

23/35

① INFLAMMATION

It is defined as the local response of living mamalian tissue to anyway from my agent. It is the Bodys defense reaction in order to eliminate.

Cellular events:-

Cellular phase of inflamation consists of 2 process.

1. Emulation of leucocytes
2. phagocytosis.

Emulation of leucocytes:-

The escape of leucocytes from the human of microvasculature to the intestial tissue is the most important feature of inflammation.

(1) Changes in the formed elements of Blood:-

In the early stage of inflammation, the rate of flow of Blood is inreased due to vasodilation, But subsequently there is slowing of stage of Blood stream.

With stasis, changes in the normal axial. Inte

flow of Blood in the microcirculation takes place.

(ii) Rolling and Adhesion:-

Peripherally marginated and pavemented neutrophils slowly roll over the endothelial cells lining the vessel wall.

2- SELECTINS:-

These are group of CAM's expressed on the cells and are structurally composed of lectins or electrion like protein molecules the most important of which is S-lines & molecules.

P- Selection

E- Selection

L- Selectin.

INTEGRINS:-

These are a family of endothelial cell surface proteins having alpha & bet a subunit.

Intercellular adhesion molecules + Leucocyte Cell

CD 54 + Vascular Cell Adhesion molecules

Platelet endothelial cell Adhesion molecule I

+ CD 3, is involved in leucocyte migration from endothelial surface

Phagocytosis :-

It is defined as the process of enlargement of solid particulate material by the cell these cell performing this function are called phagocytosis.

SHORT NOTES :-

1) GRANULOMA :-

It has the following composition :-

(i) Epithelial Cells.

(ii) Multinucleated giant Cell

(iii) Lymphoid Cell.

(iv) Necrosis

(v) Fibrosis

Example of granuloma :-

Bacterial :-

Tuberculosis

Syphilis

Granuloma

Brucellosis

Fungal :-

Actinomycosis

Blastomycosis.

Parasite :-

Chistosomosis.

2. Apoptosis :-

It is a form of co-ordinated & automated programmed cell death having significance in a variety of physiologic & pathologic conditions.

Pathological changes :-

1. Cell death in tumours, exposed to chemotherapeutic agents.
2. progression depletion of CD4+ cell in pathogenesis of AIDS
3. Cell death in viral infection
4. Agent disease eg :- In Acute MI
5. The degenerative dis of CNS.

1) Vascular changes in Acute inflammation :-

Microvasculature is the earliest response to tissue injury.

Haemodynamic changes :-

Transient vasoconstriction.

Persistent progressive Vasodilation

Hydrostatic pressure

Slowing

Leucocyte margination.

Triple respons :-

2. Two causes for fatty change :-

Drinking too much Alcohol

obesity

Type I diabetes

Metabolic syndrome

Insulin resistance

3. pathologic

3. Diff. b/w Transudate / Exudate :-

TRANSUDATE	EXODATE
* Usually seen in congestive status.	* Seen in inflammatory ratio
* Inward Hp	* Inward vascular permeability.
* Sp. Gravity : < 1.020	* Sp g : > 1.020
* proteins : < 2gm/dl	* > 2gm/dl

5. Two Oxygen free radical

* Superoxide anion radical
* Singlet Oxygen

Two Antioxidant :-

Selenium

Carbonides

3. pathological classification

PROFESSOR & HOD
Department of General Pathology
Sri Venkateswara Dental College
Chennai- 603 103

Definition:-

Abnormal deposit of Calcium Salts occurs in any tissues except Bones & teeth.

Dystrophic Calcification:

Characterised by deposition of Calcium salts in dead or degenerated tissue with normal calcium metabolism.

Morphological feature:-

Etiology & pathogenesis of 2 are different H and E stained section.

Calcium Salt appears as deeply Basophilic irregular. Calcium deposits can be confirmed by specific stains.

Metastatic Calcification:-

Can occur in normal tissue whereas there is hypercalcium.

Cause of Hypercalcemia:-

↑se secretion of parathyroid hormone.

Vit D related disorder

Renal failure.

PROFESSOR & HOD
Department of General Pathology,
Sri Venkateswara Dental College & Hospital
Chennai-602 105

25

Nabila Barwin

ESSAY:-

1) Inflammation:-

Inflammation is defined as local response of living mammalian tissues to injury due to any agent.

It is a body defense reaction in order to eliminate or limit the spread of injurious agents followed by removal of necrosed cells and tissues.

the cellular phase of acute inflammation are,

① Exudation of leukocytes
② Phagocytosis.

① Exudation of leukocytes:-

a) Changes in formed elements of blood:-

In early stage of inflammation, the rate of flow of blood is increased due to vasodilation.

there is slowing or stasis of bloodstream.

With stasis, changes in normal axial flow of blood in the microcirculation takes place.

the central stream of cells widens and peripheral plasma zone becomes narrower because of loss of plasma by exudation

this phenomenon is known as margination.

② Rolling and adhesion :-

Peripherally margination and pavemented neutrophils slowly roll over the endothelial cells lining the vessel wall (Rolling phase).

Adhesion phase ⟶ this is followed by transient bond between the leukocytes and endothelial cells becomes firmer.

. the following molecules bring about rolling and adhesion phases

a) Selectins
b) Integrin
c) Immunoglobin gene superfamily adhesion molecule (ICAM-1),

③ Emigration :-

After sticking of neutrophils to endothelium the former move along the endothelial surface till the suitable site between endothelial cells is found when the neutrophils throw out cytoplasmic pseudopods

Subsequently, the neutrophils lodged between the endothelial cells and basement membrane cross the basement membrane by damaging it locally with secreted collagenases.

then escapes out into the extravascular space, this is known as emigration.

Phagocytosis

(1) Recognition & attachment
(2) engulfment
(3) killing and degration.

a) Intracellular mechanisms
b) Extracellular mechanism.

2) Phagocytosis :-

It is defined as process of engulfment of solid particulate material by the cells.

the cells performing the functionais phagocytes.

these are 2 types of phagocytic cells.

(1) PMN's
(2) Circulating Monocytes.

Neutrophils and macrophages on reaching the tissues space produce several proteolytic enzymes.

lyzozyme, protease, collagenase, elastase, Lipase, proteinase, gelatinase and acid hydrolases.

the enzymes degrades collagen and extracellular matrix.

the microbes undergoes the process of phagocytosis and involving the following 3 steps.

(1) Recognition & Attachment
(2) Engulfment
(3) killing and degration

① Recognition & Attachment.

Phagocytosis is initiated by expression of surface receptors on macrophages which recognize micro-organisms,

Mannose receptor
Scavanger receptor.

the process of phagocytosis is further enhanced when the micro organisms are coated with specific proteins, Opsonins from the serum or they gets opsonized. the main opsonins present in the serum and their corresponding receptors on the surface of phagocytic cells.

② engulfment

the opsonised particle bound to the surface of phagocyte is ready to be engulfed. the phagosome fuses with one or more lysosomes of the cells & form bigger vacuole called phagolysosome.

③ killing and degradation

Next comes the stage of killing and degradation of micro organism to dispose it off justifying the function of phagocytes as scavenger cells.

disposal of micro organisms can proceed by following mechanism.

a) Intracellular mechanism.
b) extracellular mechanisms.

PROFESSOR & HOD
Department of General Pathology
Vaikaneswara Dental College
Chennai 603 102

SHORT NOTES:-

① Granuloma:-

It is defined as circumscribed, tiny lesion, about 7 mm in diameter, composed predominantly of collection of modified macrophages called epithiloid cells.

Pathogenesis:

formation of granuloma is a type IV granulomatous hypersensitivity reaction.

the sequence in evolution of granuloma,

Cell injury
↓
Failure to digest agent
↓
Weak acute inflammation response
↓
Engulfment by macrophages
↓
Persistence of injurious agent

↙ T cell mediated immune response

↘ Poorly digested agent.

↘ Activation of CD 4 T cells

Monocyte Chemotactic factor
↓
Accumulation of tissue Macrophages.

Increased recruitment from circulation
Local proliferation
Monocyte, proliferation of T cells

Macrophage activated by IFN-γ

↓ transformation to epithelioid cell giant cells

Secretion of fibroblastic proliferating agents

↓

Granuloma

(2) Atrophy:

Reduction of the number and size of parenchymal cells of organ or its parts which was once normal is called atrophy.

Causes

a) physiologic atrophy due to endocrine stimulation or arterios clerosis

i) Atrophy of lymphoid tissues
ii) Atrophy of gonads after menopause
iii) Atrophy of brain with ageing.

PROFESSOR & HOD
Department of General Pathology
Sri Venkateswara Dental College & Hospital
Chennai - 603 103

ii) Pathological atrophy:

a) Starvation atrophy

b) Ischaemic atrophy.

gradual diminution of blood supply.

c) Disuse atrophy.

a) Wasting of muscle of limb -

d) Neuropathic atrophy.

Interruption in nerve supply leads to wasting of muscle

a) Poliomyelitis.

b) Motor neuron disease

c) Nerve section

e) Endocrine atrophy.

Loss of endocrine regulatory mechanisms results in reduced metabolic activity.

i) hypopituitarism

ii) hypothyroidism.

f) Pressure atrophy

Prolonged pressure from benign tumors or cyst or aneurysm may cause compression.

i) erosion of spine by tumor in nerve root.

g) Idiopathic atrophy

a) Myopathies.

b) Testicular atrophy

③ Pathologic Calcification

Deposition of Calcium salts in tissues other than osteoid or enamel is called heterotopic calcification.

① dystropic calcification:

This is characterized by deposition of calcium salts in dead or degenerated tissues.

Normal calcium metabolism and normal serum Calcium levels.

→ Calcification in dead tissues.
→ calcification in degenerated tissues.
Generally irreversible.

Causes

Necrosis, cyst, tumour.
Infarct, atheromas.
Thrombi, Old scar.
dead parasite.

② Metastatic calcification:

deposits of calcium salts in normal tissues.
Calcium metabolism → deranged
hypercalcaemia.
Reversible upon correction of metabolic disorder.

Causes

Hyperparathyroidism.
Prolonged immobilization.
Hypercalcaemia of infarct.

Department of General Pathology
Sri Venkateswara Dental College
Chennai - 603 103

SHORT NOTES:

1) Vascular events of Acute inflammation:
   a) Transient vasoconstriction
   b) Persistent progressive vasodilatation.
   c) elevation of local hydrostatic pressure
   d) slowing or stasis of microcirculation
   e) Leucocyte margination.

2) Causes of Fatty change liver:
   (1) Conditions with excess fat
      (hyperlipidemia)

   (2) Liver cell damage
   a) condition with excess fat
      Obesity
      Diabetes
      Congenital hyperlipidemia
   b) Liver cell damage
      Starvation
      Alcoholic liver disease
      Chronic illnesses
      hypoxia
      hepatotoxins.

③ diff. between Transudate & Exudate.

Transudate	exudate
filtrate of blood plasma without change in endothelial permeability.	Oedema of inflamed tissue ass. with increased vascular permeability.
Non-inflammatory Oedema	Inflammatory Oedema.
LDL is low	LDL - High.
pH ≥ 7.3	pH < 7.3.
Only few cells involved (ex) Mesothelial cells	Many cells involved (ex) parenchyma.

④ Physiologic atrophy
(ex) Atrophy of brain with ageing
Atrophy of lymphoid tissue.

Pathologic atrophy
(ex) Neuropathic atrophy
Poliomyelitis.
endocrine atrophy
hypopituitarism.

⑤ Anti-oxidants
Serum proteins.
(ex) Transferrin
Vitamins E, A, C.

Oxygen free Radicals
Nitric oxide.
Halide reagent
(chloride / chlorine)

Pharmacology

Answer Papers

PROFESSOR & HOD
Department of Pharmacology
Sri Venkateswara Dental College & Hosp
Chennai-600 130.

PHARMACOLOGY

20/20

Siva Priyadharshan. V.P

1) Routes of drug Administration:

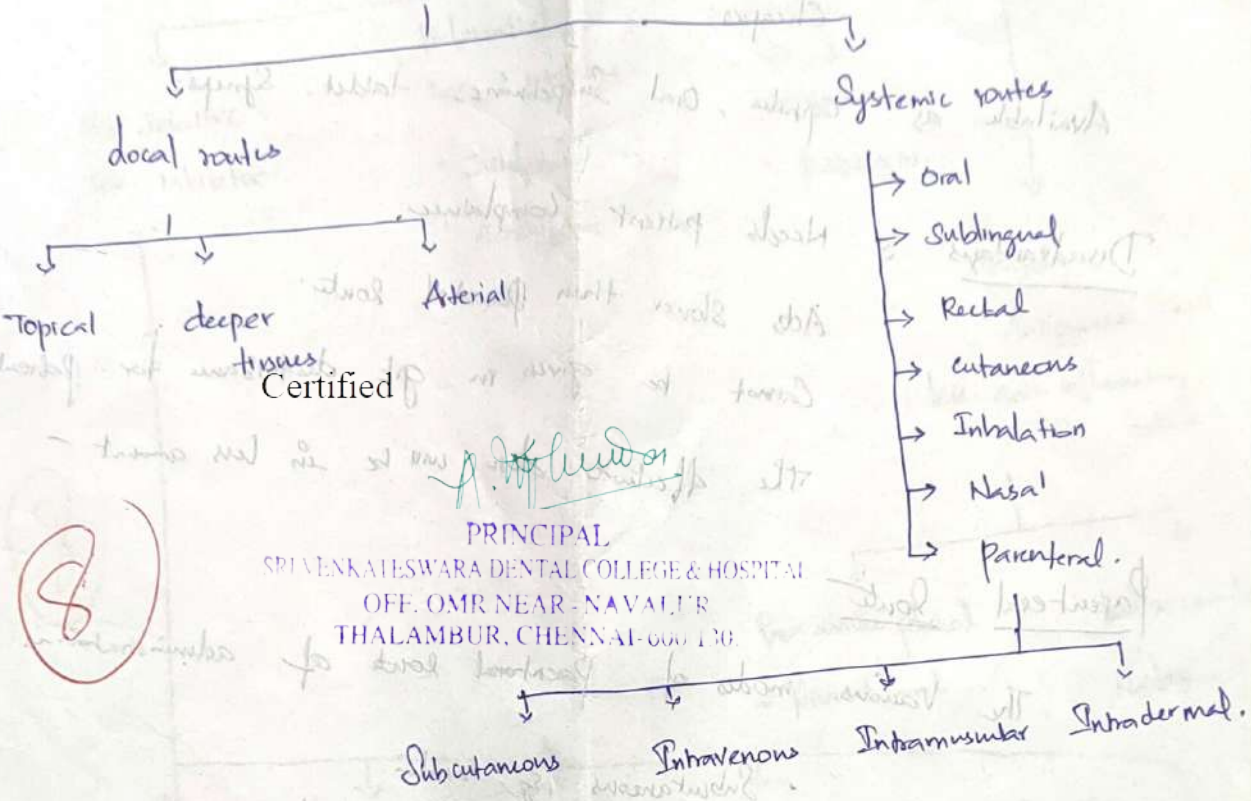

Certified

PRINCIPAL
SRI VENKATESWARA DENTAL COLLEGE & HOSPITAL
OFF. OMR NEAR - NAVALUR
THALAMBUR, CHENNAI-600 130.

8

Local Routes

Topical: It is the external application of the drug

Mucosal topical application is done in case of Candidiasis

Eg: steroid application, Neomycin.

Sublingual: Nitroglycerine - 0.5mg is given in the myocardial infarction as the fastest relieving factor.

Arterial Supply: Close intra-arterial injection of dye is used.

Eg: Angiography.

Systemic Route:

Oral Route: It is the commonest mode of administration.

Certified

Advantages: Safer

Non-invasive

Painless

Suf. administrated

Cheapest.

PRINCIPAL
SRI VENKATESWARA DENTAL COLLEGE & HOSPITAL
OFF. OMR NEAR - NAVALUR
THALAMBUR, CHENNAI-600 130.

Available as Capsules, Oral Suspensions, tablet, Syrups.

Disadvantages: Needs patient compliance

Acts slower than Parental route.

Cannot be given in GIT disturbance for patients.

The effective dose will be in less amount.

Parenteral Route

The various modes of Parentral route of administration is

- Subcutaneous Eg: Insulin
- Intravenous Eg: Iv of Paracetamol
- Intramuscular Eg: Vaccine
- Intra dermal. Eg: Kevin's test for Tuberculosis.

Adv: The effective of drug is 100%.

Fastest route of administration

Disadv: Painful

Can be used in needlephobia.

Not self administration

Inhalation: It is the inhalation of gaseous form of drug.

Eg: Salbutamol - Bronchial Asthma.

↓

Fastest Way.

PROFESSOR & HOD
Department of Pharmacology
Sri Venkateswara Dental College & Hospital
Chennai-600 130.

Certified

PRINCIPAL
SRI VENKATESWARA DENTAL COLLEGE & HOSPITAL
OFF. OMR NEAR - NAVALUR
THALAMBUR, CHENNAI-600 130.

3) NSAIDS

- Non-Selective Cox-inhibitor
  - Salicylates
    - Aspirin
  - Propionic acid
    - Ibuprofen
  - Fenamate
    - Mefenamic acid
  - Acetic acid
    - Ketorolac
  - Enolic acid
    - Piroxicam
  - Pyrazolone
- Preferential Cox-2 inhibitors
  - Diclofenac
  - Aceclofenac
- Selective Cox-2 Inhibitors
  - Parecoxib

Analgesic - Antipyretic with less anti-inflammatory action

- Para amino phenol
  - Paracetamol
- Benzodiazepine
  - Alprazolam

8

Analgesics

Opioids / Narcotics
Eg: Morphine.

NSAIDS
(Non-Steroidal - Anti inflammatory drugs).

Mechanism of action :-

Membrane lipids

↓ Phospholipase A_2

Arachidonic Acid

↓ Cyclooxygenase 1 / Cyclooxygenase 2

Naisels ← X

Prostoglandin h_2

↓

Prostoglandin H, D, E & thromboxane.

NSAIDS inhibits the secretion of prostagladins.

It reduces inflammation of pain.

Thus Action of Aspirin

Uses

Analgesics

Anti-pyretics → ↓ temperature

Used in treatment of acute chemotherapy

Post stroke & post myocardial infarction

Uses in Anti platelet aggregation.

Disadvantages

→ peptic ulcers
→ Aggravates gastritis
→ Hypersensitivity.
→ Reyes Syndrome.
→ Acute Salicylate poisoning.
Vertigo, dizziness.

PROFESSOR &
Department of Pharmacology
Sri Venkateswara Dental College & Hosp
Chennai-600 130.

2). Absorption

It is movement of drug from its site of administration ~~of~~ into circulation.

Factors affecting

→ Aqueous solubility.
→ route of administration
→ vascularity of absorbing surface
→ Area of absorbing surface

Distribution:

once drugs enters into bloodstream it get distribute to other tissue. That initially ~~has~~ has on drug. Can't gradient being is direct of drug depend on.

→ Lipid Solubility.
→ Extend of binding to plasma & tissues.

Biotransformation: It means chemical alteration of drug in body. So, they are reabsorped in renal tubulous & enter

Certified

PRINCIPAL
SRI VENKATESWARA DENTAL COLLEGE & HOSPITAL
OFF. OMR NEAR - NAVALUR
THALAMBUR, CHENNAI-600 130.

pharmacology.

PROFESSOR & HOD
Department of Pharmacology
Sri Venkateswara Dental College & Hospital
Chennai-600 130.

29/30

HEMA. S.M
II - BDS

I.

1. Describe various routes of drug administration

Routes can be broadly divided into two types

Local route
- a) Topical
- b) Deeper tissues
- c) Arterial supply.

Systemic route
- a) oral route
- b) Sublingual or buccal.
- c) Rectal
- d) cutaneous
- e) Inhalation
- f) Nasal
- g) Parenteral
  - 1) Subcutaneous
  - 2) Intramuscular
  - 3) Intravenous
  - 4) Intradermal

Certified

PRINCIPAL
SRI VENKATESWARA DENTAL COLLEGE & HOSPITAL
OFF. OMR NEAR - NAVALUR
THALAMBUR, CHENNAI-600 130

Oral drug administration

Oral ingestion is the oldest and commonest mode of drug administration.

advantages

1) safer.
2) more convenient
3) Does not need assistance
4) Non invasive.
5) painless.
6) cheaper.

Limitations

1) Actions are slower and thus not suitable for emergencies.
2) Unpalatable drugs are difficult to administer
3) May cause nausea and vomiting.
4) Cannot be used for uncooperative, unconscious or vomiting patient.
5) Absorption of some drug is erratic (streptomycin).
6) Others are destroyed by digestive juices or in liver by high first pass metabolism.

Certified

PRINCIPAL
SRI VENKATESWARA DENTAL COLLEGE & HOSPITAL
OFF. OMR NEAR - NAVALUR
THALAMBUR, CHENNAI-600 130

PROFESSOR & HOD
Department of Pharmacology
Sri Venkateswara Dental College & Hospital
Chennai-600 130.

Intramuscular

1) The drug is injected in one of the large skeletal muscles. eg. deltoid, triceps, gluteus maximus, rectus femoris.

2) Muscle is less richly supplied with sensory nerves and more vascular.

3). It is less painfull, but self-injection is often impractical, because deep penetration is needed.

4) Depot preparations can be injected by this route.

5) Intramuscular injections should be avoided in patients taking anticoagulant medication.

Intravenous:

1). The drug is injected as a bolus or infused slowly over hours in one of the superficial veins.

2). The drug directly reaches into the bloodstream and effects are produced immediately.

3). This is the most risky route where vital organs like heart & brain can get exposed to high concentration of drug.

2). Explain absorption, distribution, biotransformation and excretion of drugs.

Absorption

Absorption is the movement of the drug from the site of administration into the circulation.

Factors affecting absorption:

a) Dissolution.
b) Disintegration
c) particle size.
d) Formulation
e) Lipid solubility.
f) Area.
g) Metabolism.
h) Vascularity.
i) Presence of other drugs.
j) GI motility.
k). Diseases.

PROFESSOR & HOD
Department of Pharmacology
Sri Venkateswara Dental College & Hospital
Chennai-600 130.

First pass metabolism:-

⇒ It is the metabolism of a drug during its first passage through gut wall and liver.

⇒ It reduces bioavailability.

⇒ The extent of the metabolism depends on the drug and the individuals.

Bioavailability:-

⇒ Bioavailability is the fraction of the drug that reaches the systemic circulation following administration by any route.

⇒ Thus for a drug that is given intravenously, the bioavailability is 100 percent.

Bioequivalance:

Comparison of bioavailabity of different formulations ~~containing~~ ~~the same~~ of the same drug is the study of bioequivalance.

Distribution:

Once a drug has gained access to the bloodstream, it gets distributed to other tissues that initially had no drug, concentration gradient being in the direction of plasma to tissues.

The extent of distribution of a drug depends on ;

a) Lipid solubility.
b) Ionization at physiological pH.
c) extent of binding to plasma and tissue proteins.
d) differences in regional blood flow.

$$\text{Apparent volume of distribution (V)} = \frac{\text{Dose administered I.V}}{\text{plasma concentration}}$$

Biotransformation :- (Metabolism).

It is the process of biochemical alteration of the drug in the body.

Site : Primary site for drug metabolism is liver. Others are, kidney, intestine, lungs & plasma.

PROFESSOR & HOD
Department of Pharmacology
Sri Venkateswara Dental College & Hospital
Chennai-600130

Biotransformation of drugs may lead to the following,

a) Inactivation.
b) Active metabolite from an active drug.
c) Activation of inactive drug.

Excretion of drugs :-

Excretion is the passage out of systemically absorbed drug.

Drug and their metabolites are excreted in,

a) Urine.
b) Faeces.
c) Exhaled air.
d) Saliva and sweat.
e) Milk.

Renal excretion :

The kidney is responsible for excreting all water-soluble substances.

The amount of unaltered drug or its metabolites ultimately present in urine is sum of total of glomerular filtration, tubular reabsorption and tubular secretion.

Net renal excretion = (glomerular filtration + tubular secretion) − tubular reabsorption.

3). Classify Analgesics.

Non-steroidal anti-inflammatory drugs

- Non selective COX inhibitors
  - 1) Salicylates
    - Aspirin.
  - 2) propionic acid derivatives
    - Ibuprofen
    - Naproxen.
  - 3) Fenamate
    - → Mephenamic acid
  - 4) Enolic acid derivatives.
    - Piroxicam
- Preferential COX-2 inhibitors
  - → Nimesulide.
  - → Diclofenac
  - → Aceclofenac
  - → Nabumetone.
  - → Etodolac.
- Selective COX2 inhibitors
  - → Celecoxib
  - → Etoricoxib.
  - → Parecoxib.

Analgesic - antipyretics with poor anti-inflammatory action.

- Para aminophenol derivative
  - ↓
  - Paracetamol
- Benzoxazocine derivative
  - ↓
  - Nefopam.

PROFESSOR & HOD
Department of Pharmacology
Sri Venkateswara Dental College & Hosp.
Chennai-600 130.

Aspirin:

-) Aspirin is acetyl salicylic acid.

=) It is rapidly converted in the body to salicylic acid which is responsible for most of the actions.

Pharmacological actions:

a) Analgesia.

b) Antipyretic action.

c) Anti-Inflammatory action.

d) Respiration.

e) Acid base and electrolyte balance.

f) Metabolic effects.

g) Gastrointestinal tract.

h) Uric acid

i) Local effects.

Adverse effects:

a) Nausea.

b) Vomiting.

c) Epigastric distress.

d) peptic ulcer.

e) Allergic reactions.

f) Rashes, Rhinorrhoea, asthma

g) Nephrotoxicity.

h) Hepatotoxicity.

i) Reye's syndrome.

Indications:

a) As analgesic.

b) Fever.

c) Acute rheumatic fever.

d) Osteoarthritis.

e) Rheumatoid arthritis.

f) Post myocardial infarction.

PROFESSOR & HOD
Department of Pharmacology
Sri Venkateswara Dental College & Hospital
Chennai-600 130

25/30

S. Aravind Kumar

J. Venkatadri

essay

1. Various routes of drug administration:

Routes can be broadly divided into those for a) local action
b) systemic action.

Local routes

1. Topical.

Refers to external Application of the drug to the surface for localized action. it is more convenient and efficient mode of delivering the drug to tissue.

2. Deep tissues

Certain deep tissues can be approached by using a syringe and Needle.

3. Arterial supply

Closed intra-arterial injection is used for contrast Media in angiography.

Systemic routes

1) Oral.

Oral injection is the oldest and commonest mode of drug administration.

Safe

painless.

2. Sublingual

The tablet or pellet containing the drug is placed under the tongue or placed in the mouth and spread over buccal mucosa.

3) Rectal

Certain irritant and unpleasant drug can be put into the rectum as suppositories or retention enema for systemic effect.

4) Cutaneous

Highly lipid soluble drugs can be applied over the skin for slow and prolonged absorption.

5. Inhalation

Volatile liquids and gases are given by inhalation for systemic action

6) Nasal

The mucous membrane of the nose can speedily absorb many drugs.

4. parenteral

refers to administration by injection which takes the drug directly into the tissue fluid

2) Advantage and disadvantage of oral intravenous and intramuscular route.

Advantage

- Easily taken
- painless
- effective

disadvantage

- works slowly
-

PROFESSOR & HOD
Department of Pharmacology
Sri Venkateswara Dental College & Hospital

Advantage

- works effectively.
- Easily given

Intramuscular

the drug is injected in one of the large skeletal muscles deltoid, triceps, rectus ~~demon~~ femoris etc.

muscle is less richly supplied with sensory nerves and is more vascular. it is painful, but self injection is often unpracticable.

Intravenous

Drug is injected as a bolus or infused slowly over hours in one of the superficial veins.

the drug directly reaches unto the bloodstream and effect are produced immediately.

the intima of veins is insensitive and drug gets diluted with blood, therefore even highly irritant drugs can be hazards are thrombophebitis of the injected vein and Necrosis of

Adjoining tissues if extravasation occurs these complications can be minimized by diluting the drug or injected it into a running iv line.

2) Explain

A) Absorption

Absorption is the movement of drug from its site of administration into the circulation.

not only the fraction of the administered does that gets absorbed, but also the rate of absorption is important

1. Aqueous solubility
2. Concentration
3. Area of Absorbing surface
4. Vascularity of the absorbing surface
5. Route of Administration

B) distribution

Once the drug has gained access to the bloodstream, it gets distributed to other tissues that initially had no drug

concentration gradient being in the direction of plasma to tissues.

2 $V = \frac{\text{Dose administered IV}}{\text{plasma concentration}}$

3 Biotransformation

Means chemical alteration of the drug in the body.

Most hydrophilic drugs, eg:
gentamicin
Neostigmine

1) Inactivation

most drugs and their active metabolites are inactivated inactive or less active

Excretion

Excretion is the passage out of systemically absorbed drug

1) Urine
2) faeces
3) Exhaled air
4) Saliva and sweat.
5) Milk.

PROFESSOR & HOD
Department of Pharmacology
Sri Venkateswara Dental College & Hospital
Chennai-600 ...

3) classify Analgesics

- Non selective Cox inhibitors
  - Salicylates
    - Aspirin
  - Propionic acid
    - Ibuprofen
    - Naproxen
  - Fenamate
    - Mephenamic acid
  - Enolic Acid
    - piroxicam
  - Acetic Acid
    - Ketoolac
- preferential Cox_2 inhibitors
  - Nimesulid
  - Aceclofenac
  - Etodolac
- selective Cox_2 inhibitors
  - Celecoxib
  - Etoricoxib
  - Parecoxib
- Analgesic Antipyretics
  - Para aminophenol derivative
    - Paracetamol
  - Benzo Xazocine
    - Nefopam

8

Aspirin

*) Acetyl salicylic Acid.

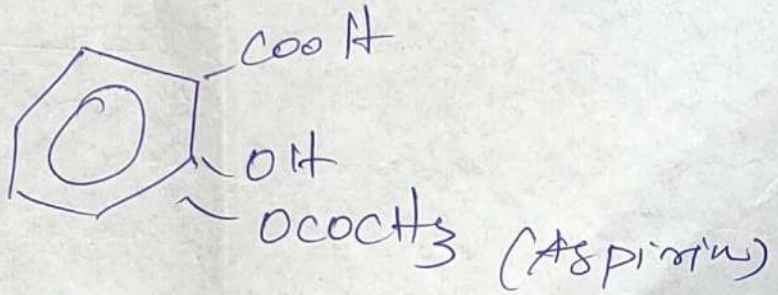

User

1. As Analgesic
2. As Antipyretic
3. Acute rheumatic fever
4. Rheumatoid arthritis
5. Osteoarthritis
6. Post myocardial infarction

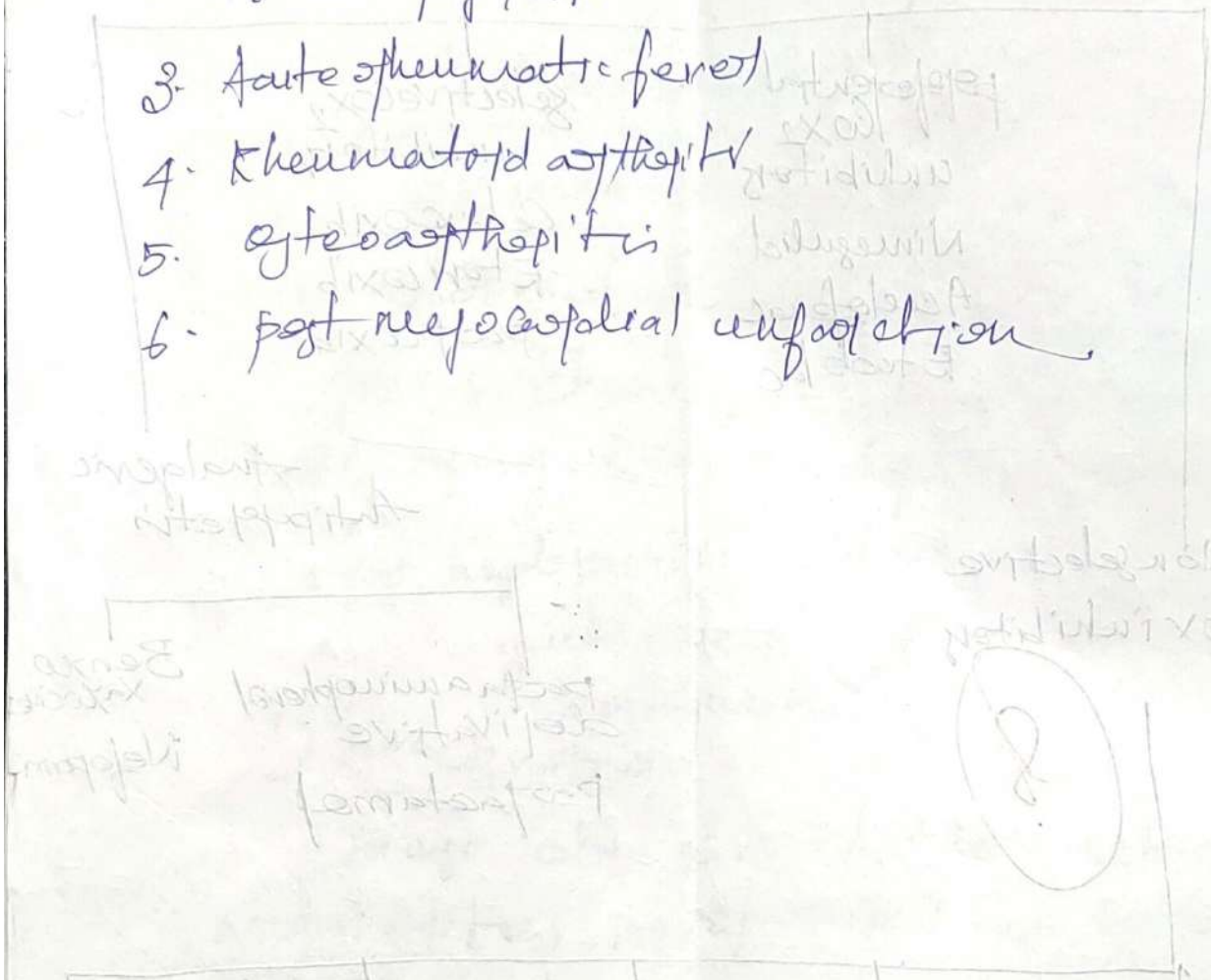

PHARMACOLOGY

PROFESSOR & HOD
Department of Pharmacology
Sri Venkateswara Dental College & Hospital
Chennai-600 130

AKSHAY PAKKI.
II year.

28/30

① Various routes of drug administration :-

Types of drug administration

(i) Local Route
- Topical tissues
- Rectal Tissues
- Arterial supply

(ii) Systemic Route
- Oral
- Sub lingual
- Rectal
- Cutaneous
- Inhalation
- Parential

8

Local Route :

(i) Topical tissues :-
External application of the drug to the surface for the localized action.

(ii) Deep tissues :-
Deep areas can be approached.

(iii) Arterial supply :-
Intra arterial injection for contrast media.

Systemic Routes:

(i) Oral:
Safer given orally

(ii) Sublingual:
Tablet/Pellet is placed under the tongue

(iii) Rectal:
- Irritant & unpleasant
- Given in Children

(iv) Cutaneous:
Highly lipid - soluble drugs can be applied over the skin for slow.

(v) Inhalation:
Volatile liquids & gases

(vi) Nasal:
Mucous membrane of the nose can readily.

(vii) Parenteral:
Administration by injection which takes the drug

Oral:

Advantages:
- Safer
- Easy to take
- Fast absorption
- Painless

Disadvantages:
- Slower action

PROFESSOR & HOD
Department of Pharmacology
Sri Venkateswara Dental College & Hospital
Chennai-600 130.

* Nausea & vomiting.
* Cannot be used for unconscious
* Cannot be used in certain people.

Intra muscular:-

Adv:- * Faster absorption
* Mild irritants can be injected.
* Less Painful than IV

Disadvantages:

* Painful ~~than IV~~
* Cannot be given in anticoagulant taking patients.

Intra Venous:-

Adv:
* Highly irritant drugs can be injected
* Small dose is requiring
* Response is accurately measurable
* Short acting

Dis advantages:

* Painful
* Invasive
* Tearing
* Injected area haematoms.
* May lead to air embolism

(2)

(i) Absorption:

It is the movement of drug from its sit of administration into circulation.

Not only the fraction of dose administred get absorbed but also the rate of absorption is important.

Factors affecting:

- Aqueous solubility.
- Concentration.
- Area of absorbing surface
- Vascularity of absorbing surface
- Route of administration.

(ii) Distribution:

Once a drug has gained access to blood stream, it gets distributed to other tissue that initially has no drug

- Liquid Solubility
- Ionisation at Physiological pH.

→ Extent of binding to Plasma & tissue protein

→ Differences in Regional blood flow.

Apparent Volume of distribution (V)

$$V = \frac{\text{Dose administered I.V}}{\text{Plasma concentration}}$$

Factors Effecting :-

- Lipid Water position coefficient of drug
- PK value of drug
- Degree of Plasma protein.
- Fat : Lean Body mass Ratio.
- Disease like CHF, Diabetes.

(iii) Biotransformation :-

It means chemical alteration of the drug in the Body. It is needed to render polar compounds.

Primary site of drug metabolism is LIVER.

Biotransformation of drugs may lead to.

* Inactivation.
* Activation of inactive drug.

(iv) Excretion of drug:

It is the passage route of systemically absorbed drug.

* Drugs and their metabolites are excreted in → Urine - Through Kidney
  → Milk
  → Exhaled Air.
  → Faces
  → Saliva & sweat.
  → Biliary Excretion.

Nat. Renal Excretion :

(Glomerular filtration + Tubular Excretion)
- Tubular reabsorption.

PROFESSOR & HOD
Department of Pharmacology
Sri Venkateswara Dental College & Hospital
Chennai-600 130

(2)

NSAIDS

- Non selective COX Inhibitors.
- Preferential COX-2 Inhibitors
  - * Diclofenac
  - * Aceclofenac.
- Selective COX-2 Inhibitors.
  - * Celecoxib
- Analgesic - antipyretic with poor anti inflammatory action
  - Para aminophenol derivative
    - * Paracetamol
  - Benzocaine
    - * Nefopam
- (6)
  - Salicylates
    - * Aspirin
  - Propionic acid
    - * Ibuprofen
    - * Naproxen
  - Fenamate
    - * Mephenamic acid.
  - Enolic acid (oxicam)
    - Piroxicam
  - Acetic acid derivatives
    - Ketorolac
  - Pyrazolone derivatives
    - Phenylbutazone

Aspirin

- It is a analgesic, antipyretic & anti inflammatory

Adverse effects:

- Vomiting dehydration
- * Hypersensitivity.

* Acute Salicylate Poisoning.

Contra Indication :-

Peptic ulcer.

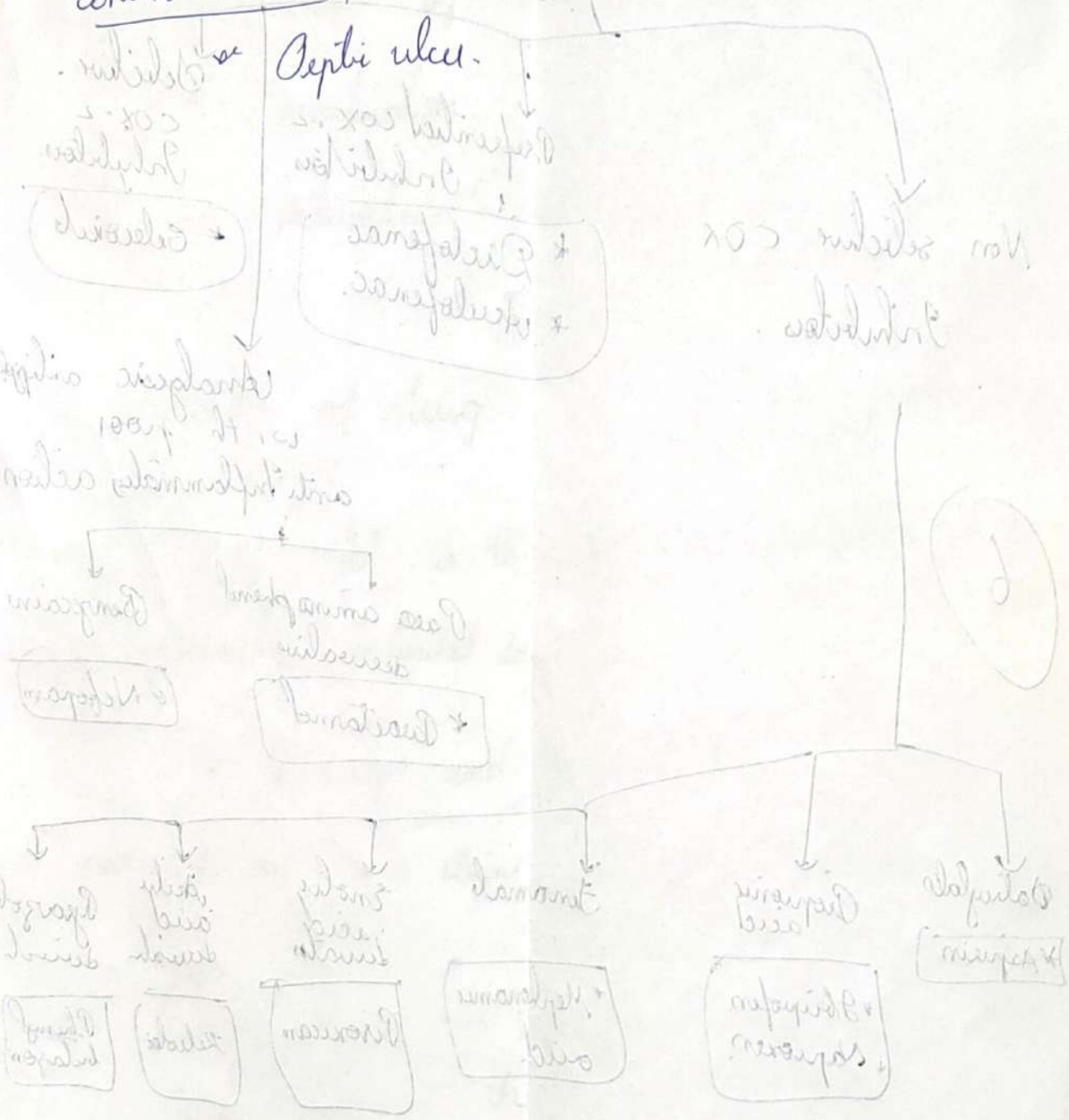

PHARMACOLOGY.

PROF. SELVANAYAGAM
A. MONISH, M.SC., M.PHIL.
Department of Pharmacology
Sri Venkateswara Dental College & Hospital
Chennai-600 130.

27/30

M. Venkatadri

ESSAY:-

1. ROUTE OF ADMINISTRATION:-

Local Route

* Topical
* Deeper tissue
* Arterial supply

Systemic Route.

* Oral
* Sublingual & Buccal
* Rectal
* Cutaneous
* Inhalation
* Nasal
* Parenteral.

LOCAL ROUTE:-

1. TOPICAL:-

External application of drug to surface for localized action.

Drug is desired to skin, nasal mucosa, vagina, buccal mucosa.

2. DEEPER TISSUE :-

Approached by Syringe

Eg :- 1. ~~Subcutaneous~~

Intramuscular.

2. Intraarticular

3. Retro bulbar injections.

3. ARTERIAL SUPPLY :-

Used for contrast media in Angiography.

SYSTEMIC ROUTE :-

1. ORAL

Oldest & most common.

Eg: Tablets, powder.

2. SUBLINGUAL / BUCCAL

. Tablet is placed under tongue

. Lipid soluble & non irritating drugs can be Administered.

PROFESSOR & HOD
Department of Pharmacology
Sri Venkateswara Dental College & Hospital
Chennai-600 130.

Advantages :-

1. ORAL

Adv :- Safe,
Non invasive
Painless
Convinient.

Dis :-
Action is slower
Not suitable for emergency.
Cause Nausea & Vomiting.

2. Intramuscular :-

Adv :- Absorption is faster
less painful than I.V
Mild irritant can be injected.

Dis :- Assistance needed for Administration
Painful
Invasive

Intravenous :-

Adv :- Highly irritant drug can be injected.
Drug dose is less
Immediate effect.

Dis :- Painful Invasive.

Eg:- Glyceryl Trinitrate

3. RECTAL

Inconvient & Embarassing

4. CUTANEOUS :-

Lipid drug on skin

Ointment

5. INHALATION :-

Volatile liquid and gases

Anesthesia are given by INHALATION.

6. NASAL :-

7. PARENTAL :-

2.

(i) ABSORPTION

It is the movement of drug from its site of administration into circulation.

Not only the fraction of dose administered gets absorbed but also the rate of absorption is important.

FACTORS AFFECTING :-

* Aqueous solubility
* Concentration
* Area of absorbing surface
* Vascularity of the absorbing surface
* Route of administration.

(ii) DISTRIBUTION :-

Once a drug has gained access to blood stream, it gets distributed to other tissue that initially has no drug, conc gradient being in direction of a drug depends on its

→ Liquid solubility

PROFESSOR & HOD
Department of Pharmacology
Sri Venkateswara Dental College & Hospital
Chennai 130.

→ Ionisation at physiological pH

→ Extent of binding to plasma & tissue protein.

→ Difference in Regional Blood flow

Apparent Volume of distribution (V):

$$V = \frac{\text{Dose Administered}}{\text{Plasma Concentration}}$$

FACTORS AFFECTING :-

* Lipid : Water partition Coefficient of drug
* Pka Value of drug
* Degree of plasma protein
* Affinity to ~~diff. tissues~~ different tissue
* Fat :- Lean Body Mass Ratio.
* Disease like CHF, anemia, cirrhosis.

(iii) BIOTRANSFORMATION:-

PROFESSOR
Department of Pharmacology
Tenkaleswara Dental College & Hospital
Chennai-600 130.

It means chemical Alteration of the drug in the Body. It is needed to render nonpolar compounds polar. So they are not reabsorbed in renal tubules & excreted

Primary Site of drug metabolism is LIVER.

Biotransformation of drugs may lead to

* Inactivation
* Active metabolite from an Active drug.
* Activation of inactive drug.

(iv) EXCRETION OF DRUG:-

It is the passage out of systemically absorbed drug.

Drugs and their metabolites are excreted in → Urine - Through Kidney
→ Milk
→ Faeces
→ Exhaled Air
→ Saliva & Sweat

Renal Excretion

The kidney is responsible for all water-soluble substances.

Net Renal excretion = (glomerular filtration + Tubular excretion) − Tubular reabsorption.

3.

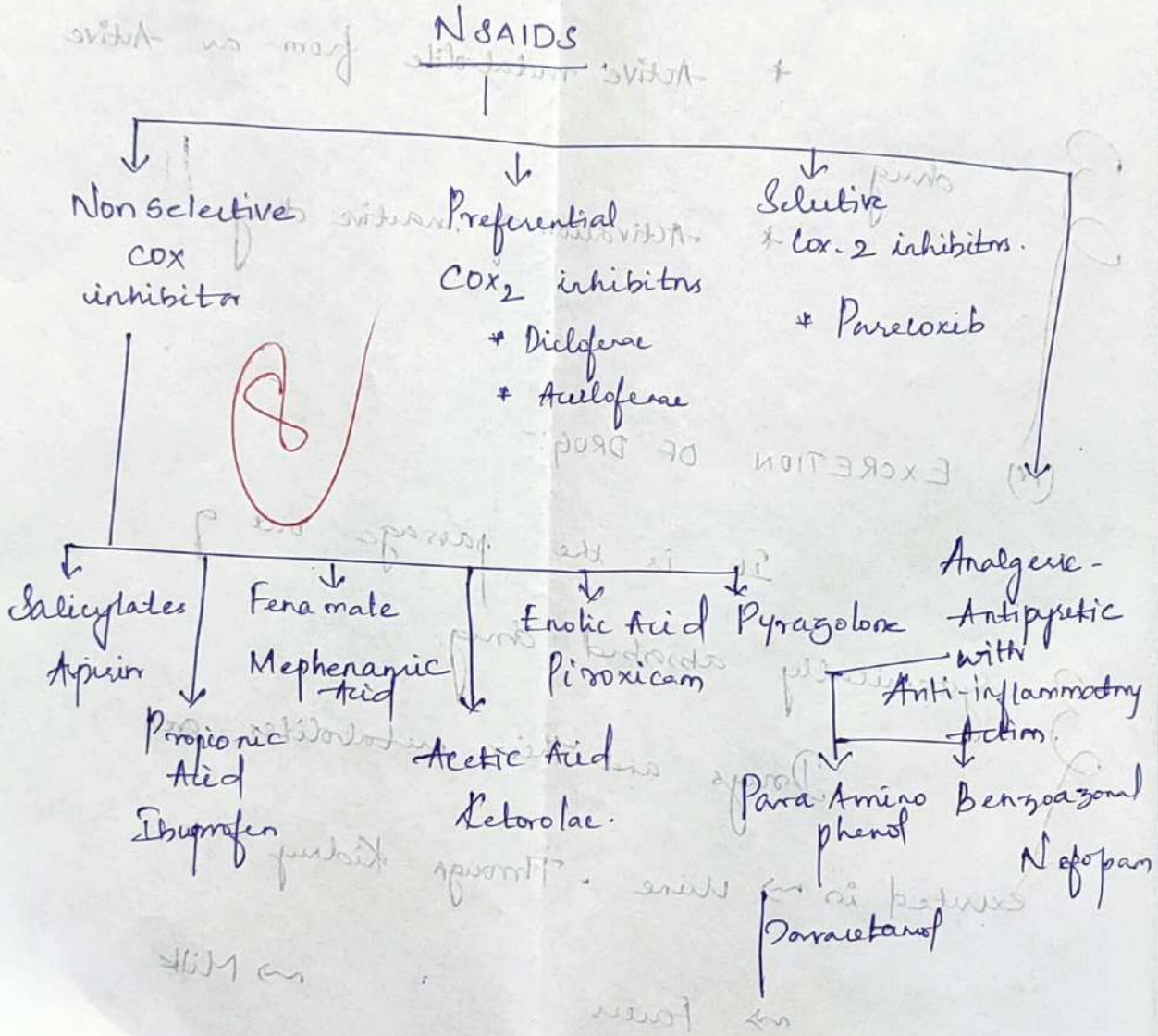

PROFESSOR & HOD
Department of Pharmacology
Sri Venkateswara Dental College & H
Chennai-600 130.

ASPIRIN :-

It is a Acetyl Salicylic Acid Converted to Salicylic acid responsible for most actions.

Oldest Analgesic Anti-inflammatory drugs.

USES :-

* Analgesic
* Antipyretic
* Antipyretic
* Rheumatoid arthritis
* Acute Rheumatic fever.

PROFESSOR & HOD
Department of Pharmacology
Sri Venkateswara Dental College & Hospital
Chennai-600 130.

Pharmacology

22/30

Kaithikeyan. P

1) Various Routes of drug administration

Local action
→ Topical
→ Deeper tissues
→ Arterial supply

Systemic action
→ Oral
→ Sublingual or Buccal
→ Rectal
→ Cutaneous
→ Inhalation
→ Nasal
→ Parenteral → Intravenous
→ Intradermal
→ Subcutaneous
→ Intramuscular

Oral route :

① Advantages

→ Oldest & Convenient mode of drug administration

→ Safer, more convenient, does not need assistance, non invasive, often painless,

→ The medicament need not be sterile & so is cheaper.

→ Solid dosage forms (powder, tablets, moulded tablets, gastrointestinal therapeutic system) and liquid dosage form (syrup, emulsion, mixtures) can be given

Disadvantage:

→ Action is slower & thus not suitable for emergencies.

→ Unpalatable drugs (chloramphenicol) are difficult to administer, drug may be given in capsule to circumvent this.

→ May cause nausea & vomiting.

→ cannot be used for uncooperative / unconscious / vomiting patient

→ certain drugs are not absorbed. Absorption of drug is erratic.

→ other are destroyed by digestive juices.

→ by liver first pass metabolism.

Intravenous:

→ drug is injected as a bolus or infused slowly over hours in one of the superficial veins.

→ The drug directly reaches into the bloodstream & effects are produced immediately.

→ the intima of vein is insensitive and drug gets diluted with blood, therefore, even highly irritant drugs can be injected.

→ The hazards are thrombophlebitis of injected vein & necrosis of adjoining tissues, if extravasation occurs.

PROFESSOR & HOD
Department of Pharmacology
Sri Venkateswara Dental College & Hospital
Chennai-600 130.

→ Absorption is faster.
→ Mild irritants can be injected.
→ It is less painful, but self-injection is often impracticable.
→ Deep penetration is needed.
→ Depot preparation can be injected by this route.
→ IM injection should be avoided in patients taking anticoagulant medication.

Local routes

→ It used for localised lesion at accessible sites and for drugs whose systemic absorption from these site is minimal
→ High concentration are attained at the desired site. Without exposing the rest of the body.
→ Systemic side effects or toxicity are consequently absent

Parenteral routes

→ The drug is directly into the tissue fluid or blood without having to cross the enteral mucosa.
→ Drug action is faster & surer.
→ Emetic irritation & vomiting is not
→

→ These complications can be minimised by diluting the drug or injecting into a running IV line.

→ only aqueous solution can be injected i.v.

2) there are no depot preparations for this route

→ the dose of the drug required is smallest & even large volume can be injected

→ 100% of bioavailability.

→ this route - it can separate immediately meanwhile the drug is short acting

Sodium nitroprusside is a short acting drug.

→ The most risky route - vital organs like heart, brain — get exposed to high concentration of drug.

→ Air embolism is the rare complication can occur.

Intramuscular

→ The drug is injected in one of the large skeletal muscles - deltoid, triceps, gluteus maximus, rectus femoris.

→ muscle is less richly supplied. With sensory nerves & more vascular.

PROFESSOR & HOD
Department of Pharmacology
Sri Venkateswara Dental College & Hospital
Chennai-600 130.

provided.

→ No chance of interference by digestive juices.
→ Liver is bypassed.

2. NSAIDS

Nonsteroidal, anti-inflammatory drugs / Antipyretic - Analgesic

① Nonselective cox inhibitors

→ Salicylate = Aspirin.
→ propionic acid derivative = Ibuprofen, Naproxen, Ketoprofen.
→ fenamate = mefenamic acid
→ Enolic acid derivative = piroxicam, Tenoxicam.
→ Acetic acid derivatives = Ketorolac, Indomethacin.
→ Pyrazolon derivatives = phenylbutazone, oxyphenbutazone, propyphenazone.

② Preferential cox-2 inhibitors:

Nimesulide
- Diclofenac
- Aceclofenac.

③ Selective cox-2 inhibitors

- celecoxib, Etoricoxib.

④ Analgesic - antipyretic with poor inflammatory action

→ paraaminophenol derivative = paracetamol.

→ Benzoxazocine derivative = nefopam.

Aspirin

Mechanism of action.

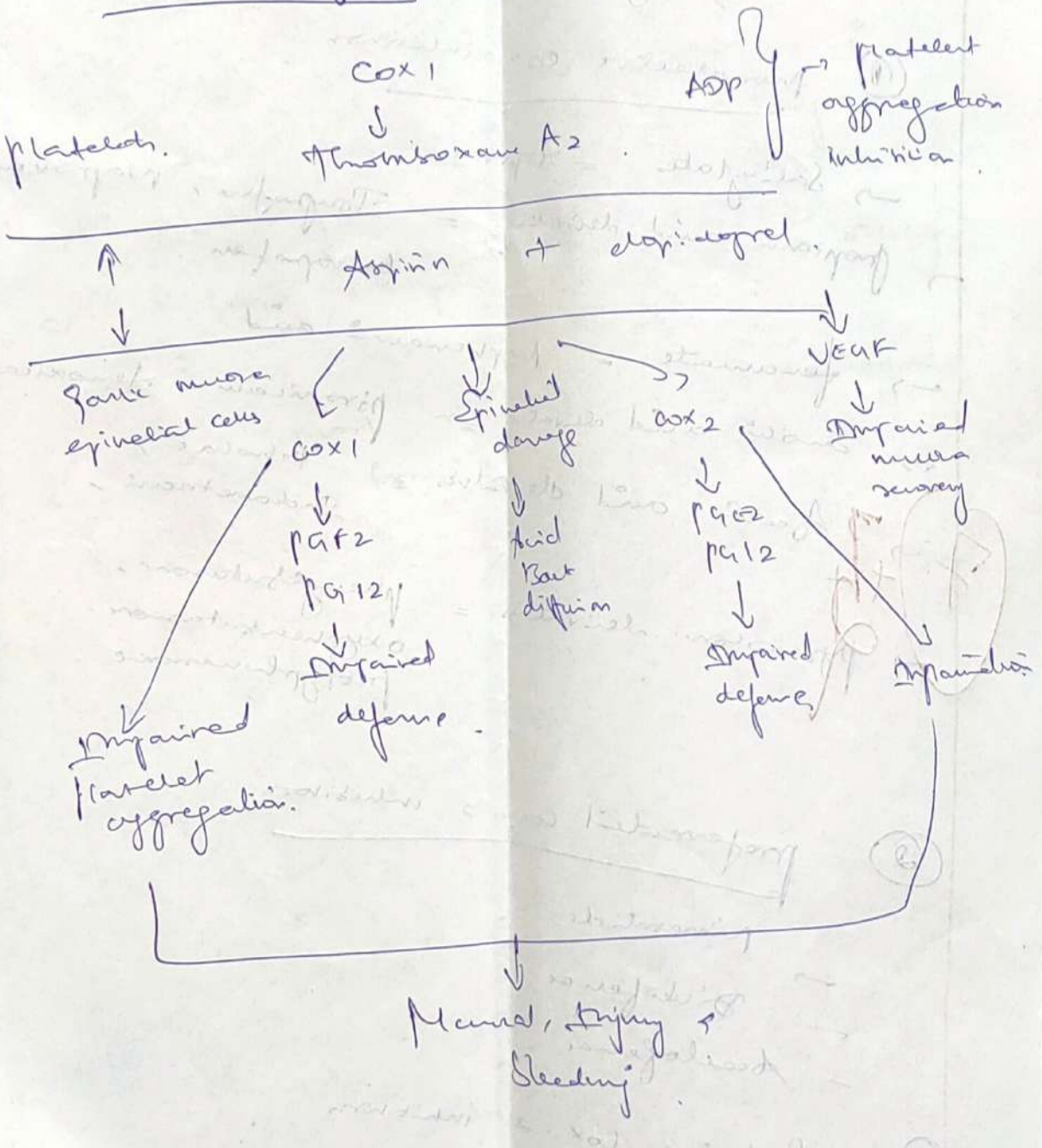

PROFESSOR & HOD
Department of Pharmacology
Sri Venkateswara Dental College & Hospital
Chennai-600 130.

→ Anti-inflammatory action is occurred at high dose (3 – 5 g/day).

→ Sign of inflammation (pain, tenderness, swelling, vasodilatation, leucocyte infiltration)

↓

Progression of underlying disease (rheumatoid arthritis, rheumatic fever, osteoarthritis).

↓

Aspirin (irritate gastric mucosa)

↓

Causing epigastric distress, nausea & vomiting.

↓

High doses (stimulate CTC)

↓

Cellular metabolism is enhanced, especially in skeletal muscles due to uncoupling of oxidative phosphorylation

↓

Glucose utilization is increased resulting in fall in blood glucose level. a liver glycogen is cause sympathetic stimulation & rise in blood sugar.

↓

Respiratory stimulation is tends to washout CO_2 & produce

respiratory alkalosis

↓

Compensated by enhanced HCO_3 excretion by kidney.

↓

Soluble aspirin tablets containing calcium carbonate + citric acid → less liable to cause gastric ulceration.

↓

Aspirin in contact with gastric mucosa.

↓

local sacks diffusion of acid

↓

focal necrosis of mucosal cells + capillaries

↓

Acute ulcers, erosive gastritis, congestion & microscopic hemorrhages.

↓

Occult stool loss in stool is increased by even single dose of aspirin.

↓

Blood loss average 5ml day.

Adv effect.

→ Nausea, vomiting, epigastric distress,
→ Reye syndrome (Hepatic encephalopathy)
Acute salicylate poisoning.
→ Bleeding tendencies.
→ chronic liver disease.

3) Absorption.

movement of drug from its site of administration into circulation

Factors affecting

- Aqueous solubility
- route of administration
- Vascularity of absorbing surface.
- Area of absorbing surface.

Distribution

→ once drug enter into bloodstream, it get distribute to other tissue.

→ liquid solubility.
→ Extent of binding to plasma & tissues.

PHARMACOLOGY

V. Abirami
PROFESSOR & HOD
Department of Pharmacology
Sri Venkateswara Dental College & Hospital
Chennai-600 130

25/30

ESSAY:

1. ROUTES OF ADMINISTRATION:

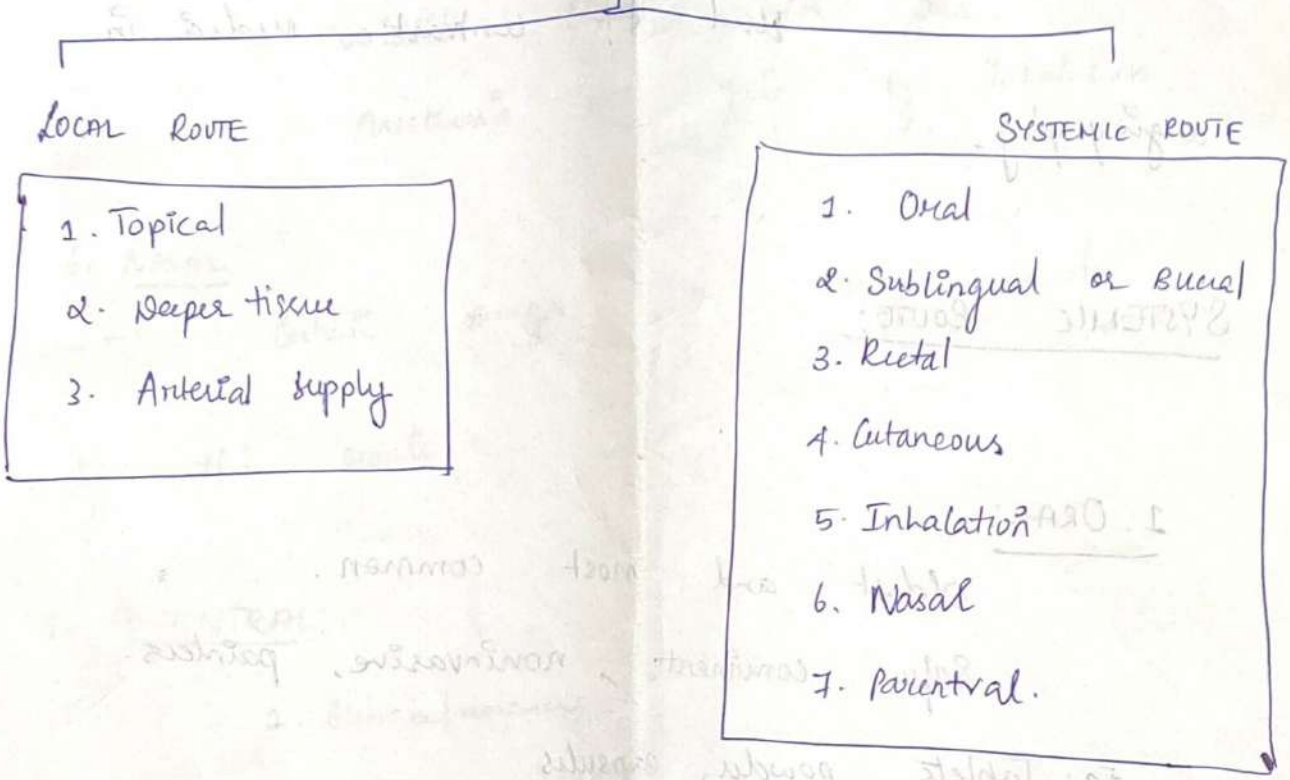

LOCAL ROUTE:

1. TOPICAL:

External application of drug to surface for localized action.

Drug is derived to skin, nasal mucosa, vagina, buccal mucosa.

2. Deeper tissue:

Approached by syringe.

Eg: 1. Intramuscular
2. Intra articular
3. Retro bulbar injection.

3. ARTERIAL SUPPLY:

Used for contrast media in angiography.

SYSTEMIC ROUTE:

1. ORAL:

Oldest and most common.

Safer, convinent, noninvasive, painless.

Eg: Tablets, powder, capsules

2. SUBLINGUAL OR BUCCAL

Tablet is placed under tongue

Lipid soluble and non irritating drugs can be administered.

Sublingual Drugs: Eg: Glyceryl Trinitrate

3. RECTAL :

Inconvenient & Embarrassing

4. CUTANEOUS :

Lipid drug over skin

Ointment

5. INHALATION :

Volatile liquid and gas.

Anesthetic are given by inhalation

6. NASAL :

Certain drugs are only used by this route.

7. PARENTRAL :

1. Subcutaneous
2. Intramuscular
3. Intravenous
4. Intradermal.

PROFESSOR & HOD
Department of Pharmacology
Sri Venkateshwara Dental College & Hospital
Chennai-600 130.

ADVANTAGES

1. ORAL:

Adv: 1. Safer

2. Easy to use

3. Noninvasive

4. No assisstance needed for administion

5. Painless.

6. Convenient

Disadvantage:

1 action is slower

2. Not suitable for emergency

3. Cause nausea & vomiting

4. Cannot be used in unco-operative unconscious patient

INTRAMUSCULAR:

Adv: 1 Absorption is faster

2. Less painful than I.V.

3. Mild irritant can be injected

PROFESSOR & HOD
Department of Pharmacology
Sri Venkateswara Dental College & Hospital
Chennai-600 130

Q: ABSORPTION:

Movement of drug from site of administration to circulation.

Not only the fraction of dose administered gets absorbed but also the rate of administration is important

FACTORS AFFECTING:

1. Aqueous solubility
2. Concentration
3. Area of absorbing surface.
4. Vascularity of absorbing surface
5. Route of administration.

Disadvantage: 1. Assistance needed for administra

2. Painful

3. Invasive

4. Cannot be used in patient taking anticoagulant medication.

INTRAVENOUS:

Adv: 1. Highly irritant drugs can be injected.

2. Drug dose is less.

3. Immediate Effect.

4. Short acting drugs can be used

Disadv: 1. Painful

2. Invasive

3. Risk of thrombophlebitis

4. Air Embolism can occur

5. Assistance for administration needed.

6. Haematoma.

7. Necrosis of adjoining tissue.

(ii) DISTRIBUTION:

PROFESSOR & HOD
Department of Pharmacology
Sri Venkateswara Dental College & Hospital
Chennai-600 130.

Once the drug enters the blood, it is now distributed to other tissue.

These tissue initially has no drug, cone. gradient being in direction of a drug depends on 4 factors.

4
→ Liquid Solubility.
→ Ionisation at physiological pH
→ Extent of binding to plasma.

V = Dose administered i.v
Plasma Conc

FACTORS AFFECTING:

pK value of drug
Degree of plasma protein binding
Affinity of different tissue.

(iii) BIOTRANSFORMATION:

It means chemical alteration of drug in body.

It is needed to render nonpolar compounds polar

So they are not reabsorbed in renal tubules & excreted.

PRIMARY SITE OF DRUG METABOLISM IS LIVER:

BIOTRANSFORMATION OF DRUG MAY LEAD TO:

4

1 Inactivation

2 Active metabolic from an active drug

3. Activation of inactive drug

(iv) EXCRETION OF DRUG:

It is the passage out of systemically absorbed drug

3

Drugs and their metabolites are excreted in → urine - through kidney

→ Faces

→ Exhaled air

→ Milk.

PROFESSOR & HOD
Department of Pharmacology
Sri Venkateswara Dental College and Hospital
Chennai-600

RENAL EXCRETION:

Kidney is responsible for all water soluble substances

Net renal excretion =

(Glomerular filtration + Tubular Excretion)

− Tubular reabsorption.

3)

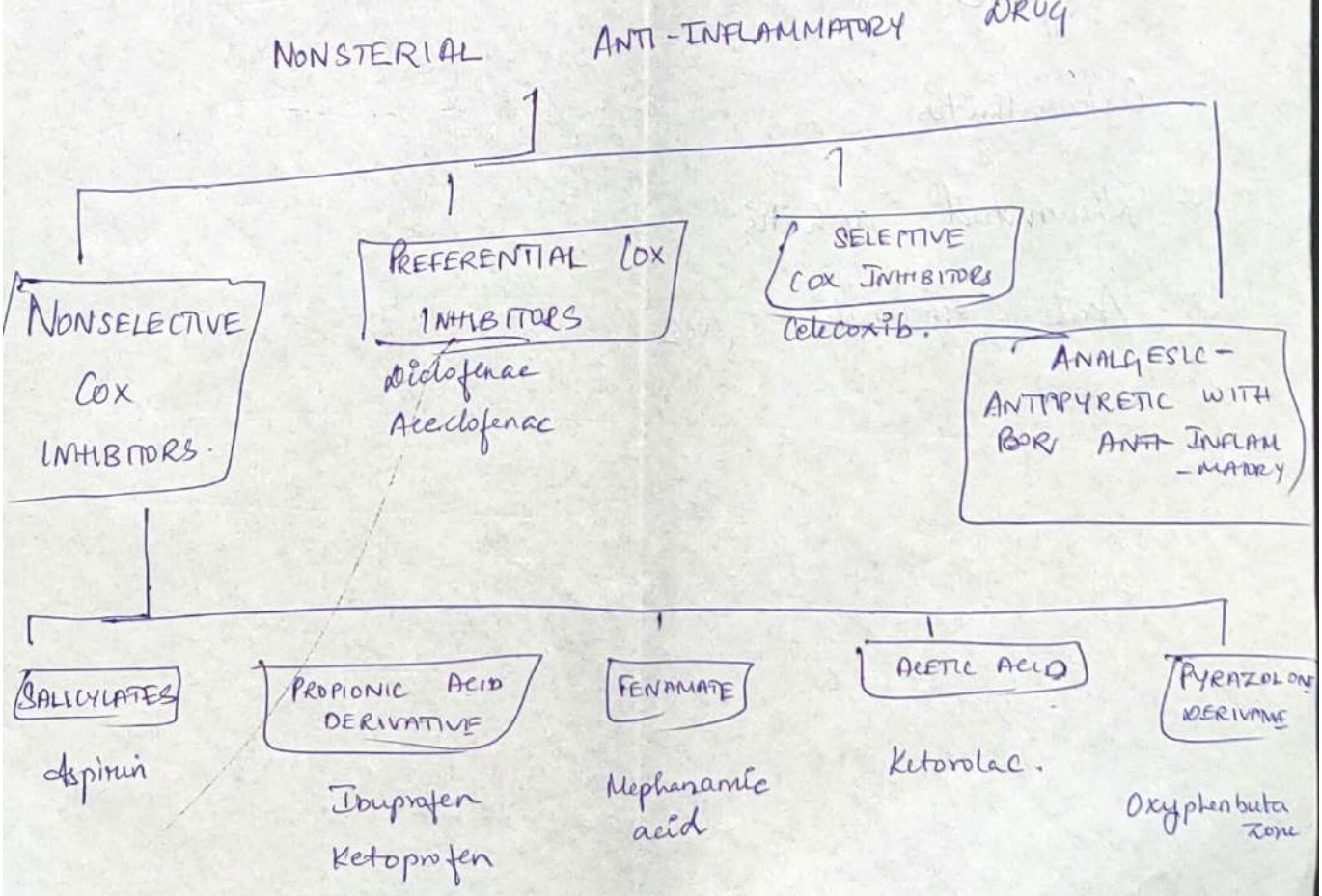

ASPIRIN!

It is acetylsalicylic acid.

Converted to salicylic acid → responsible for most actions.

Oldest analgesic - anti inflammatory drugs.



USES:

1. Analgesic
2. Antipyretic
3. Osteoarthritis
4. Rheumatoid arthritis
5. Acute rheumatic fever

PROFESSOR & HOD
Department of Pharmacology
Sri Venkateswara Dental College & Hospital
Chennai-600 130.

23/30

Pharmacology

Shruthi. J

I. Essay:

1. Routes of Drug Administration:

Local Route
1. Topical
2. Deeper Tissue
3. Arterial supply

Systemic Route
1. Oral,
2. Sublingual or Buccal
3. Rectal
4. Cutaneous
5. Inhalation
6. Nasal
7. Parental

Local Route:

1. Topical:

External application of drug to surface for localized action.

Drug is desired to skin, nasal mucosa, eye, Buccal mucosa

2. Deeper Tissue :

Approached by syringe.

eg: Intramuscular, Intraarticular, Retrobulbar injection.

3. Arterial Supply:

Used for contrast media in angiography

Systemic Route :

1. Oral :

oldest & most common.

Safer, convinient, non-invasive, painless.

eg: Tablets, powder, capsules.

2. Sublingual or Buccal:

Tablet is placed under Tongue

Lipid soluble and non irritating drugs can be administrated.

Sublingual Drugs : eg: Glyceryl Trinitrate.

PROFESSOR & HOD
Department of Pharmacology
Sri Venkateswara Dental College & Hospital
Chennai-600 130.

3. Rectal:

Inconvenient & Embrassing

4. Cutaneous.

Lipid Drug over Skin. Ointment.

5. Inhalation:

Volatile liquid and Gas.
Anesthesia are given by Inhalation

6. Nasal:

Certain drugs are only used by this route.

7. Parenteral:

1. Subcutaneous
2. Intramuscular
3. Intravenous
4. Intradermal.

Q) ABSORPTION:

Movement of Drug from site of administration to circulation.

Not only - the fraction of dose administered gets absorbed but also the rate of administration is important.

Factors Affecting:

1. Aqueous solubility.
2. Concentration
3. Area of absorbing surface.
4. Vascularity of absorbing surface.
5. Route of administration

Disadvantage:

1. Assistance needed for administration
2. Painful
3. Invasive
4. Cannot be used in patient taking anticoagulant medication

PROFESSOR & HOD
Department of Pharmacology
Sri Venkateswara Dental College & Hospital
Chennai-600 130.

Intravenous :

Advantage :

1. Highly irritant drugs can be injected.
2. Drug dose is less.
3. Immediate effect.

Disadvantage :

1. Painful
2. Invasive
3. Risk of Thrombophlebitis.
4. Air embolism may occur.

(ii) Distribution :

Once the drug enters the blood, it is now distributed to other tissue.

These Tissue initially has no drug. Conc gradient being in direction of a drug depends on its

→ Liquid solubility
→ Ionisation at physiological PH
→ Extent of binding to plasma

$$V = \frac{\text{Dose administered}}{\text{Plasma conc}} \text{ i.v.}$$

Factors affecting :

1) Pk value of drug
2) Degree of plasma protein
3) Affinity of different Tissue

(iii) BIOTRANSFORMATION :

It means chemical alternation of drug in body.

It is needed to render nonpolar compound polar.

To They are not reabsorbed in rend Tubules & excreted.

The Primary site of Drug metabolism is liver.

(iv) EXCRETION OF DRUG :

It is the Passage out of systemically absorbed drug.

(v) RENAL EXCRETION:

PROFESSOR & HOD
Department of Pharmacology
Sri Venkateswara Dental College & Hospital
Chennai-600 130

Kidney is responsible for all watersoluble substances.

Net renal excretion =

(Glomerular filtration + Tubular Excretion)
- Tubular reabsorption.

3)

NON-STEROIDAL ANTI-INFLAMMATORY DRUG.

- NON-SELECTIVE COX INHIBITORS
- SELECTIVE COX INHIBITORS
  - celecoxib
- ANALGESIC-ANTIPYRETIC WITH POOR ANTI-INFLAMMATORY
- PREFERENTIAL COX INHIBITORS
  - Diclofenac
  - Aceclofenac
- 7
  - Salicylates
  - Fenamate
  - Propionic acid derivative
  - Acetic acid
  - Pyrazolone Derivative

Aspirin :

It is acetylsalicylic acid ;

Converted to salicylic acid → Responsible for most actions.

Oldest analgesic - anti inflammatory drugs.

Uses :

- Analgesic
- Antipyretic
- Osteoarthritis
- Rheumatoid arthritis
- Acute Rheumatic fever

PROFESSOR & HOD
Department of Pharmacology
Sri Venkateswara Dental College & Hospital
Chennai-600 130.

PHARMACOLOGY

Name: Vethakarthiga. N. 25/30
Year: IInd year

J. Venkatadri

ESSAY

1. ROUTES OF DRUG ADMINISTRATION.

There are multiple routes of drug administration.

They are of two types:

9 i) Local Route

ii) Systemic Route

i) Local Routes:

- There are different routes of drug administration locally.
- They have minimal systemic absorption.
- They have slow rate of absorption.

- The different routes are:

a) Topical:

It is the application of drug onto the skin / mucosal surface.

b) Deeper tissues:

It is the method of injecting the drug into the deeper tissues using a syringe.

Eg: Local anesthetic solution

c) Arterial supply:

It is the injection of drug into the artery.

Eg: Radiopaque drugs for angiography.

PROFESSOR & HOD
Department of Pharmacology
Sri Venkateswara Dental College & Hospital
Chennai-600 130.

ii) Systemic Routes.

- The drug is delivered directly to the blood.
- Faster rate of absorption.
- The different routes of systemic administration of drugs are.

a) Oral:

- It is the intake of drug orally.
- It is painless, inexpensive, convenient.
- Available drug forms are: Tablets, Capsules, Powders, Syrups, etc

b) Rectal:

- It is the form of drug administration through the rectum.

- Irritant & unpleasant drugs can be administered this way.

- Slow absorption
- Can cause inflammation in rectum.
  Eg: Enema

c) Sublingual:

- The drug is placed sublingually
- Has rapid absorption rate.

Eg: GTN during anginal attack can be given sublingually.

PROFESSOR & HOD
Department of Pharmacology
Sri Venkateswara Dental College & Hospital
Chennai-600 130.

c) Nasal

- In this method, the drugs are inhaled through the nose.

- Forms of drug: drops, sprays.

d) Inhalation:

- Certain drugs are given through inhalational method,

Eg: General anesthetics.

e) Parenteral:

- They are the methods of administering drugs directly into the bloodstream without having

it enters the digestive system. iii)

The different parenteral routes of drug administration are:

i) Subcutaneous:

- The drug is delivered to the subcutaneous tissue

- Less painful than vascular injection.

ii) Intravenous:

- The drug is injected slowly into the vein.

- Rapid rate of absorption.

- Can be given to even unconscious patient and in emergency cases.

PROFESSOR & HOD
Department of Pharmacology
Sri Venkateswara Dental College & Hospital
Chennai-600 130.

iii) Intramuscular:

- The drug is injected into muscle.

- Rapid absorption.

- Can be painful.

iv) Intradermal injection:

- The drug is injected ~~directed~~ into the skin using a syringe.

Eg: Vaccines like BCG.

2. Explain:

a) Absorption:

Absorption is the movement of drug from its administration site into the circulation.

Factors affecting absorption are:

i) Aqueous solubility.
ii) Concentration of drug.
iii) Vascularity.
iv) ~~Root~~ Route of administration.

(2)

b) Distribution:

Distribution refers to the distribution of drug to the tissues of the body

(2)

Once the drug enters the circulation.

PROFESSOR & HOD
Department of Pharmacology
Sri Venkateswara Dental College & Hospital
Chennai-600 130.

c). Biotransformation:

It refers to the transformation of the drug when it is absorbed into the body.

(2) d) Excretion:

- Excretion is the passing of the drugs that were absorbed.

(2) - The different routes of drug excretion are:

- Saliva
- Sweat
- Urine
- Milk
- Feces.

3. NSAIDS

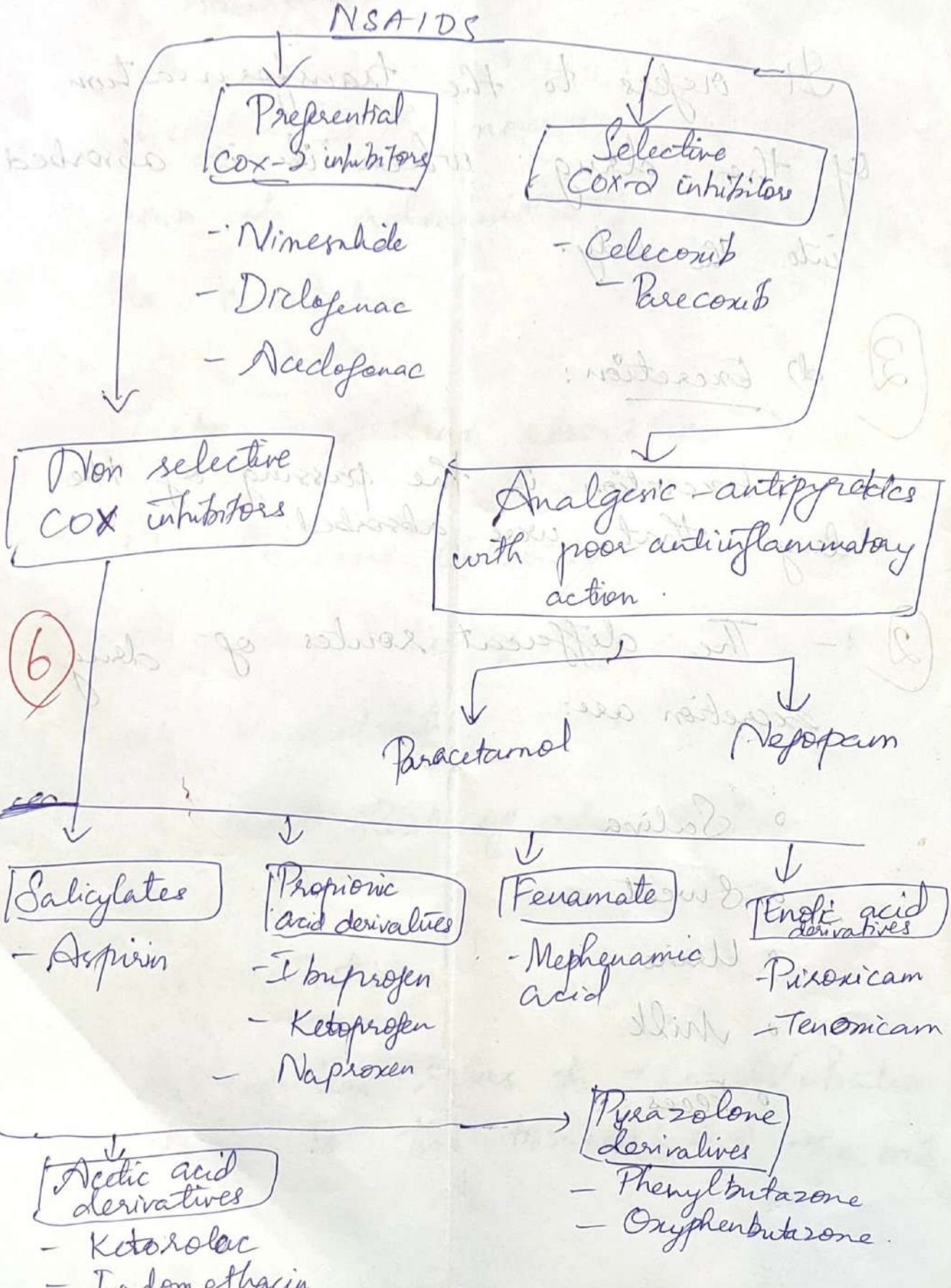
NSAIDS
Preferential cox-2 inhibitors
- Nimesulide
- Diclofenac
- Aceclofenac
Selective cox-2 inhibitors
- Celecoxib
- Parecoxib
Non selective cox inhibitors
Analgesic - antipyretics with poor antiinflammatory action.
Paracetamol
Nefopam
6
Salicylates
- Aspirin
Propionic acid derivatives
- Ibuprofen
- Ketoprofen
- Naproxen
Fenamate
- Mephenamic acid
Enolic acid derivatives
- Piroxicam
- Tenoxicam
Pyrazolone derivatives
- Phenylbutazone
- Oxyphenbutazone
Acetic acid derivatives
- Ketorolac
- Indomethacin

PHARMACOLOGY

S. Kirubakaran
PROFESSOR & HOD
Department of Pharmacology
Sri Venkateswara Dental College & Hospital
Chennai-600 130.

22/30

Essay

1. Routes of drug administration

Routes of administration

Local route

1. Topical
2. Deeper tissue
3. Arterial supply

Systemic route.

1. Oral
2. Sublingual & buccal
3. Rectal
4. Cutaneous
5. Inhalation
6. Nasal
7. Parenteral.

7

1. Local route

* Topical: External application of drug to surface for localized action

Drug is delivered to skin, Nasal mucosa, Vaginal, buccal mucosa.

* Deeper tissue: Approached by syringe

eg: 1 Intramuscular
2. Intraarticular
3. Retrobulbar injection

3. ARTERIAL SUPPLY :

Used for contrast media in angioplasty.

Systemic route :

Oldest and most common safer convenient, noninvasive, painless.

Eg : Tablets, Powder, Capsules.

2. Sublingual or buccal :

Tablet is placed under tongue.

Lipid soluble and non irritating drugs can be administrated.

Sublingual drugs : Eg : Glyceryl Trinitrate.

3. Rectal :

Inconvenient & embarassing.

4. Cutaneous :

Lipid drug over skin.

eg: Ointment.

5. Inhalation :

Volatile liquid and gas. Anesthesia are given by inhalation.

6. Nasal :

Certain drugs are only used by this route.

PROFESSOR & HOD
Department of Pharmacology
Sri Venkateswara Dental College & Hospital
Chennai-130.

7. Parentral:

Administration by which taken by drug

Advantages

1) Oral

1. Safer
2. Early to use
3. Noninvasive
4. No assistance needed for administration
5. Painless.
6. consistent.

Disadvantages

1) Action is slower
2) Not suitable for emergency.
3) Cause nausea & vomitting.
4) Cannot be used in uncorporated. Unconscious patient.

Intramuscular

Advantages 1) Absorption is faster
2) Less painful than IV.
3) Mild irritant can be ejected.

Disadvantages

1) Assistance needed for administration
2) painful
3) Invasive
4) Cannot be used in Painful taking anticoagulant

INTRAVENOUS

Advantages:

1) Highly irritant drug can be injected
2) Drug dose is less.
3) Immediate effect.
4) Short acting drugs can be used.

Disadvantages

1) Painful
2) Invasive
3) Risk of thrombophlebitic
4) APE embolism can occur
5) Assistance of administration
6) Haematoma
7) Necrosis of adjacent tissues.

PROFESSOR & HOD
Department of Pharmacology
Sri Venkateswara Dental College & Hospital
Chennai-600 130.

2. ABSORPTION:

It is the movement of drug from its site of administration into circulation. Not only the fraction of dose administered get absorbed but also the rate of absorption is important.

Factors affecting:

Aqueous solubility
Concentration
Area of absorbing surface.
Vascularity of absorbing surface
Route of administration.

DISTRIBUTION:

once the drug has enters into bloodstream it gets distributed to other tissue. that initially has on drug, cant gradient being in direction of a drug depends on

→ Liquid solubility.
→ Ionisation at physiologic pH.
→ External of binding to plasma & tissues.

Difference in Regional blood flow.

Apparent Volume of distribution (Vd)

$V = \frac{\text{Dose Administered i.v}}{\text{plasma concentration}}$

Factors affecting

i) Lipid : water partition coefficient of drug

ii) PKa value of drug

iii) Degree of plasma protein.

iv) Affinity for different tissue.

v) Fat : Lean body mass ratio

vi) Disease like CHF, Anaemia, Cirrhosis.

BIOTRANSFORMATION

It means chemical alteration of drug in the body. It is needed to render, nonpolar compounds polar.

So they are not reabsorbed in renal tubules & external.

Primary site of drug metabolism's liver.

Biotransformation site of drug metabolism.

PROFESSOR & HOD
Department of Pharmacology
Sri Venkateswara Dental College & Hospital
Chennai-600 130.

lead to

Inactivation

Action metabolite form an action

Activation of inactive drug.

iv) Excretion of drug

It is the passage out of systemically absorbed drug.

Drugs and thier metabolites are excreted in urine through kidney.

→ Faces

→ Exhaled air

→ Milk.

Renal excretion:

Kidney is responsible for all water soluble substances

Net renal excretion =

(glomular filtration + Tubular excretion) − Tubular reabsorption

(8)

NSAIDs

- Non selective COX inhibitors
- Preferential Cox inhibitors
- Selective cox inhibitors
- Analgesic Antipyretic with poor anti-inflammatory

Non selective COX inhibitors:

- Salicylates
  - Aspirin
- Propionic acid derivative
  - Ibuprofen
  - Ketoprofen
- Fenamate
  - Mephenamic acid
- Acetic acid
  - Ketrolac
- Pyrazole derivative
  - Oxyphenbutazone

6

Aspirin:

It is acetylsalicylic acid, converted to salicylic acid responsible for most actions.

oldest analgesic anti-inflammatory drugs.

Uses:

1) Analgesic
2) Antipyretic
3) Osteoarthritis
4) Rheumatoid arthritis
5) Acute rheumatic fever.

Pharmacology.

Name: Kaviya. P
Department of Pharmacology
Sri Venkateswara Dental College & Hospital
Chennai-600 130.

22/30

1) Routes of drug Administration

- Local routes
  - Topical
  - deeper tissues.
  - Arterial
- Systemic routes
  - Oral
  - Sublingual
  - Rectal
  - cutaneous
  - Inhalation
  - Nasal
  - parenteral
    - Subcutaneous
    - Intravenous
    - Intra muscular.
    - Intra dermal

8

Local routes

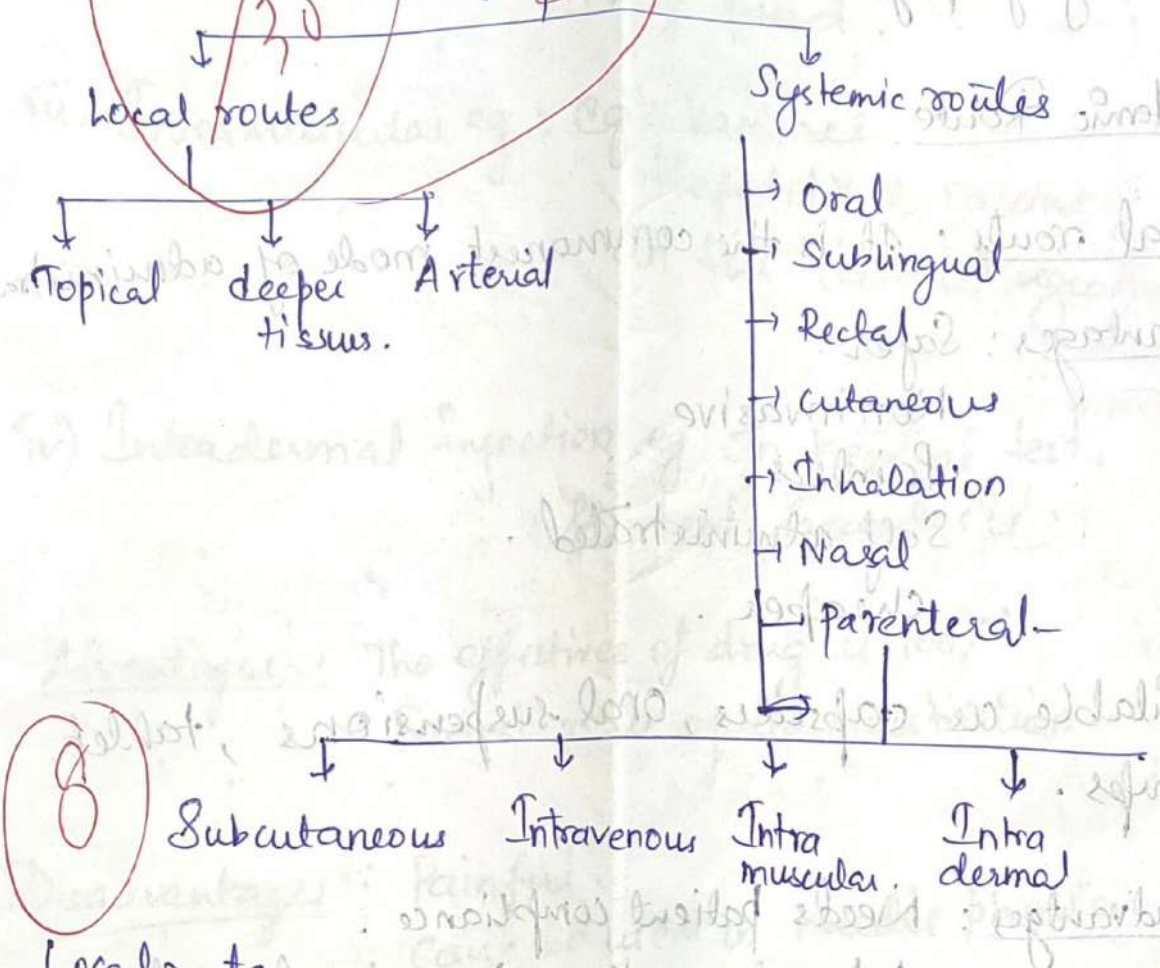

Topical : It is the external application of the drug.
Mucosal topical application is done in case of candidiasis
eg: Steroid application, Neomycin.

Sublingual : Nitroglycerine - 0.5mg is given in the emergency of Myocardial infarction.

It is fastest way in management of myocardial infarction.

Arterial supply : close intra arterial injection of dye is used.

eg: Angiography.

Systemic Route.

Oral route : It is the commonest mode of administration.

Advantages : Safer.
Non invasive
Painless.
Self administrated.
cheaper.

Available as capsules, Oral suspensions, tablet, Syrups.

Disadvantages : Needs patient compliance.
→ Acts slower than parenteral route.
→ Cannot be given in gi ~~dur~~ disturbances of the patients.
→ The effective ~~dose~~ dose is less than parenteral.

Parenteral route.

The various modes of parenteral route of Administration is :-

PROFESSOR & HOD
Department of Pharmacology
Sri Venkateswara Dental College & Hospital
Chennai-600 130.

i) Subcutaneous eg: Insulin

ii) Intravenous. eg: IV of saline + dextrose.
IV of pan d.

iii) Intramuscular eg: eg: Vaccines.
Hepatitis B vaccine
in the deltoid region.

iv) Intradermal injection eg: In Kelvins test,
for test for sarcoidosis.

Advantages: The effectives of drug is 100%.
Fastest route of administration.

Disadvantages: Painful.
Cant be used in Needle phobic patients.
Cannot be self administrated.

Inhalation: It is the inhalation of gaseous form of drug.
eg: Salbutamol in Bronchial Asthma.
fastest way to relieve the symptoms of Bronchial Asthma.

~~Analg~~

(6)

8) NSAIDS



(8)

Analgesics

1) Opioids / Narcotics.
eg: Morphine

NSAIDS
(Non steroidal Antiinflammatory drugs)

Mechanism of Action

PROFESSOR
Department of Pharmacology
Sri Venkateswara Dental College & Hospital
Chennai-600 130.

Membrane lipids.

↓ Phospholipase A_2

Arachidonic Acid

NSAIDs ⟵ ✕ ↓ cyclooxygenase 1
cyclooxygenase 2

Prostagladin h_2

↓

Prostoglladin H, D, E & thromboxane A.

↓

Inflammation.

NSAIDs inhibits the secretion of prostagladins. thereby it reduces inflammation & pain.

~~Advantages~~.

Actions

→ ~~Analgesic~~.

Aspirin.

Uses.

→ Analgesics
→ Antipyretics → used the temperature of the body
→ Used in treatment of Acute rhematic fever.
Post stroke & Post myocardial infarction
→ Used for its pos Anti-Platelet aggregation action → used in low dose for post MI patients.

Disadvantages

→ peptic ulcers.
→ Aggravates gastritis.
→ Hypersensitivity
→
→ Reye's syndrome: If Aspirin administrated for pregnant patients.
→ Acute salicylate poisoning.
→ Vertigo, dizziness, tinnitus.

2). Absorption.

→ Movement of drug from its site of administration into circulation.

2 factors affecting

- Aqueous Solubility
→ route of administration.
→ Vascularity of absorbing surface.
→ Area of absorbing surface

PROFESSOR & HOD
Department of Pharmacology
Sri Venkateswara Dental College
Chennai-600 130.

Distribution : Once drug enters into bloodstream it get distributed to other tissue. That initially has on drug, can't gradient being in direct. Of drug depend on

→ Liquid Solubility

2 → External of binding to plasma & tissues.

Biotranformation : It means chemical alteration of drug in body. So, they are ~~reabos~~ reabsorbed in rend tublon & enternal.

1

PROFESSOR & HOD
Department of Pharmacology
Sri Ramachandra Dental College & Hospital
Chennai-600 116.

24/30

Pharmacology

Nabila Barvin .S

(1) Various routes of drug administration :

Routes of administration can be broadly divided into those for,

i) local action
ii) systemic action.

Local route

These can be used for localized lesions at accessible site and for drugs whose systemic absorption from their site is Minimal.

a) Topical
external application of drug to surface.
b) Deeper tissues
c) Arterial supply.

Systemic route

It is intended to be absorbed into blood stream. distributed all over, including the site of action. through circulation,

a) Oral
b) sublingual
c) Rectal
d) Cutaneous.
e) Inhalation
f) Nasal
g) Parenteral

a) Subcutaneos
b) Intramuscular
c) Intravenous
d) Interdermal injection

Intravenous

Advantages

1. The drug directly reaches into the bloodstream and effects are produced immediately.
2. It is less painful, but self injection is often impractical.
3. Response is accurately measurable.
4. Titration of dose with response is possible.

disadvantages

1. Possibilty of causing air embolism is another risk.

Intramuscular

Advantages.

1. Muscle is less richly supplied with sensory nerves as is more vascular.
2. It is less painful, self injection is often impracticable.
3. depot preparation can be injected by this route.

Disadvantages.

1) It should be avoided in patients taking anticoagulant medication.

PROFESSOR & HOD
Department of Pharmacology
Sri Venkateswara Dental College & Hospital
Chennai-600 130.

① **Absorption :**

Absorption is the movement of drug from the site of administration into the circulation.

factors affecting absorption,

1. Aqueous solubility.
2. Concentration.
3. Area of absorping surface.
4. Vascularity of absorbing surface.
5. Routes of administration.

distribution :

Once the drug has gained access to the bloodstream, it gets distributed to other tissues.

$$V = \frac{\text{dose administered}}{\text{plasma Concentration}}$$

Factors governing volume of drug distribution

1. Lipid.
2. pKa value of drug
3. degree of plasma protein binding
4. Affinity for diffent tissues
5. Fat
6. Disease like CHF, Uraemia, Cirrhosis.

Biotransformation :
Metabolism

Means chemical alteration of the drug in the body
It is needed to render non-polar compounds polar so that they are absorbed in the renal tubules.

the primary site of drug mechanism is liver.
other are, kidney, intestine, lungs and plasma.
Biotransformation of drugs leads to following,

(1) Inactivation
(2) Active metabolite from an active drug
(3) Activation of inactive drug.

Excretion

excretion is passage out of systematically absorbed drug.
drugs and their metabolites are excreted in,

(1) Urine
(2) faces
(3) exhaled air
(4) Saliva and sweet
(5) Milk

(3) NSAIDO's =

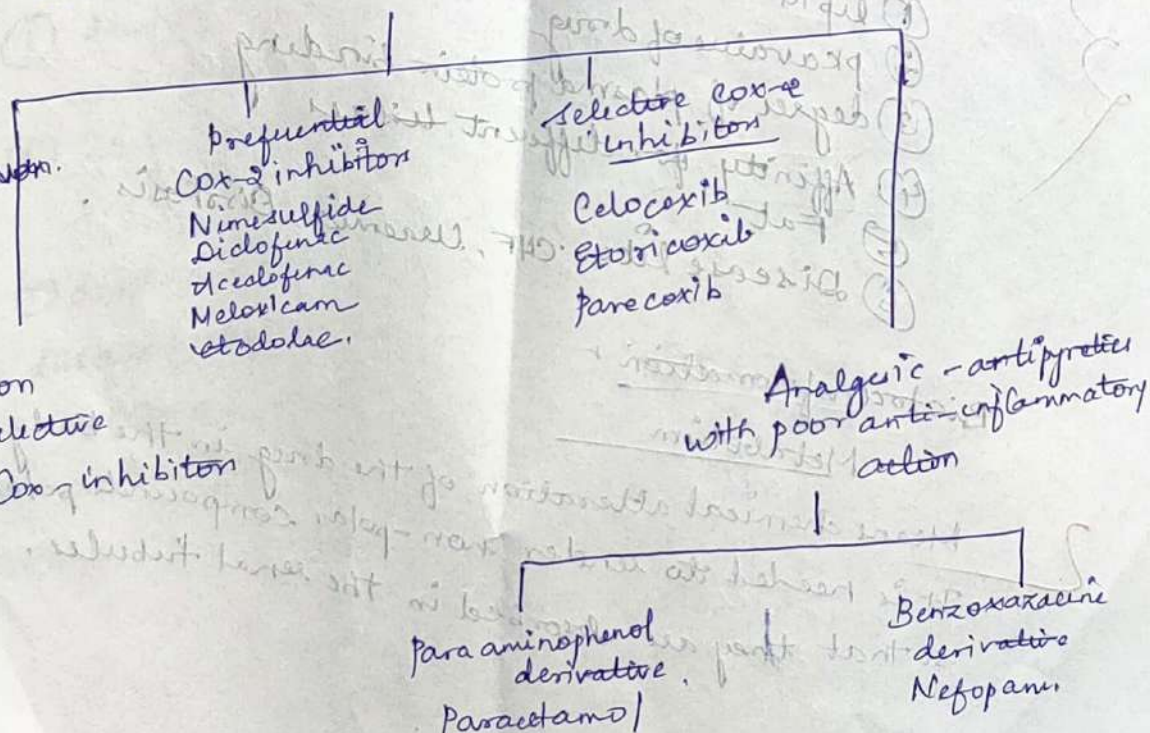

PROFESSOR & HOD
Department of Pharmacology
Sri Venkateswara Dental College & Hospital
Chennai-600 130.

Non-selective cox inhibitors

- Salicylates
  - Aspirin
- Propionic acid derivatives
  - Ibuprofen
  - Naproxen
  - Ketoprofen
  - Flurbiprofen
- Fenamate
  - Mephenamic acid
- Enolic acid derivatives
  - Piroxicam
  - Tenoxicam
- Acetic acid derivatives
  - Ketorolac
  - Indomethacin
  - Nabumetone
- Propionic phenazone

6

Pharmacology

PROFESSOR & HOD
Department of Pharmacology
Sri Venkateswara Dental College & Hospital
Chennai-600 130.

5/20

Hariharan K.
BDS II Year.

1. Describe various routes of drug administration. Explain the advantages and disadvantages of oral intravenous and intramuscular route.

Drugs can be administered by a variety of routes. Routes can be broadly divided into those used for:

a) local action.

b) systemic action

a) Local Routes

- Topical
- Arterial supply
- Deeper tissues.

b) Systemic Routes

- Oral
- Sublingual.
- Cutaneous
- Rectal
- Nasal
- Inhalation
- Parenteral.

6

a) Local Routes.

- Used for drugs which cannot be absorbed from the system properly for localized lesions.

i) Topical.

- It is the external application of drug for

localized action.

- Used for delivering drug to skin, eyes, ear and canal, vagina, etc.
- Antiseptics, astringents, haemostatics are applie as toothpastes, gargles, etc.

ii) Deeper tissues.

- Used for deep areas using syringe and needle
- Systemic absorption of drug should be slow.
- Eg: lidocaine, hydrocortisone acetate.

iii) Arterial supply

- Close intra-arterial injection is used.
- Anticancer drugs can be used.

b) Systemic Routes

- Drugs are ~~intak~~ intended to be absorbed into bloodstream and then distributed all over

i) Oral

- Most commonest method.
- Safer, convenient and no assistance is required
- Drugs can be given in the form of powders, tablets, capsules and liquid dosage forms.

ii) Sublingual or buccal

- Tablet or pellet containing drug placed under the tongue or crushed in the mouth or spread over the buccal mucosa.
- Absorption is rapid and action is produced within minutes.
- Liver is bypassed.
- Eg: glyceryl trinitrate, desamino-oxytocin

PROFESSOR & HOD
Department of Pharmacology
Sri Venkateswara Dental College & Hospital
Chennai-600 130.

iii) Cutaneous

- Used when slow and prolonged absorption is required.
- Highly lipid soluble drugs come under this.
- Drug used as ointment and can be applied over specified area of skin.
- Transdermal therapeutic systems can also be used → adhesive patches.

iv) Rectal

- Irritant and unpleasant drugs can be put into rectum
- Used when patient has recurrent vomiting
- Eg: Indomethacin, diazepam, ergotamine

v) Nasal.

- Eg: GnRH agonists and desmopressin applied as a spray or nebulized solution.

vi) Inhalation.

- Volatile liquids and gases are given by inhalation for systemic action.

vii) Parenteral.

- Administration by injection.

a) Subcutaneous.
   - Dermojet
   - Pellet implantation

b) Intramuscular

c) Intravenous

d) Intradermal injection

2. Explain:

A) Absorption
B) Distribution
C) Biotransformation.
D) Excretion of drugs.

A) Absorption

- It is the movement of drug from its site of administration.
- Factors affecting absorption are:

PROFESSOR & HOD
Department of Pharmacology
Sri Venkateswara Dental College & Hospital
Chennai-600 130.

* Aqueous solubility
* Concentration.
* Area of absorbing surface
* Vascularity of the absorbing surface
* Route of administration:

→ Oral.

• Drugs like ethanol are readily absorbed from stomach as well as intestine at rates proportional to their lipid : water partition coefficient.

• Drugs absorption can be affected by luminal effect and gut wall effect

→ Subcutaneous and intramuscular.

• Drug directly deposited in the vicinity of the capillaries.

→ Topical sites. (skin, cornea, mucous membrane)

• Eg: Glyceryl trinitrate, fentanyl and estradiol.

B) Distribution.

— After entering the bloodstream, the drug gets distributed to other tissues that initially had no drug.

— Apparent volume of distribution (V)

$$V = \frac{\text{dose administered iv}}{\text{plasma concentration}}$$

c) Biotransformation.

- It is the chemical alteration of the drug in the body.
- It renders nonpolar (lipid soluble) compounds polar (lipid insoluble) so that they are not reabsorbed in the renal tubules and are excreted.
- It leads to
  * Inactivation
  * Active metabolite from an active drug
  * Activation of inactive drug

D) Excretion of drugs.

- It is the passage out of systemically absorbed drug.
- Drugs and their metabolites are excreted in:
  * Urine
  * Faeces
  * Saliva
  * Sweat
  * Milk
  * Exhaled air

3. Classify analgesics. Explain mechanism of action, uses and adverse effects of aspirin. (nsaids)

PROFESSOR & HOD
Department of Pharmacology
Sri Venkateswara Dental College & Hospital
Chennai-600 130.

Classification

A) Nonselective COX inhibitors.

1) salicylates : Aspirin
2) Propionic acid derivatives : Ibuprofen
3) Aryl-acetic acid derivatives : Diclofenac.
4) Oxicam derivatives : Piroxicam.
5) Indole derivative : Indomethacin.

B) Preferential cox-2 inhibitors.

- Nimesulide.

c) Selective cox-2 inhibitors.

- Celecoxib, Parecoxib

D) Analgesic - antipyretics with poor antiinflammatory action

- Paracetamol
- Pyrazolone derivatives : Metamizol.
- Benzoxazocine derivative : Nefopam.

Aspirin

Mechanism of Action

- Analgesic, antipyretic anti-inflammatory action.
- Converted into salicylic acid.
- Acetylation of certain macromolecules.

Uses

- As analgesic [Headache, toothache, backache]
- As antipyretic [fever]
- Acute rheumatic fever
- Rheumatoid arthritis
- Osteo arthritis

Adverse Effects

- Nausea, vomiting, epigastric distress. (0.3-1.5g/day)
- Hypersensitivity and idiosyncrasy
- Acute salicylate poisoning
- Anti-inflammatory dose of 3-5g/day cause salicylism [dizziness, tinnitus, vertigo]

Pharmacology

29/30

PROFESSOR & HOD
Department of Pharmacology
Sri Venkateswara Dental College & Hospital
Chennai-600 130.

Haritha-V

1. Describe various routes of drug administration
Explain the advantages and disadvantages of oral intravenous and intramuscular routes.

Drugs can be administered by a variety of routes
Routes can be broadly divided into those for
(a) Local action and (b) Systemic action:

(a) Local Routes

(i) Topical

(ii) Deeper tissues

iii) Arterial supply.

9

b) Systemic Routes

(i) oral

ii) Sublingual or buccal

iii) Rectal

iv) Cutaneous
→ Transderonal therapeutic system.

v) Inhalation

vi) Nasal

vii) Paranteral.

→ Subcutaneous.

* Dermojet.

*) Pellet implantation.

* Sialistic (non biodegradable) and biodegradable implant)

→ Intramuscular.

→ Intravenous.

→ Intradermal Injection.

a) Local Route:

These route can only be used for localized lesions. at accessible sites and for drugs whose systemic absorption from these sites is minimal, slow or absent. → systemic side effects or toxicity are consequently absent or minimal.

(i) Topical.

This refers to external application of the drug to the surface for localized action.

→ mode of delivering the drug to skin, oropharyngeal nasal, mucosa, eyes, ear canal, anal canal, vagina, etc.

ii) Deeper tissues:

→ Certain deep areas can be approached by using a syringe and needle, but the drug should be such that systemic absorption is slow.

PROFESSOR & HOD
Department of Pharmacology
Sri Venkateswara Dental College & Hospital
Chennai-600 130.

iii) Arterial supply.

→ close intra - arterial injection ~~anbsanter~~ is used for contrast media in angiography.

b) Systemic Routes:

→ The drug administered Through systemic routes is intended to be absorbed into bloodstream and distributed all over.

vii) Parenteral.

→ This refers to administration by injection which takes the drug directly into the tissue fluid or blood. ~~of~~ without having to cross the intestinal mucosa.

(*) Intramuscular (i.m).

→ The drug is injected in one of the large skeletal muscles - deltoid, triceps gluteus maximus, rectus femoris, etc. muscle is less richly supplied with sensory nerves and is more vascular. It is less painful, but self-injection is often impracticable.

(*) Intravenous (i.v)

The drug is injected as a bolus or infused slowly over hours in one of the superficial vein.

→ The intima of veins is insensitive and drug gets diluted with blood, Therefore, even highly irritant drug can be injected.

→ hazards are.

→ Thrombophlebitis of the injected vein and necrosis of adjoining tissue if extravasation occurs.

→ This is the most risky route - vital organs like heart, brain, etc. get exposed to high concentration of the drug.

Q2. Explain.

A) absorption

b) Distribution

c) biotransformation

d) excretion of drugs.

A) Absorption.

→ Absorption is the movement of drug from its site of administration into the circulation.

→ Absorption is governed by the above described principle. ~~other~~

PROFESSOR & HOD
Department of Pharmacology
Sri Ramaswamy Dental College & Hospital
Chennai-600 130.

→ other factors affecting absorption are:

i) Aqueous solubility:

→ Drugs given in solid form must dissolve in aqueous biophase before they are absorbed.

ii) Concentration:

→ Passive transport depends on concentration gradient: drug given as concentrated solution is absorbed faster than from dilute solution.

(a) Area of absorbing surface.

(b) vascularity of the absorbing surface.

(c). Route of administration.

d) Aqueous solubility

e) Concentration.

→ oral:

The effective barrier to orally administered drugs is the epithelial lining of the gastrointestinal tract, which is lipoidal.

→ subcutaneous and intramuscular

By these route the drug is deposited directly in the vicinity of the capillaries. Lipid-soluble drugs pass readily across the whole surface of the capillary endothelium.

→ Topical site:

systemic ad absorption after topical application depends primarily on lipid solubility of drugs.

B) Distribution

once a drug has gained access to the blood stream, it gets distributed to other tissues that initially had no drug. Concentration gradient being in the direction of plasma to tissue.

Apparent volume of distribution. (V)

$$V = \frac{\text{dose administered i.v}}{\text{plasma concentration.}}$$

→ Redistribution:

• Highly lipid-soluble drugs get initially distributed to organs with high blood flow.

→ Penetration into brain and CSF:

The capillary endothelial cells in brain have tight junctions and lack large intercellular pores.

→ Passage across placenta:

Placental membranes are lipoidal and allow free passage of lipophilic drugs.

plasma protein binding.

PROFESSOR & HOD
Department of Pharmacology
Sri Venkateswara Dental College & Hospital
Chennai-600 130.

The clinically significant implication of plasma protein bing are:

(i) Highly plasma protein bound drugs are largely restricted to the vascular compartment and.

(ii) The bound fraction is not available for acton.

(iii) Highly degree of protein binding genually makes the drug long acting.

→ Tissue storage:

→ Drugs may also accumulate in specific organs or get bound to specific tissue constituents.

c) Biotransformaton.

It is chemical alteraton of the drug in the body.

→ The primary site for drug metabolism is lever.

Other are - kidney, intestine lung and plasm.

(i) Inactivaton.

most drugs and their active metabolite are rendered inactive or less active.

(ii) Active metabolite from an active drug:

→ Many drugs have been found. to be pathaly

Conveited.

iii) Activation of inactive drug.

→ few drugs are inactive as such and need conversion in the body to one or more active metabolites.

non synthetic reaction

i) oxidation:

ii) Reduction:

iii) Hydrolysis:

$$\text{ester} + H_2O \xrightarrow{\text{esterase}} \text{Acid} + \text{Alcohol}$$

→ synthetic reaction.

(a) Glucuronide Conjugation.

(b) Acetylation.

c) Methylation

d) sulfate Conjugation.

~~e) sulphate Conjugation.~~

e) Glycine Conjugation.

f) Glutathione Conjugation.

g) Ribonucleoside

D) excretion.

Excretion is the passage out of systemically absorbed drug. They are excreated in

i) urine

ii) Faeces.

iii) exhated air.
iv) saliva and sweat.

→ Renal excreation.
i) Glomerular filtration
ii) Tubular reabsorption.
iii) Tubular secreation.
a) organic acid transport.
b) organic base transport.

PROFESSOR & HOD
Department of Pharmacology
Sri Venkateswara Dental College & Hospital
Chennai-600 130.

Renal excreation.
The kidney is responsible for excreting all of water-soluble substance.
net renal excretion = (glomerular filtration + tubular secretion) - tubular reabsorption.

3. Classification of NSAIDS.

Non steroidal Anti inflammatory drugs.

- Preferential COX_2 inhibitors.
  - Declofenac.
  - Aceclofenac.
  - Nimesulide.
- selective COX_2 inhibitors
  - Celecoxib
  - Etoricoxib
  - Paracoxib.
- Analgesic - antipyretics. with poor anti inflammatory action.
  - Para aminophenol derivative.
    - Paracetamol.
  - Benzoxazocine derivative.
    - Nefopam.
- non selective COX inhibitors.
  - Salicylates
    - Aspirin.
  - Propionic acid derivatives
    - Ibuprofen
    - Ketoprofen.
    - aproxen.
  - Fenamate
    - Mephenamic acid.
  - Oxobic acid derivative.
    - Piroxicam
    - Tenoxicam.
  - Acetic acid derivative.
    - Ketorolac
    - Indomethacin.

PROFESSOR & HOD
Department of Pharmacology
Sri Venkateswara Dental College & Hospital
Chennai-600 130.

24/30

JANANI. D

1. VARIOUS ROUTES OF DRUG ADMINISTRATION:-

Most drugs can be administered by variety of routes. The choice of appropriate route in particular depends both on drug as well as patient related.

Routes can be broadly classified into 2 { local action / systemic action.

Local routes:-

These routes can only be used for localized lesions at accessible sites & for drugs systemic absorption from these sites are minimal, slow (or) absent.

Systemic side effects or toxicity are absent (or) minimal.

The local routes are

(i) Topical

(ii) Deeper tissues

(iii) Arterial supply.

Systemic routes:-

The drug administered through systemic routes is absorbed into bloodstream and distributed all over the body.

The systemic routes are

1. oral
2. Sublingual
3. Rectal
4. cutaneous.
5. Inhalation
6. Nasal
7. parenteral
8. Subcutaneous.

Oral routes :-

1. Topical - It is external application of drug to the surface for localized action,

It is more convinient & efficient mode of delivering drug to skin, oropharyngeal, eyes, ears canal.

2. Deeper tissues :-

Deep areas can be approached by using a syringe and needle.

3. Arterial supply -

close intra-arterial injection is used for contrast media in angiography.

Systemic routes:-

PROFESSOR & HOD
Department of Pharmacology
Sri Venkateswara Dental College & Hospital
Chennai-600 130.

1. Oral:-

- It is oldest & commonest mode of drug administration

Advantages:-

- Safer
- more convenient
- painless
- non-invasive
- cheaper.

Disadvantages:-

- It takes more time to action.

2. Sublingual:-

- The tablet (or) pellet containing the drug is placed under tongue (or) crushed in the mouth.

- Only rapid soluble and non-irritating drugs can be administered.

3. Rectal:-

certain irritant & unpleasant drugs can put into rectum as suppositories (or) retention enema for systemic effect.

4. Cutaneous:-

- Highly lipid soluble drugs can be applied over the skin for slow & prolonged absorption

5. Inhalation:-

Volatile liquids & gases are given by inhalation for systemic actions.

Disadvantages :-

- Irritant
- Inflammation.

b. parenteral :-

This refers to administration by injection which takes drug directly into tissue fluid or blood without having to cross the intestinal mucosa.

(i) Subcutaneous :-

The drug is deposited in loose subcutaneous tissue which is richly supplied by nerve

This route should be avoided in shock patients - Vasoconstricted.

(ii) Intramuscular :-

The drug is injected in one of large skeletal muscle. - deltoid, triceps, gluteus maximus, rectus femoris.

Advantages :-

- painless
- Depot preparation

(iii) Intravenous :-

The drug is injected as a bolus (or) Infused slowly over hours in one of the superficial veins

Advantage :-

- Accurately measurable
- titration of dose with response is possible

Disadvantages :-

It is the most risky route.

PROFESSOR & HOD
Department of Pharmacology
Sri Venkateswara Dental College & Hospital
Chennai-600 130.

2. ABSORPTION:-

Absorption is the movement of drug from its site of administration into the circulation.

The factors affecting absorption:-

(i) Aqueous solubility

(ii) Concentration

(iii) Vascularity of the absorbing surface.

(iv) Route of administration.

DISTRIBUTION:-

Once a drug has gained access to the bloodstream it gets distributed to other tissues that initially had no drug. concentration gradient being in the direction of plasma to tissues.

The extent of distribution of a drug depends on its lipid solubility, ionization at physiological pH.

$$V = \frac{\text{dose administered i.v}}{\text{plasma concentration}}$$

Factors governing Volume of drug distribution:-

(i) Lipid

(ii) Pka volume of the drug

(iii) Degree of plasma protein binding

(iv) Affinity for different tissues

(v) Fat - lean body mass ratio

BIOTRANSFORMATION:-

It means chemical alteration of the drug in the body.

It is also known as metabolism

It is needed to render non polar (lipid soluble) compounds polar (lipid insoluble)

Most hydrophillic drugs eg. gentamicin, neostigmine, decatnathonium are not biotransformed & excreted unchanged.

The primary site for drug metabolism is liver, kidney, intestine, lungs & plasma.

EXCRETION:-

Excretion is the passage out of systemically absorbed drug. Drugs and their metabolites are excreted in urine, Faeces, Exhaled air, Saliva & sweat, Milk

Renal Excretion:-

Net renal excretion = (Glomerular filtration + tubular secretion) - tubular reabsorption.

Glomerular filtration:-

Glomerular capillaries have pores larger than usual; all non-protein bound drug presented to the glomerules is filtered.

5. ANALGESICS :-

classification of analgesics :-

Non-steroidal Anti-inflammatory Drugs

- Non-selective cox. inhibitors
  - Salicylates
    - Aspirin
  - Propionic acid derivatives
    - Ibuprofen
    - Naproxen
    - ketoprofen
  - Fenamate
    - Mephenamic acid
  - Enolic acid derivatives
    - piroxicam
    - Tenoxicam
  - Acetic acid derivatives
    - ketorolac
    - Indomethacin
  - Pyrazolone derivatives
    - phenylbutazone
    - oxyphenbutazone
    - propyphenazone
- Preferential cox-2 inhibitors
  - Nimesulide
  - Diclofenac
  - Aceclofenac
  - meloxicam
- Selective cox-2 inhibitors
  - celecoxib
  - Etoricoxib
  - parecoxib
- Analgesic - antipyretics with poor antiinflammatory actions
  - Para-aminophenol derivative
    - paracetamol
  - Benzoxazocine derivative
    - Nefopam

PROFESSOR & HOD
Department of Pharmacology
Sri Venkateswara Dental College & Hospital
Chennai-600 130.

Pharmacology

PROFESSOR & HOD
Department of Pharmacology
Sri Venkateswara Dental College & Hospital
Chennai-600 130.

21/30

Hari Balaji. B

01. Various Routes of Drug Administration.

Most of the drugs can be administered by a variety of routes.

Local Routes

Systemic routes.

Local Routes:

Topical

Deeper tissues

Arterial supply.

8

Topical:

This refers to external application of the drug to the surface for localized action.

It is often more convenient and efficient mode of delivering the drug to skin, oropharynged eyes, ear canal etc.

Deeper tissues:

Certain deep areas can be approached by using a syringe and needle, but the drug should be in such a form that systemic absorption is slow Eg: Infiltration.

Systemmic Routes:

Oral

Sublingual

Rectal
cutaneous
Inhalation
Nasal
Parenteral

Oral:

Oral Ingestion is the oldest and commonest mode of drug administration.

It is safer more convenient, non invasive, painless.

Sublingual:

The tablet or pellet containing the drug is plaed under tongue or crushed in mouth and spread over bucal mucosa.

Rectal:

Certain Irritant and unpleasant drugs can be put into rectum as suppositories or retention enema for systemic effect.

cutaneous:

Highly lipid soluble drugs can be applied over the skin for slow and prolonged absorption.

Inhalation:

Volatile liquids and gases are given by inhalation for systemic action,

Eg: general anaesthetics.

PROFESSOR & HOD
Department of Pharmacology
Sri Venkateswara Dental College & Hospital
Chennai 130.

Intramuscular & Intravenous Routes

Intramuscular:

The drug is injected in one of the large skeletal muscles - deltoid, triceps, gluteus maximus, rectus femoris etc.

Muscle is less richly supplied with sensory nerves.

It is less painful, but self injection is often impractical - deep penetration is needed.

Depot preparations can be injected by this route.

Intravenous:

The drug is injected as a bolus or infused slowly over hours in one of the superficial veins.

The drug directly reaches into the blood stream and effects are produced immediately.

The intima of veins is insensitive and drugs get diluted with blood, therefore, even highly irritant drugs can be injected.

It is accurately measurable and the drug short acting.

02. Absorption, Distribution, Biotransformation, Excretion of drugs.

Absorption:

Absorption is the movement of drug from site of administration into the circulation.

Part-1

Not only the fraction of the administered dose that gets absorbed, but rate of absorption is important.

Other factors affecting absorption are.

Aqueous solubility

concentration

Area of absorbing surface

Vascularity of the absorbing surface.

Route of administration

oral

subcutaneous and intramuscular

topical sites.

Distribution:

Once a drug has gained access to the bloodstream. It gets distributed to other tissues that initially had no drug, concentration gradient being in the direction of plasma to tissues.

Lipid solubility

Ionisation at physiological pH.

Extent of binding to plasma and tissue proteins.

Differences in regional blood flow.

Redistribution.

Penetration into brain & CSF.

Passage across placenta.

plasma protein binding.

Tissue storage.

Biotransformation:

It is chemical alteration of the drug in the body.

The primary site of drug metabolism is liver, others are - kidney, intestine, lungs and plasma.

(i) Inactivation:

Most drugs and their active metabolites are rendered inactive or less active.

Eg: Lidocaine, Ibuprofen.

(ii) Active metabolite from an active drug.

(iii) Activation of inactive drug.

Nonsynthetic reactions:

(i) oxidation

(ii) Reduction

(iii) Hydrolysis.

Excretion:

Excretion is the passage out of systemically absorbed drug. Drugs and their metabolites are excreted in Urine, Faeces, Exhaled air, saliva and sweat. Milk.

PROFESSOR & HOD
Department of Pharmacology
Sri Venkateswara Dental College & Hospital
Chennai-600 130.

03. classification of NSAIDs.

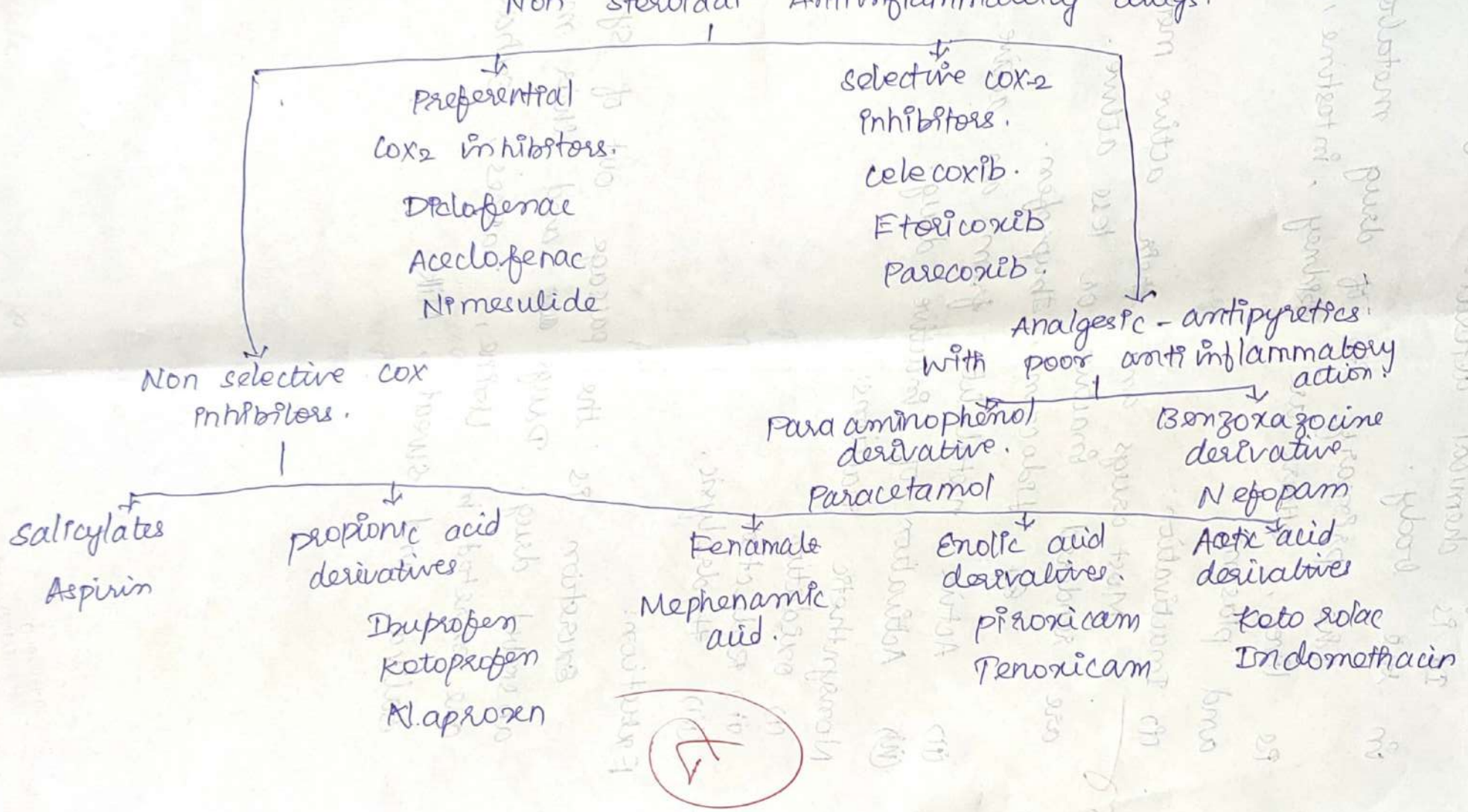

Oral Pathology

Answer Papers

Infant Nithin

20/8/22

29/5/22

1) Orofacial clefts :-

* A facial cleft results due to lack of fusion of facial embryonic processes.

* Occurence of cleft lip and cleft palate 50% of cleft lip and cleft palate

Pathogenesis :-

* Polygenic or multifactorial inheritance
* Monogenic or syndromic associated with variety of other congenital anomaly.

Certified

PRINCIPAL
SRI VENKATESWARA DENTAL COLLEGE & HOSPITAL
OFF. OMR NEAR - NAVALUR
THALAMBUR, CHENNAI-600 130.

Classification :-

* Veau's classification :-
  - Group I → Soft palate alone
  - Group II → Hard and soft palate
  - Soft palate extending to alveolus and lip
  - Group IV → Complete bilateral cleft.

Clinical features :-

* Isolated cleft palate is more common in females
* Cleft lip/palate is more common in males
* It creates a communication between the oral and nasal cavity, Patient feel difficulty in taking foods and drinks
* Breast feeding is difficult as babies cannot generate suction
* Usually retrusion of maxilla with narrow palatal arch.
* Deflection of nasal tip towards non cleft side and larger nares

Prognosis and predictive factors :-

* It is a team effort. The team consist of genetic counsel prosthodontist, plastic surgeon, orthodontist, paediatrician
* Surgical treatment includes primary lip closure, which the rule of 10.
  - 10 pounds of weight
  - 10 weeks of age
  - 10 gm/dl of Hb.

2) Developmental disturbances affecting structure of teeth.

Amelogenesis imperfecta

* It is a group of hereditary defect and an ectodermal disorder
* It has 3 types:-
  - Hypoplastic
  - Hypocalcified
  - Hypomaturation

Clinical features :-

* Pitted pattern, which undergo staining
* Enamel surface is thin, glossy and without thickness
* Teeth will be opaque white or translucent.
* In enamel agenesis, total lack of enamel formation.

Certified

PRINCIPAL
SRI VENKATESWARA DENTAL COLLEGE & HOSPITAL
OFF. OMR NEAR - NAVALUR
THALAMBUR, CHENNAI-600 130

Dentinogenesis imperfecta :-

* It is a developmental disturbance of dentin.
* The gene affected is DSPP code.
* Teeth will be opalescent.

Classification :-

Type 1 → Dentinogenesis imperfecta only
Type 2 → Dentinogenesis imperfecta with osteogenesis imperfecta
Type 3 → Seen as racial isolate in maryland.

Histopathology :-

* Enamel appears normal.
* Dentin has irregular tubules, with uncalcified matrix
* The pulp chamber is obliterated

3) Radicular cyst :-

* It is a common inflammatory cysts and arise from epithelial residue in the periodontal ligament.

Pathogenesis :-

- Phase of initiation
- Phase of cyst formation
- Phase of cyst enlargement.

Clinical features :-

* Age :- 40 - 50 years
* No gender prediction

Certified

PRINCIPAL
SRI VENKATESWARA DENTAL COLLEGE & HOSPITAL
OFF. OMR NEAR - NAVALUR
THALAMBUR, CHENNAI-600 130.

* Location:- Maxillary anterior region.
* Asymptomatic
* Slow growing swelling
* Bone becomes very thin despite subperiosteal bone deposition causing egg shell appearance.
* Pain is due to secondary infection
* vitality test elicit negative.

Radiographic features:-

* The lesion is 10-14 mm is granuloma, more than 15 mm is cyst.
* Well defined, round shaped radiolucency
* Root resorption is seen.

Histopathology

* The cystic fluid contents are usually brown due to breakdown of blood.
* Lined by squamous stratified epithelium
* Cholestrol clefts are seen.
* Connective tissue has dense inflammatory cell infiltration
* Rushton's hyaline bodies is seen.

Differential diagnosis

* Periapical granuloma
  Periapical abscess.

Actinomycosis:-

* It is a chronic granulomatous suppurative fibrosing infection.
* It is mostly caused by A. israelii



Clinical features

* Age :- 35 - 50 years
* Sex :- Both sexes are affected
* Symptoms occurs 2 - 10 days after initial contact
* site :- Jaw bones, upper neck.
* wooden indurated area of fibrosis
* Skin appears bluish red.
* Tonsillar affect is affected.
* Trismus is seen.
* Periapical abscess and granulomas can be seen.
* It does not spread to lymph nodes.
* Painful swelling of salivary glands.

Histopathology :-

* Exhibit chronic suppurative inflammation in affected tissue with numerous abscesses.
* centerally placed bacterial colonies
* surrounded by PMN's and mononuclear cells.

Diagnosis

* Bacterial culture, Immunofluorescence test

Treatment :-

* High dose of antibiotics

5) candidiasis :-

* It is the most common mycotic infection.
* It is caused by candida albicans.

Pathogenesis :-

* Tissue invasion or by inducing hypersensitivity reaction

clinical features

* acute or chronic
* Mostly superficial
* Smooth, thick creamy
* white or yellow.

Types :-

* Acute pseudomembranous candidiasis
* Acute atrophic candidiasis
* Chronic atrophic candidiasis
* Angular cheilitis
* Chronic hyperplastic candidiasis
* Mucocutaneous candidiasis
* Syndrome associated candidiasis

Histopathology :-

* candidal hyphae invasion into superficial layer.
* Hyperplastic epithelium exhibit superficial necrotic and desquamating parakeratinized layer with candidal hyphae.

Differential diagnosis :-

* chemical burns
* Leukoplakia
* Lichen planus.

Treatment :-

* Amphotericin B
* Fluconazole.

6) Oral manifestations of HIV :-

* Fungal infections :-
  * candidiasis
  * Angular cheilitis
  * Esophageal candidiasis
* Viral infection
  - Herpes simplex
  - Herpes zoster
  - Epstein Barr virus
  - Papilloma
  - cytomegalovirus virus
* Bacterial infection :-
  - Tuberculous ulcers
  - Osteomyelitis of jaw.
  - cellulitis.
* Deep fungal infections :-
  - Toxoplasmosis
  - Histoplasmosis

* Tumors
  - Kaposi's sarcoma
  - Burkitt's lymphoma
  - Squamous cell carcinoma
* Stomatitis :-
  - Recurrent major aphthous ulcers
  - Atypical oropharyngeal ulcers.
* Salivary gland disease :-
  - Sjogren's disease
  - Parotitis
  - Lymphoepithelial lesions
* Neurological disorders :-
  - Facial palsy
  - Trigeminal neuropathy

7) Verrucous carcinoma :-

* It is also called as snuff dipper's cancer
* Low grade variant of squamous cell carcinoma

Clinical features :-

* Diffuse
* Well demarcated
* Painless thick plaque
* Exophytic
* Has pebbly surface.

Histopathology :-

* It has thick parakeratin
* It has minimal dysplasia
* It has increased spinous layer → acanthosis
* It has broad bulbous rete pegs
* It has thick connective tissue
* wide, elongated rete ridges appears to push into underlying connective tissue called pushing margins of ackerman

Treatment :-

* Surgical excision

8) Pyogenic granuloma.

* common tumor like growth.
* Non neoplastic

Clinical features :-

* Elevated, pedunculated or sessile
* vascular mass with smooth lobulated surface.
* May be unilateral or bilateral
* Pus, purulent membrane.
* Pink to red or purple
* painless
* Soft
* frequent in pregnant women

Histopathology :-

* Densely collagenized
* Hypovascular connective tissue
* Sub epithelial vesicles.

Treatment :-

* Intralesional injection of interferon D.
* Vitamin C.

10) Gustafson's method of age estimation :-

A - Attrition
S - Secondary dentin deposition
P - Apical migration of PDL attachment
C - Cementum apposition
R - Root resorption
T - Dentin translucency

* Gustafson's assigned four grades 0 to 3.
* The formula is $[A3 + S2 + P2 + C1 + R2 + T1 = X]$
* Later researchers discovered statical errors and modified the grades to 0, 0.5, 1, 1.5, 2, 2.5, 3.
* The formula is

$$(5.14 \times A) + (2.3 \times S) + (4.14 \times P) + (3.71 \times C) + (5.57 \times R) + (8.98 \times T)$$

20.8.2022.

Oral Pathology.

S. Janani Kesthana

32/50

① Orofacial clefts :-

* A facial cleft results because of the lack of fusion of facial embryonic process.

* Orofacial clefts are also known as cleft lip + cleft + cleft palate.

* Cleft palate + cleft lip is classified into three types / groups
  - → Group 1 : cleft of lip or alveolus
  - → Group 2 : cleft of secondary palate
  - → Group 3 : combined cleft of primary & secondary palates.

* Pathogenesis :-
  - Infections like German measles
  - Polygenic (or) multifactorial inheritance
  - Lack of developmental force.

* Clinical Features :-
  - It is more common in males.
  - Isolated cleft palate is common in females.
  - Maxillary anterior teeth is displaced or impacted in the case of cleft palate.
  - For babies, breast feeding will be difficult because of insufficient suction.
  - Difficulty in consumption of food & drinks due to the nasal regurgitation.

- Deflection of nasal tip towards the normal & larger naris on the cleft side.

Treatment:-

* It can be treated by multidisciplinary approach like:-
  - pedodontist
  - orthodontist
  - prosthodontist
  - Surgeon
  - Speech therapist
  - Genetic counsellor.

② Radicular cyst:-

* Radicular cyst is also known as periapical cyst.
* It is the most common inflammatory cyst as a result and arises from the epithelial residues in the periodontal ligament of a result of periapic periodontitis.

Pathogenesis:-

- Phase of initiation.
- Phase of cyst formation
- Phase of enlargement

Clinical features:-

* Age:- 40-50 yrs
* Gender is predilication
* Location:- Maxillary anterior region.

* Pain is due to secondary infection:-

* Pulpal floor of the deciduous teeth contains numerous accessory canals which intends to cause furcation involvement rather than periapical lesions:-

* Basically the lesion is about 10-15 mm is known as Granuloma.

* Loss of continuity of lamina dura of the involved tooth is frequently seen.

* Root resorptions may be seen in few lesions.

Differential diagnosis:-

* periapical Granuloma.
* central gaint cell granuloma
* periapical abscess.

Treatment:-

* Root canal treatment of the affected teeth if the attack age - small cyst.

* Marsupialization.

③ Actinomycosis :-

* Actinomycosis is the bacterial infection.
* It is caused by Actinomyces meyeri.
* Actinomycosis is characterized by chronic suppurative & granulomatous inflammation & the formation of multiple abscesses & sinus tracts that may discharge sulphur like granules.

clinical features :-



* It occurs in the age group of 20-50 yrs.
* Male predilection.
* There are three types of Actinomycosis
  - cervicofacial actinomycosis
  - Thoracic actinomycosis
  - Abdominal actinomycosis.
* The microorganisms that cause Actinomycosis are Filamentous, gram-positive, non-acid fast, anaerobic-to-microaerophilic bacteria.

Diagnosis :-

* culture of the tissue or fluid
* Examination of drained fluid under a microscope shows sulphur granules & the Actinomyces species of bacteria.

infection.

Treatment:-

* Surgical Drainage.
* Removal of lesion

(3) Developmental disturbances affecting structure of teeth.

* Amelogenesis Imperfecta
* Dentinogenesis Imperfecta
* Dentin Dysplasia.
* Regional odontodysplasia.

Amelogenesis Imperfecta:-

Amelogenesis Imperfecta is of 3 types.

Type I - Generalized or localised pitted pattern, Pinpoint pits are present which undergo staining.

Type II - Teeth in shape but enamel is much softer.

Type III - The teeth are shaped normally but after a period of function the enamel is lost.

Dentinogenesis Imperfecta:-

Type I - Dentinogenesis without osteogenesis imperfecta.

Type II - Dentinogenesis imperfecta with osteogenesis imperfecta.

Dentin Dysplasia.

Type I - Radicular dentin dysplasia.

Type II - coronal dentin dysplasia.

④ Pyogenic Granuloma:-

*

Regional odontodysplasia:-

Enamel + dentin appear fusing, no contrast between them radiographically ghost teeth appearance.

⑤ Oral candidiasis :-

* Oral candidiasis is caused by candida albicans which causes thrush when the host immunity or normal flora is disrupted.

* It is an oppurtunistic infection.

* IgA present in saliva affects adherance of candida to oral mucosa.

* The predisposing factors are:-

→ Radiation
→ Chronic illness
→ Smokers
→ Old age
→ Systemic diseases
→ Pregnancy
→ Immunosuppressive deficiency
→ Denture wears.
→ Nutritional deficiency.

* The types are:- → chronic hyperplastic
→ chronic atrophic
→ Erythematous
→ Secondary oral candidiasis

Gustafsons Method:-

* Gustafson's Method is a age estimation method.
* It is based on histological & morphological changes in tooth.

(A) Attrition
(S) Secondary dentin formation
(P) Loss of Periodontal support
(C) Cementum opposition at root
(R) Root resorption at apex
(T) Dentin translucency.

* The grades for these degenerative changes are from 0-3 (A_0, A_1, A_2, A_3)

$$x = A_0 + S_2 + P_1 + C_0 + R_2 + T_1$$

$\uparrow x = \uparrow$ age.

* For indian population. it is ± 8 years error
* For others it is ± 3 years error.
* This is due to the use of beetleaves & tobacco chewing.
* Johanson → 7 grade modification.

0, 0.5, 1, 1.5, 2, 2.5, 3.

$$\text{Age} = 11.02 + (5.14 \times A) + (2.3 \times S) + (4.4 \times P) + (8.12 \times C) + (5.57 \times R) + (8.8 \times T)$$

Increase in no. of teeth = Increase in accuracy.

⑦ Oral Submucous Fibrosis:-

* Oral Submucous fibrosis is a premalignant c
* It is caused by betel nut chewing (Areca n
* OSMF is usually more common in Southeast Asia
* It is characterised by inflammation & progressiv fibrosis of the submucosal tissues that results in trismus.

clinical features:-

* Burning sensation in early period of oral submucous fibrosis:-

~~Dryness of mouth~~
~~ulceration~~
~~Blisters~~
~~Excessive salivation~~

* Blisters
* ulcerations
* Excessive salivation
* Defective gustatory sensation
* Dryness of mouth.

* In OSMF, collagen hyalinized as smooth sheet.
* Total loss of epithelial rete pegs.
* Mild to moderate atypia is present.
* Extensive degeneration of muscle fibers evident.

Treatment:-

* It can be treated with dexamethasone hyaluronidase etc.

(8) Verrucous Carcinoma:-

* Verrucous carcinoma is a variant of squamous cell carcinoma.

* It is characterised by exophytic overgrowth of well-differentiated keratinizing epithelium has minimal atypia.

* The agegroup:- 60-70 years.

* Male predilection.

* Site of occurance:- Buccal Mucosa, gingiva, alveolar ridge & floor of the mouth.

* The lesions commonly has rugae-like folds with deep clefts between them.

* Pain during mastication

* Bleeding ulcer.

Treatment:-

* Radiotherapy is effective

* Chemotherapy can reduce the size temporarily.

20/8/22

Oral Pathology

36/50



V. Nivetha

1) Actinomycosis :-

→ It is a fungal infection > infection of filamentous bacteria > gram +ve anaerobic

→ Causative organism is actiomyces israeli.

* Clinical features :-

→ Superficial skin infection.

→ Acute, Progressing rapidly (or) chronic, slowly spreading lesion.

→ It may discharge large yellowish fluid that represents colonies of bacteria called sulphur granules.

→ Tonsillar hyperplasia occur.

→ Trauma, Periodontal infection, non vital tooth.

* Histopathological features :-

→ Colonies of filamentous bacteria

→ Collections of neutrophils surrounding the bacterial mass.

→ chronically inflammed granulation tissue surrounding large collection of PMN leukocytes.

→ Methanamine silver stain demonstrate the organism well.

⊕ Diagnosis:-

→ Sulfur granules injections demonstration.

→ fluoresent conjugated antiserum.

→ culture – 50% grow.

⊕ Treatment:-

→ Penicillin

→ Tetracyclin.

2) Oral submucous fibrosis:-

It is a chronic disease affecting any part of oral cavity.

⊕ Etiology:- unknown

Predisposing factor

→ Tobacco, betelnut, [redacted].

→ genetic factor

→ Autoimmunity.

→ Bacterial infection

→ collagen disorder.

Clinical features :-

Site :- Buccal mucosa, retromolar pad, soft palate, Palatal fauces, tongue, labial mucosa

Signs and symptoms :-

→ Burning sensation on eating spicy food.

→ Difficult in opening mouth.

→ Difficult in swallowing

→ Blisters on palate

→ Excessive salivation.

→ dryness of mouth.

→ ulceration

Stages :-

Stage - I - Stomatitis and vesiculation.

Stage - II - Fibrosis.

Stage - III - sequelence and complication.

Histopathological features :-

→ Atrophic oral epithelium

→ Loss of rete legs

→ Epithelial atypia may be seen.

→ Hyalinization of collagen bundles

Treatment :-

SREE MATESWARA DENTAL COLLEGE & RESEARCH INSTITUTE
THALAMBUR

→ Non-surgical therapy

→ Restriction of Habits and behavioural therapy.

→ Oral Physiotherapy.

→ Steroids

→ Hyaluronidase.

3) Pyogenic granuloma:-

→ Benign condition, highly vasular variant of capillary haemangioma.

→ Non neoplastic.

⊕ Pathogenesis:-

Inflammation
↓
differentiation and maturation.
↓
cells are widely separated
↓
little growth occur
↓
Pyogenic granuloma.

⊕ clinical features:-

Site:- gingiva, lip, tongue.

Signs and symptoms:-

→ Female are more susceptible

→ lesion appears on pregnancy women called Pregnancy tumor (or) granuloma gravidarum.

→ Maxillary gingiva involved more frequently

→ Painless & represent pedunculated (or) sessile rapid growth.

→ red purple colour.

→ soft, moist glistening surface, ulcerated.

⊕ Histopathological changes:-

→ epithelium is flattened, atrophic

→ ulcerated epithelium often covered with fibrinopurulent membrane.

→ Endothelial cells with vascular channels.

→ scattered mixed inflammatory cells.

→ Basic lesion is lobular hemangioma.

⊕ Differential diagnosis:-

→ Peripheral ossifying fibroma.

→ Peripheral giant cell granuloma.

→ well differentiated angiosarcoma.

⊕ Treatment:-

→ Remove the etiology

→ surgical excision of lesion.

VENKATESHWARA DENTAL COLLEGE
DEPT OF ORAL & MAXILLOFACIAL PATHOLOGY

4) Verrucous carcinoma :-

→ Variant of Squamous cell carcinoma

→ well differentiated keratinizing epithelium having minimal atypia.

⊕ Pathogenesis :-

→ chewing tobacco

→ Human Papilloma virus type 16 and 18

⊕ clinical features :-

Site :- Buccal mucosa, gingiva, alveolar ridge, palate and floor of mouth.

Signs and Symptoms :-

→ exophytic and appears Papillary in nature.

→ Rugae like fold with deep clefts

→ lesions on mandibular ridge into the overlying soft tissue and become fixed to the Periosteum.

→ Regional lymph nodes often harden and enlarges, stimulating metastatic tumor.

→ Pain and difficult in mastication, bleeding.

⊕ Histopathological features :-

→ epithelial proliferation

→ mitotic activity, Parakeratosis & hyperchromatism.

→ cleft like spaces lined by a Thick layer of Parakeratin.

→ Basement membrane is intact

→ chronic inflammatory infiltrate in the underlying The connective tissue.

⊕ Treatment:-

→ Surgical excision without radical neck dissection.

→ Radiotherapy

→ chemotherapy.

5) Candidiasis:-

→ It is caused by candida albicans.

→ most common fungal infection.

⊕ clinical features:-

(i) Pseudomembrous candidiasis:-

→ It is also called as oral Thrush.

→ Superficial infection of upper layer of oral mucosa.

→ Soft white, adherent patches on oral mucosa.

→ Painless.

→ Removed with little difficulty.

(ii). erythematous candidiasis:-

→ red macules, burning sensation in the Posterior hard Palate, buccal mucosa, dorsal tongue.

→ associated factor – xerostomia, antibiotic Therapy, idiopathic.

(iii) central papillary atrophy:-

→ red, atrophic mucosal area, asymptomatic.

→ occur in midline posterior dorsal tongue.

→ associated factor – immunosuppression, idiopathic.

(iv) chronic multifocal:-

→ red area often with removable white plaque, burning sensation.

(v) Angular cheilitis:-

→ red fissured lesion, irritated, raw feeling.

→ occur in angle of mouth

(vi) Denture Stomatitis:-

→ Red, asymptomatics

→ confined to palatal denture bearing area.

(vii) hyperplastic candidal leukoplakia:

→ white Plaque that are not removed.

(viii) Mucocutaneous candidiasis:-

→ white plaque, some of which is

removable, red areas.

→ occur in tongue, buccal mucosa.

VENKATESWARA DENTAL COLLEGE & HOSPITAL

⊕ Treatment:-

Antifungal therapy.

6) Radicular cyst:-

→ Also called as periapical cyst / Apical Periodontal cyst.

→ Source of injection — cell rest of malassez.

→ The apex of a nonvital tooth can be stimulated by inflammation to form a true epithelium lined cyst.

⊕ clinical features:-

(i) Periapical cyst:-

→ No symptoms unless acute inflammation occurs.

→ large cyst → swelling & mild sensitivity

→ Movement of adjacent teeth are possible.

Radiographs:-

→ cyst develops small periapical radiolucencies

→ loss of lamina dura.

(ii) Lateral radicular cyst:-

→ Appears as discrete radiolucencies lateral aspect of root.

→ loss of lamina dura

(iii) Residual Periapical cyst :-

→ Appears as a round to oval radiolucency within the alveolar ridge at site of previous tooth extraction.

→ as cyst ages, dystropic calcification and central luminal radiopacity occurs.

⊕ Histopathological features :-

→ lined by stratified squamous epithelium, Pseudostratified ~~squamous~~ ~~colour~~ columnar epithelium are also seen.

→ Rushton bodies are seen.

→ Arcading Pattern of epithelial cells

→ cholesterol cleft, giant cells of multinucleated foreign bodies are seen.

⊕ Treatment :-

→ extraction.

→ Non surgical endodontic therapy

→ Marsupialization

---

7) Gustafsons method of age estimation :-

The following 6 dental changes were studied for age estimation

(i) Attrition

(ii) Periodontitis.

(iii) secondary dentine

(iv) cementum apposition

(v) root resorption.

(vi) Transparency of root.

RAMESWARA DENTAL COLLEGE
DEPT OF ORAL & MAXILLOFACIAL PATHOLOGY

Attrition of teeth:-

Physiological wear and tear of occlusal surface of teeth due to mastication.

A_0 – No attrition, A_1 – Attrition in enamel, A_2 – Attrition reaches dentin, A_3 – Attrition in pulp.

Secondary dentin:-

Layer of dentin which is produced after the tooth root is completed.

S_1 – No formation of secondary dentin, S_2 – secondary dentin has start to begin in pulp.

S_3 – Pulp cavity has half filled with secondary dentin, S_4 – Pulp cavity fully filled with secondary dentin.

Periodontitis:-

Inflammation of Periodontal tissue Gingiva with age leading to loosening of tooth in socket.

P_0 – No Periodontitis, P_1 – Slight loosening of tooth.

P_2 – Periodontisis along upper 1/3rd of root, P_3 – Periodontisis along upper 2/3rd of root.

Cementum apposition:

deposition of cementum around the root of tooth.

C_0 – No deposition of cementum.

C_1 – Apposition greater than normal

C_2 – greater layer of cementum.

C_3 – very heavy layer of cementum

Root resorption:-

Root resorption is the progressive loss of dentin and cementum by the action of odontoclast.

R_0 – No resorption

R_1 – only small isolated spot of resorption.

R_2 – lower 1/3rd of root resorption

R_3 – greater area of resorption.

Transparency of root:-

with age the dentinal tubules are filled with minerals and turn opaque.

T_0 – No transparency.

T_1 – slight transparency

T_2 – Transparency over 1/3rd apical root

T_3 – Transparency over 2/3rd apical root

8) Orofacial cleft:-

It occurs due to lack of fusion of facial embryonic processes.

The orofacial clefts are cleft lip, cleft palate, combination of cleft lip, and cleft palate, median cleft upper lip, oblique facial cleft and lateral cleft lip.

SRI VENKATESWARA DENTAL COLLEGE & HOSPITAL
DEPT OF ORAL & MAXILLOFACIAL PATHOLOGY
THALAMBUR

⊕ **Pathogenesis:-**

→ congenital anomalies
→ infection like german measles
→ Alcohol, drugs, toxins
→ Emotional stress.

⊕ **classification:-**

group - I — defect of soft palate only
group - II — defect of hard and soft palate.
group III — defect of soft palate extending to alveolus and lip.
group IV — complete bilateral cleft.

⊕ **clinical features:-**

→ cleft palate common in females
→ cleft lip common in males
→ impacted teeth, supernumerary teeth
→ Pierre robin syndrome.
→ Treacher collins syndrome.

⊕ **Treatment and Prognosis:-**

→ It is a multidisciplinary approach

→ Surgical treatment of cleft lip

Rule 10

10 Pounds of weight.

10 weeks of age

10 g/dl of Hb.

9) Developmental disturbances of structure of tooth:

(i) Microdontia:-

This term is used to describe teeth without smaller than normal.

3 types:-

→ True generalized microdontia.

→ Retain generalized microdontia.

→ Microdontia involving a single tooth

(ii) Macrodontia:-

Teeth are larger than normal

3 types:-

→ True generalized

→ Relative generalized

→ Macrodontia involving a single teeth.

(iii) germination:-

which arises from an attempt at

division of single tooth germ by an incomplete constriction with resultant in complete formation of two teeth.

SRM DENTAL COLLEGE
DEPT OF ORAL MEDICINE & RADIOLOGY
THALAMBUR

(iv) Fusion:-

Fused tooth arises through union of two normally separated tooth germ.

(v) Concrescence:-

→ Teeth are united by cementum only

→ Most commonly seen in maxillary posterior.

(vi) Dilaceration:-

Refers to an angulation (or) a sharp bent in root of a teeth.

(vii) Talon's cusp:-

→ Talon's cusp is an anomalous structure resembling eagle's talons.

10) Oral manifestation of HIV:-

(i) candidiasis:-

→ most common oral manifestation of HIV.

(ii) Oral hairy leukoplakia:

→ white mucosal plaque that do not rub off -

→ It occurs on the lateral border of tongue.

(iii) Kaposi sarcoma :-

→ vascular endothelial neoplasm caused by human herpes virus 8.

→ single / multiple bluish swelling.

→ ocur in gingiva, hard palate, tongue.

→ pain, bleeding, necrosis are present.

(iv) Non Hodgkin lymphoma :-

→ malignancy of HIV infected individuals.

→ It involves extraoral site and CNS.

(v) HIV associated Periodontal disease :-

⊕ Linear gingival erythema :

→ linear band of erythema in free gingival margin.

⊕ Necrotising ulcerative gingivitis

⊕

(vi) less commonly affected are

⊕ mycobacterium infection.

⊕ Herpes simplex virus:-

It increases when CD4 cells count below 50 cells/mm³.

⊕ Human papilloma virus:

⊕ Hyperpigmentation:-

Hyperpigmentation is seen in skin, nail, mucosa.

Other lesion:-

→ Apthous ulceration
→ Histoplasmosis
→ Mollascum contagiosum.

SRI VENKATESWARA DENTAL COLLEGE & HOSPITAL
DEPT OF ORAL & MAXILLOFACIAL PATHOLOGY
THALAMBUR

25/50

Name :- Abinisha A

year :- BDS III year

Date :- 20.08.2022

Roll No :- 05

1) Orofacial clefts:

Disturbance in growth of tissue processes or their fusion may result in formation of orofacial clefts.

The primary palate also is formed by merger of medial nasal processes to form intermaxillary segment.

this segment gives rises to premaxilla, a triangular shaped piece of bone that will include four incisor teeth.

Clinical features & Radiographic features.

The minimal manifestations of clept palate is bifid uvula.

In some instances a submucous palatal cleft develops.

Malocclusion occurs.

Airway obstruction.

posterior displacement of tongue

Treatment:

Oral and maxillofacial surgeon.

Orthodontist.

Speech pathologist.

2) Developmental disturbance of structures of tooth.

Amelogenesis imperfecta alternations in structure of enamel in a absence of systemic disorder / syndrome.

Stages:-

(1) Elaboration of organic matrix

(2) Mineralisation of matrix

(3) Maturation of enamel.

Clinical and Radiographic features:

It may be inherited as an autosomal dominant, autosomal recessive or X linked disorder.

Yellow or brown discoloration.

It associated with dental caries, tooth wear, cracking and chipping.

Treatment:

Bonding

Full crown restoration.

3) Radicular Cyst.

It is also known as periapical cyst.

The source of epithelium is usually a rest of malas

periapical pocket cysts are characterised by an incomplete epithelial lining because of extension of the apical portion.

periapical true cyst form complete epithelium lined bag like structure.

Clinical features:

No symptoms

Swelling & mild sensitivity

Mobility of adjacent teeth.

If doesn't respond to thermal & electrical pulp tests

Loss of lamina dura.

Root resorption.

Histologic features

It is lined by stratified squamous epithelium

Scattered mucosa.

Treatment:

Extraction

Conservative non surgical endodontic therapy.

~~Treatment~~: Actinomycosis :

It is an fungal infection

Normal saprophytic components of oral flora

Actinomyces Israelii is causative organism.

Clinical features:

Acute (or) rapidly progressing infection or a chronic, slowly spreading lesion that is associated with fibrosis.

Infection may discharge large yellowish flecks that represents colonies of bacteria called sulfur granules.

Submandibular, submental & cheeks are common areas

Histologic features.

Large collection of PMNs, leukocytes, colonies of organism.

Club shaped filaments.

Treatment:

Antibiotics.

Abscess discharge.

(5) Candidiasis.

Older name - moniliasis

Three general factors.

(i) The immune status of host.

(ii) The oral mucosal environment.

(iii) The strain of C. albicans.

Clinical features

Pseudomembranous - creamy white plaques.

Erythematous - Red macule, burning sensation

Angular cheilitis - Red, fissured lesions, irritated raw feeling.

Hyperplastic - white plaque, not removable.

Histopathologic Features.

On staining with (PAS) method, candidiasis hyphae and yeas can be readily identified.

It appears Bright magenta.

Treatment:

Antifungal medications.

⑥ Oral manifestations of HIV.

Hairy leukoplakia.
Kaposi sarcoma.
Non Hodgkin lymphoma
Recurrent aphthous stomatitis
Drug reactions Ulcerative
Cat Scraten disease.
Necrotising ulcerative stomatitis
Viral infections - cytomegalovirus.
Fungal infections - cryptococcus neoformans.
Aspergilus flavus.

⑦ Verrucous carcinoma.

It is a low grade variant of oral squamous cell carcinoma.

Lesions associated with smokeless associated with smokeless tobacco.

Tabacco chewers.

Extraoral sites - laryngeal, vulvovaginal, perile, Sole of of the foef.

people who we chewing tabacco & stuff-

Clinical features.

SRI VENKATESWARA DENTAL COLLEGE & HOSPITAL
DEPT OF ORAL & MAXILLOFACIAL PATHOLOGY
THALAMBUR

It is found predominantly in men older than 55 years.

Common site : Mandibular vestibule
Buccal mucosa.
gingiva
tongue.

painless, thick plaque with papillary

It appears in white / pink

which depends on the amount of keratin

Leukoplakia / tobacco pouch keratosis may seen.

Histopathologic features

It has wide and elongated rete ridge appears to push paraKeratin cleft.

Treatment :-

Surgical excision.

(8) Pyogenic Granuloma :-

Non neoplastic in nature

It is caused by pyogenic organisms

Clinical Features :-

It is smooth or lobulated mass that is usually pedunculated.

Some lesions are sessile

Colour pink to red to purple.

Highly vascular in appearance during young older lesions have more collagenized & pink.

Mass is painless, often bleed easily

It exhibits rapid growth

Gingival Irritation.

Histopathologic features

It shows highly vascular

These vessels sometimes are organised in lobular aggregates, Hence the term lobular capillary hemangioma

The surface usually ulcerated and replaced by thick fibrinopurulent membrane.

Treatment :-

surgical Excision.

(9) Oral submucous fibrosis

It is high risk, precancerous condition characterised by chronic, progressive scarring of oral mucosa.

The incidence of oral submucosa fibrosis has been increasing especially among young persons due to the growing popularity of commercially freeze dried betel quid substitutes.

clinical features

Inability to open mouth

Generalised oral burning sensation

Signs - vesicles, petechiae, melanosis, xerostomia

Site - Buccal mucosa, retromolar area & soft palate

Leukoplakia of surface mucosa often

Betel chewer mucosa.

Histologic features

It is characterised by juxtaepithelial and submucosal deposition of densely organised.

Treatment:

Corticosteroids
Surgical splitting
Physiotherapy.



(10) Gustafson Age Estimation:-

Gustafson method of age determination from teeth is based on evaluation of ground sections of teeth.

Attrition
Periodontitis
Secondary dentin
Cementum apposition
Root Resorption
Transparency of root.

20/8/22.

Oral pathology. B. Roshini Devi

Roll. No.

30/50

1) Oro-facial clefts.

Cleft palate:

→ lack of fusion of palatal shelves

→ Abnormalities in programmed cell death may contribute to lack of palatal fusion.

→ Isolated disruption of palate shelves can occur after closure of the lip.

→ palatal closure is not completed until 9 weeks post-conception.

Causes:

→ environmental + genetic factors

positive family history in 26 % cases

→ known Teratogens:

eg: phenytoin, methotrexate, sodium valproate.

Cleft lip:

→ cleft lip refers to open space between lip especially in part of vermilion line or failure in fusion of lip.

→ Also known as hare lip

2) Developmental disturbances of structure of teeth.

1) Microdontia:

→ this term is used to describe teeth which are smaller than normal.

→ 3 types.

- True generalized microdontia
- Relative generalized microdontia
- Microdontia involving a single tooth.

2) Macrodontia:

→ teeth are larger than normal

→ 3 types:

- True generalized
- Relative generalized
- Macrodontia involving a single teeth.

3) Gemination:

which arises from an attempt at division of single tooth germ by an invagination, with resultant incomplete formation of two teeth.

4) Fusion:

→ Fused teeth arise through union of two normally separated tooth germ.

5) Concrescence:

→ Teeth are united by the cementum only

→ Most commonly seen in maxillary posterior

6) Dilaceration:

→ Refers to an Angulation or a sharp bend in root of a teeth.

2) Talon's cusp:

Talon cusp is an anomalous structure resembling eagles talon.

3) Radicular cyst:

→ Inflammatory odontogenic cyst.
→ Also called radicular cyst, apical periodontal cyst, root end cyst or ~~dental~~ cyst.
→ Arises from rests of Malassez cells.

Sites:

→ Maxilla commonly seen than mandible.
→ Mostly in apex of lateral incisors & canine along lateral accessory root canals.

Clinical features:

→ possible swelling.
→ May be painful.

Radiographic:

→ Round to oval radiolucency, often with well defined cortical border.

Treatment:

Surgical excision.

4) Actinomycosis:

5)

Causative organism: Actinomyces israelii or A. gerencseriae

Signs & symptoms:

→ The disease is characterised by the formation of painful abscesses in mouth, lungs & GIT.

→ the abscess often called as sulfur granules due to their yellow appearance.

Causes:

- Radiation therapy.
- poor dental work.
- poor oral hygiene.
- periodontal disease.

Diagnosis:

- MRI
- immuno assays.

Treatment:

→ penicillin.
→ doxycycline
→ sulfonamides.

5) Candidiasis:

Causative organism: Candida albi



Classification:

- Pseudomembranous.
- Erythematous.
- Hyperplastic Candidiasis.
- Candida associated lesions

Signs & Symptoms:

→ Burning mouth syndrome.

→ Acute atrophic Candidiasis may feel like the mouth has been scalded with a hot liquid.

→ Another potential Symptom is a metallic, acidic, Salty or bitter taste in the mouth.

→ Pseudomembranous type rarely causes any Symptoms apart from possibly some discomfort or bad taste due to the presence of the membranes

→ occasionally dysphagia.

Differential diagnosis:

- Lichen planus.
- Leukoplakia.

Treatment:

→ nystatin

→ Miconazole.

→ Amphotericin B

6) Oral Manifestations of HIV:

Signs & Symptoms:

→ Night sweats, weight loss.
→ chills or fever Lower than 100°F
→ Cough & shortness of breath, Skin rashes.

Group - 1:

Candidiasis.
Oral hairy leukoplakia.
Kaposi Sarcoma.
Non-Hodgkin lymphoma.

Group-2:

Bacterial infections.
Melanotic hyperpigmentation.
Necrotising ulcerative stomatitis.
Xerostomia.
HSV
HPV.

Group-3:

→ Drug Rxn.
→ Epithelioid angiomatis
→ Cryptococcus neoformans
→ H. capsulatum.
→ Facial palsy.
→ Trigeminal neuralgia.
→ Recurrent aphthous ulcer.

f) Verrucous Carcinoma:

Variant of squamous cell carcinoma characterised by a predominantly exophytic overgrowth of well-differentiated keratinizing epithelium having minimal atypia

CF:

Age: 60-70 yrs.

Sex: Male.

Site: Buccal mucosa, gingiva, alveolar ridge, palate floor of the mouth.

Signs & Symptoms:

→ Exophytic & appears papillary in nature, pebbly surface covered by white leukoplakia film.

→ Rugae-like folds with deep clefts.

→ Lesions on mandibular ridge invade the overlying soft tissue & fixed into the periosteum.

H/P:

→ little mitotic activity.

→ epithelial proliferation, with downgrowth of epithelium into connective tissue.

→ cleft-like spaces lined by a thick layer of parakeratin

→ Basement membrane is intact.

→ Chronic inflammatory cell infiltrate in the underlying connective tissue may be not present.

Treatment:

→ Surgical excision.

→ Radiotherapy

→ Chemotherapy.

8) Pyogenic granuloma.

→ Also called as lobular capillary hemangioma
→ Most common in females.

Signs & Symptoms:

→ red, pink to purple, grows rapidly, smooth or mushroom shaped.

→ Epulis granulomatosum is a variant of pyogenic granuloma that forms only on gingiva. It is often seen forming in a recent extraction socket.

→ Most often seen in Mandibular jaw.

→ Ulcerations.

Management:

Curettage.

Electrodessication.

beta-adrenergic antagonist timolol.

Scaling & root planing.

1) OSMF

→ Oral Submucous fibrosis.

→ Characterised by juxta-epithelial inflammatory reaction & progressive fibrosis of the submucosal tissues. As the disease progresses, the oral mucosa becomes fibrotic to the point that the person is unable to open the mouth.

→ Areca nut & its by products are major cause.

SRI VENKATESWARA DENTAL COLLEGE & HOSPITAL
DEPT OF ORAL & MAXILLOFACIAL PATHOLOGY

Symptoms:

→ Xerostomia.
→ Recurrent ulceration.
→ Pain in ear.
→ Depigmentation of the oral mucosa.
→ Dryness & burning sensation of mouth.

Causes:

Immunological diseases
Extreme climatic conditions.
prolonged deficiency to Fe & vits in the diet.

Treatment:

→ Reversal of the habit.
→ A, B Complex & C Vitamin & Fe.
→ Hydrocortisone.

10) Gustafson's age estimation

Gustafson's method for age determination from teeth is based on the evaluation of ground sections of teeth. Six age-associated parameters are evaluated in the ground section & are compared to a regression curve of age versus the age-associated changes. Two of these changes, transparency of radicular dentin & secondary dentin have the highest correlation with age. The evaluation of these parameters only from thin (0.25mm) ground sections may lead to an artificially high secondary dentin value. The evaluation of these parameters only from thin ground sections & by an accidental overgrinding of the apical area of the root. These

20/8/22 Oral pathology 35/50 R. Pavithra Lakshmi

59

① Orofacial clefts :-

→ A facial cleft results due to lack of fusion of facial embryonic processis

SAVEETHA DENTAL COLLEGE & HOSPITAL
DEPT OF ORAL & MAXILLOFACIAL PATHOLOGY
SAVEETHA NAGAR * THANDALAM

→ There are cleft lip, cleft palate, the combination of cleft lip & palate, median cleft of upper lip, oblique facial cleft & lateral facial cleft.

Pathogenesis :-

> polygenic / multifactorial inheritance.
> Infections like German measles.
> Lack of developmental force.

Classification

> Group I :- It is a defect of soft palate alone.
> Group II :- It is a defect of hard palate & soft palate.
> Group III :- It is a defect of soft palate extending to alveolus & lip.
> Group-IV :- complete bilateral cleft.

Clinical features :-

* Isolated cleft palate is more common in females
* Cleft lip/palate is more common in males.
* Breast feeding is very difficult as babies cannot generate sufficient suction.

Prognosis / predictive factors

* It is a team effort.
* Surgical treatment includes primary lip closure which is done by the rule of 10 for child.
- 10 pounds of weight
- 10 weeks of age
- 10 g/dl of haemoglobin.

(2.) Developmental disturbance of structure of tooth.

→ Amelogenesis imperfecta :-

It is a group of hereditary defect enamel with any other generalized defect or systemic disorder. It is ectodermal disorder.

Classification :-

Type I :- Hypoplastic

Type 2 :- Hypomaturation.

Type III :- Hypocalcified

Type IV :- Hypomaturation.

Clinical features :-

Type I :- * generalized / localized pitted pattern.
* pinpoints are undergo staining.

Type II :- The teeth are normal in shape but the enamel is much softer

Type III :- the teeth are shaped normally but after a period of function the enamel is lost.

Radiographic features.
* enamel may be completely absent.
* If present, it appears as a thin layer over the cusp tips & interproximal areas.

Histopathology :-
* Hypoplasia :- Matrix formation is defective.
* Hypocalcification :- Improper mineralization.
* Hypomaturation :- Alteration in the enamel rod & sheath structure.

Prognosis & predictive factors :-
* Improve the cosmetic appearance by full crown veneer.
* Full denture can be provided in cases of enamel agenesis.

Dentinogenesis Imperfecta :-

* It is the hereditary developmental disturbances of dentin.

Classification :- Shield's classification :-

- Dentinogenesis Imperfecta type 1 :- Dentinogenesis imperfecta without osteogenesis imperfecta
- Dentinogenesis imperfecta type 2 :- Dentinogenesis imperfecta with osteogenesis imperfecta
- Dentinogenesis imperfecta type 3 :- This is seen as racial isolate in Maryland & it is called Brandywine type.

Histopathology :-

* Enamel appears as normal.
* Dentin is composed of irregular tubules.
* Dentin may contain few no. of tubules.

Prognosis :-

* It is directed primarily towards preventing the loss of enamel & subsequent loss of dentin through attrition.

(3) Radicular cyst :-

> It is the most common inflammatory cyst & arise from epithelial remains in PDL as a result of periapical periodontitis following death / necrosis of pulp.

> It is also called as residual cyst.

Pathogenesis :-

1. phase of initiation
2. phase of cyst formation.
3. phase of cyst enlargement.

Clinical features :-

Age :- 40 - 50 years.

Gender :- No gender predilection.

Location :- Maxillary anterior region.

Radiographic features :-

> lesion -> 10-14 mm is granuloma,

> well defined, round / ovoid - shaped radiolucency with thin sclerotic border.

> Loss of continuity of lamina dura.

Histopathology :-

> Cyst fluid content are usually brown due to breakdown of blood.

> they are lined by stratified squamous epithelium.

> Cholestral cleft are present which is moon shaped.

> Arcading pattern are seen.

diagnosis :-

> periapical granuloma.

> Central giant cell granuloma.

> periapical abscess.

Actinomycosis:

-> lesion is caused by Actinomyces israelli
-> It is characterized by chronic Suppurative & granulomatous inflammation & formation of multiple abscess & Sinus tracts that may discharge Sulphur like granules.

Clinical features:

Age: 20-50 years
Sex: Male predilection.

Pathogenesis:-

> It enter the facial tissue after trauma, Surgery / infections

> It produce bacteria by elaborating toxins / enzyme.

It has:-
- Cervicofacial actinomycosis
- Thoracic actinomycosis
- Abdominal actinomycosis

Histopathological features:-

> It shows granulomatous with central abscess formation.

> lesions appear to floating in a sea

> tissue surrounding the lesion exhibits fibrosis

Diagnosis -> Culture of tissue / fluid.
-> Examination of drained fluid.

(5) Candiadisis :- :

It is caused by yeast like fungus called Candide.

Microorganisms :-

→ Candida albicans

→ exis forms → pseudohypae, yeast, chlamydia

Classification :-

- Acute → pseudo membranous oral candidiasis
  Erythromatous candidiasis
- chronic → hyperplastic
  → chronic atrophic.

Clinical features :-

→ common form → Acute pseudomemembranous
→ also called as oral thrush

(6) Verrucous Carcinoma :-

It is a warty variant of squamous cell carcinoma characterized by a predominately exophytic overgrowth of well differentiated keratinizing epithelium having minimal atypia.

Clinical features :-

Age :- 60-70 years -
Gender :- male
Location :- Buccal mucosa, gingival, alveolar ridge, palate, floor of mouth.

Sign & Symptoms :-
→ lesion - sugar like folds with deep cleft, palate & floor.
→ pain & difficult in mastication.

Histopathological features

→ bulbulous parakeratin : plugging.
→ pleomorphism
→ cleft like spaces are present.

(7.) Oral manifestation of HIV :-

Group 1 :- lesion strongly associated with HIV.
→ candidiasis
→ Hairy leukoplakia.
→ Angular cheilitis
→ Kaposi Sarcoma,
→ periodontal disease.

Group : 2 :- Lesion less commonly associated with HIV
→ Mycobacterium tuberculosis.
→ thrombocytopenic purpura.
→ Oral Ulceration.

Group : 3 :- lesion associated with HIV.
→ Delayed wound healing.
→ Bacterial infection - actinomycosis.
→ Fungal infection → candidiasis.
→ Viral infection → cytomegalovirus infection.

(10)

Pyogenic granuloma :-

It is a pedunculated, hemorrhagic nodule having a tendency to develop on the gingiva.

Etiology :-

-> Chronic irritation.

-> Local factors - calculus, food impaction.

-> Hormonal changes.

Clinical features :-

-> friable.

-> Heamorhagic

-> frequently ulcerated.

Treatment :-

- Surgical excision.

20/8/22

Oral Pathology

28/50

Snehara. SJ

1. Actinomycosis:

Fungal infection, infection of filamentous, branching, gram +ve anaerobic.

colonies within tonsillar crypts may form, become large enough for patient to feel from plugs

causative organism: Actinomyces israeli



clinical features

Acute, rapidly progressing infection

slowly spreading lesion

superficial skin infection

suppurative rxn of infection - may release large yellowish discharge sulfar granules

Tonisllas hyperplasia occurs.

Trauma, periodontal infections, non-vital tooth.

Histopathological feature:

colonies of filamentous Bacteria

Neutrophils: collection of neutrophils surrounding the bacterial mass.

inflammed granulation tissue.

Methenamine silver stain demonstrate the organism.

SRI VENKATESWARA DENTAL COLLEGE & HOSPITAL
DEPT OF ORAL & MAXILLOFACIAL PATHOLOGY
THALAMBUR

Diagnosis:
culture gram -50%
sulfur granules
fluorescent conjugated antiserum

Treatment:
Penicillin
Tetracycline

2. Orofacial clefts:

cleft lip & palate:

Etiology:
lack of developmental force.
infection like german measles.
alcohol, drugs, toxin

clinical features:
Sex: Female ⇒ more of isolated cleft palate.
generally more common in males.
Cleft palate creates a communication between the oral and nasal cavities, patient often feels difficulty in taking foods.
difficulty in breast feeding
Anterior teeth may be dis placed. deformed, impacted.
Retrusion of maxilla anteriors with narrow palatal arch is seen.

Pierre Robin
Treacher col
Symptoms
Post
Air
Treatment and
Place
Rule

3. Periapical
Also kn
the ap
stimulated
epithelium
Rest
St
by epitheli
clinical fea
No symp
large
Movem
Radiographi
small
Loss
Radio

Pierre Robin syndrome
Treacher collins syndrome
Symptoms in Pierre Robin syndrome
Posterior displacement of tongue.
Airway obstruction.

Treatment and prognosis:
Placement of nasopharyngeal airway done.
Rule of 10 for child
10 pounds of weight
10 weeks of age
10 g/dl of Hb.

Periapical cyst:
Also known as Radicular cyst.
The apex of the non vital tooth can be stimulated by inflammation to form a true epithelium lined cyst.

Rest of Malassez ⇒ source.
It is a fibrous connective tissue lined by epithelium.

clinical features:
No symptoms unless Acute inflammation occurs.
large cyst ⇒ swelling & mild sensitivity.
Movement of adjacent teeth are possible.

Radiographic features:
small Periapical Radiolucency
Loss of Lamina dura.
Radiolucency encircles the affected tooth apex.

Histological features:

6-8 layers of cystic lining.

Rushton Bodies → large eosinophilic

Arcading pattern

Cholesterol cleft

Multinucleated giant cells.

Treatment:

surgical excision

4. Candidiasis:

caused by candida albicans.

Most common oral fungal infection

5 determinant factors

immune status of host

oral mucosal environment

stains of C. albicans.

Mild to superficial mucosal involvement is seen.

clinical features:

Pseudomembranous candidiasis:

only scrappable.

Infants: 6th to 10th day after birth

infection from maternal vaginal canal.

Soft white / bluish white

painless.

Adult:

symptoms: Rapid onset of bad taste

& discomfort from spicy food.

	Appearance	common sites
Pseudo membranous [thrush]	creamy white plaque Burning sensatn.	Buccal mucosa, tongue, palate, posterior nasal palate.
Erythematous	Red macules, Burning sensatn.	post. palate. post. dorsal tongue angles of mouth
chronic multi focal	Red areas, often with removal white plaque.	
Angular chelitis	Red, fissured lesion irrited	Angle of mouth.
Denture stomatitis	Red, asymptomatic	confined to palate, denture bearing mucosa.

Diagnosis:

can be scrapped off.

D.D Lichen planus

chemical burn, leukoplakia.

5. Verrucous carcinoma:

Also known as snuff Dipper's cancer (or) Ackerman's tumor.

varient of squamous cell carcinoma.

Predominantly exophytic overgrowth of well differentiated keratinizing epithelium having minimal atypia.

pathogenesis: unknown.

chewing tobacco, HPV typ 16 & 18

clinical features:

Age: 60-70yrs.

Sex: Male predilection

site: Buccal Mucosa, gingiva, alveolar ridge, palate, floor of mouth.

SRI VENKATESWARA DENTAL COLLEGE & HOSPITAL
DEPT OF ORAL & MAXILLOFACIAL PATHOLOGY
THAL

Histological D. features:

Signs & symptoms:

Exophytic & appear papillary in nature, pebbly surface covered by white leukoplakic film.

Rugae like folds with deep clefts.

lesion on mandibular ridges into the overly soft tissue & become fixed to the periosteum.

Regional lymph nodes often tender & enlarge, simulating metastatic tumor.

pain & difficulty in mastication, bleeding.

Histopathological features:

Epithelial proliferation with down growth of epithelium into connective tissue.

little mitotic activity, pleomorphism (or) hyperchromatism.

cleft like spaces lined by a thick layer of parakeratin.

Basement membrane is intact.

chronic inflammatory cells infiltration

Treatment:

surgical excision without radical neck dissection.

Radiotherapy

chemotherapy

6. Pyogenic granuloma:

It is not associated with pus and does not represent granuloma histologically.

variant of capillary haemangioma.

Predisposing factor:

idiopathic, trauma

poor oral hygiene.

linical features:

Young adult.
Female predilection
gingiva, lips, tongue & buccal mucosa.

Signs & symptoms:

Female is more prone becoz of hormonal changes during puberty, pregnancy, menopause.

Pregnancy tumour & granuloma gravidarum.

Maxillary gingiva is involved more.

painless & sessile & pedunculated (or) sessile

rapid growth.

Red - purple colour

soft, moist, glistening surface, ulcerated

vascularity ↓es, more collagenous & rubbery in consistency.

H/F: Epithelium is flattened, atrophic & acanthotic

Basic lesion is lobular haemangioma.

endothelial cells with vascular channels.

inflammatory cells.

Treatment: Remove the etiology

surgical excision of the lesion.

7. Oral Submucous fibrosis:

Etiology: chillies, lime, tobacco, betel nut.

genetic factors

Autoimmunity.

defective iron metabolism

collagen disorders.

Clinical features:

20-40yrs.

No sex predilection

Buccal mucosa, retromolar area, soft palate, uvula, tongue, labial mucosa, floor of mouth, gingiva

Signs & symptoms:

Initial symptoms	Later
* Burning sensation on eating spicy food.	* difficulty in opening mouth.
* Blister on palate.	* Inability to whistle blow.
* Ulceration	* Difficulty in swallowing
* Excessive salivation	* Referred pain to ear.
* Defective gustatory sensation	* changes in tone of vocal cord involvement.
* Dryness of mouth.	* Deafness

Staging:

Stage I: Stomatitis & vesiculation

Stage II: Fibrosis

Stage III: sequelence & complication

HIF:

Atrophic Oral Epithelium

Loss of rete pegs.

Epithelial atypia

Hyalinization of collagen bundles.

Treatment:

Restriction of habits

Non-surgical therapy.

Steroids

Hyaluronidase.

Surgical therapy.

NAME: C. NAVANEETHA
DATE: 20/08/2022

SAVEETHA DENTAL COLLEGE

ORAL PATHOLOGY

50

1. Orofacial cleft:-

↳ A facial cleft results due to lack of fusion of facial embryonic processes.

↳ These are cleft lip, cleft palate, the combination of cleft lip and palate, median cleft of upper lip, oblique facial cleft and lateral facial cleft.

Pathogenesis:-

→ Polygenic / multifactorial inheritance
→ Monogenic / syndromic associated with a variety of other congenital Anomalies, nutritional disturbances
→ Circulating substances like Alcohol, drugs & toxins.
→ Infections like German Measles.
→ lack of developmental force.

Classification:-

.ICPR classification:-

→ Group I: cleft of lip / Alveolus
→ Group II: cleft of secondary palate
→ Group III: combined cleft of primary & secondary palates.

Clinical Features:-

→ Sex: Females - Isolated cleft Palate, cleft lip & cleft palate in Males.

→ Breast feeding is Very difficult as babies Cannot suck.
→ Maxillary anterior teeth may be misplaced, impacted
→ Retrution of Maxilla with narrow palatal arch.
→ Deflection of nasal tip towards the noncleft sid
→ pierre Robin syndrome.
→ Treacher collins syndrome
→ Symptoms in pierre Robin syndrome:-
    → posterior displacement of tongue
    → lack of support of the tongue musculature
    → Airway obstructions.

Treatment and prognosis:-

→ It involves multidisciplinary approach genetic Counsellor, Prosthodontist, plastic surgeon, Orthodontist, Paediatrician & speech therapist.
→ placement of Nasopharyngeal airway may be done.
→ Surgical treatment includes primary lip done by following the rule of 10 for the child.
    → 10 pounds of weight
    → 10 weeks of Age
    → 10g/dl of haemoglobin.

2. Developmental disturbances affecting structure of teeth:-
    ↳ Amelogenesis Imperfecta
    ↳ Dentinogenesis Imperfecta
    ↳ Dentine dysplasia

↳ Regional Odontodysplasia

↳ Enamel hypoplasia



Amelogenesis Imperfecta :-

It is a group of hereditary defect unassociated with any other generalized defect or systemic disorder. It is entirely / ectodermal disorder.

1. Hypoplastic – Defective Matrix formation
2. Hypocalcified - Defective mineralization of matrix.
3. Hypomaturation - Enamel fails to mature.

Classification :-

Type I : Hypoplastic

→ IA : Hypoplastic, pitted autosomal dominant.
→ IB : Hypoplastic, local autosomal dominant.
→ IC : Hypoplastic, local autosomal recessive.
→ ID : Hypoplastic, smooth autosomal dominant
→ IE : Hypoplastic, smooth x- linked dominant
→ IF : Hypoplastic rough autosomal dominant
→ IG : Enamel agenesis autosomal recessive.

Type II : Hypomaturation.

→ II A : Hypomaturation, pigmented autosomal recessive.
→ II B : Hypomaturation, X- linked recessive.
→ II C : Snow-capped teeth, autosomal dominant.

Type III : Hypocalcified.

→ III A : Hypocalcified, autosomal dominant.
→ III B : Hypocalcified, autosomal recessive.

Type IV: Hypomaturation - hypoplastic with taurodontism:-

IVA: Hypomaturation - hypoplastic with taurodontism, autosomal dominant.

IV B: Hypoplastic - hypomaturation with taurodontism autosomal dominant.

Dentinogenesis Imperfecta :-

↳ It is the hereditary developmental disturbances of dentine.

↳ The gene affected is present on chromosome 4, & It codes for DSPP

↳ Dentine defect associated with opalescent teeth & bone disease is termed

Histopathology:-

→ The enamel appears Normal

→ Dentin is Composed of irregular tubules, often with large areas of Uncalcified matrix.

→ Cellular inclusions probably Odontoblasts in the dentin are not Uncommon.

→ Dentinogenesis Imperfecta 2: Not Adequately documented.

Dentin dysplasia :-

→ It is a genetic disorder of teeth, Commonly exhibiting an autosomal dominant inheritance.

→ It is characterized by the Presence of Normal enamel but Atypical dentine with abnormal

pulpal morphology.

↳ There are two types of dentine dysplasia.

→ Type I: Radicular dentine dysplasia

→ Type II: coronal dentine dysplasia.

Regional odontodysplasia:-

Histopathology:-

→ The Marked reduction in the Amount of dentine, the widening of the predentine layer, the Presence of large areas of interglobular dentine & an irregular tubular pattern of dentine are seen.

→ characteristically the reduced enamel epithelium around non erupted teeth shows many irregular calcifies bodies.

3. Radicular cyst:-

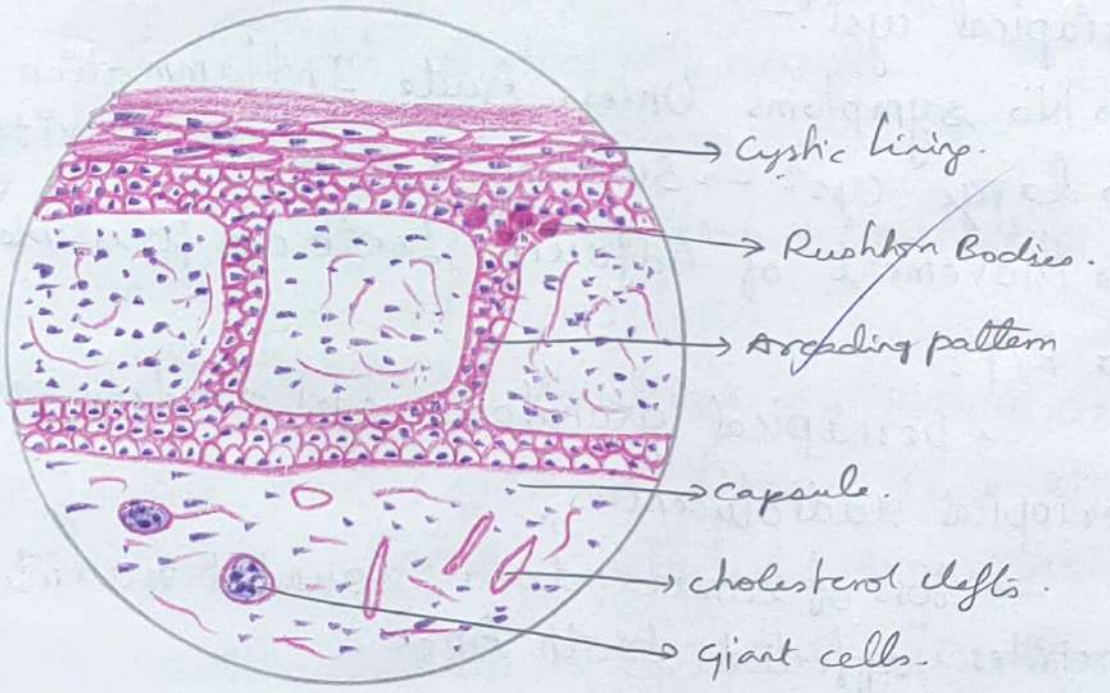

→ The Apex of a nonvital tooth can be stimulated by Inflammation to form a true epithelium lined cyst.
→ Source : rest of Malassez.
→ When cyst & root are removed. 2 variations are seen
  → periapical pocket cysts
  → periapical true cyst.
→ periapical cyst is fibrous connective tissue well lined by epithelium.
→ Lateral radicular cyst - appear along lateral aspect of the root.
→ If is not curetted at the time of tooth removal may give rise to an Inflammatory cyst called a residual periapical cyst.

Clinical and Radiographic features:-

periapical cyst:-
→ No symptoms Unless Acute Inflammation occurs.
→ large cyst → swelling & mild sensitivity.
→ Movement of Adjacent teeth are possible.
→ R/F:-
  → periapical granuloma. cyst develop small periapical radiolucencies.
  → loss of lamina dura, rounded radiolucency encircles affected tooth Apex.
  → Cone-beam CT is used.

↳ Involves deciduous teeth → Molar teeth & appears as a radiolucent zone that surrounds the roots.

SAISWARA DENTAL COLLEGE & HOSPITAL
DEPT OF ORAL & MAXILLOFACIAL SURGERY
THALAMBUR

Lateral Radicular cyst:-

↳ Appears as discrete radiolucencies along lateral aspect of the root.

↳ Loss of lamina dura.

↳ During extraction, Adjacent teeth vitality has to be performed.

eg: globulomaxillary cyst prove to be Inflammatory origin.

Residual periapical cyst:-

→ Appears as a round to oval radiolucency within the alveolar ridge at site of previous tooth extraction.

→ As the cyst ages, dystrophic calcification & central luminal radiopacity occurs.

H/F:-

→ Lined by stratified squamous epithelium, may be lost at place of hyperplastic

→ pseudostratified columnar epithelium are seen.

→ Rushton bodies are seen linear eosinophilic structures represent epithelial degeneration.

→ Arcading pattern of epithelial cells seen which enclose capsular tissue.

Treatment:-

→ Extraction
→ Non surgical endodontic therapy
→ Mass spialization.
→ decompression.

4. Actinomycosis:-

↳ Fungal infection, infection of filamentous, branching, gram +ve anaerobic.

↳ Colonies within tonsilar crypts may from concretions & become large enough for patients to feel firm plugs.

↳ Actinomyces israeli is the causative organisms.

clinical features:-

↳ Acute, rapidly progressing. infection are chronic, slowly spreading lesion.

↳ superficial skin infections.

↳ Suppurative reaction of infection may discharge large yellowish flecks that represents colonies of bacteria called **sulfur granules.**

Histopathological features:-

→ Colonies of filamentous bacteria: Masses of filamentous bacteria.

→ Neutrophils: Collections of Neutrophils surrounding the bacterial mass.

→ Chronically inflamed granulation tissue surrounding large collection of polymorpho

Neutrophils leukocytes.

→ Central core stains basophilic & peripheral portion is eosinophilic.

→ Methenamine silver stain demonstrate the organisms well.

SRINIVASA DENTAL COLLEGE
DEPT OF ORAL PATHOLOGY
THALAMBUR

Diagnosis:-

↳ Culture → 50% grow

↳ Sulfur granules infections demonstrations

↳ fluorescent conjugated Antiserum.

Treatment:-

↳ penicillin

↳ Tetracycline.

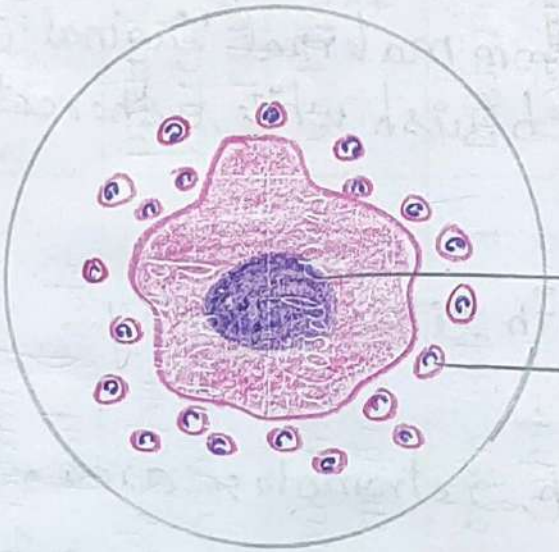

5. **Candidiasis:-**

↳ It is caused by candida albicans

↳ It is a most common and fungal infection in humans

↳ Three factors are determined factors:-

→ The immune status of the host

→ The Oral mucosal environment.

Treatment:

→ The strain of C. albicans.

→ It may range from mild, superficial mucosal involvement seen in most patients.

Clinical features:-

pseudomembranous Candidiasis:-

→ Thrush
→ superficial infection of upper layer of oral mucous.
→ Fungal growth - desquamation of epithelial cell & accumulation of bacteria, Keratin & necrotic tissue forming.

Infants:- → 6th - 10th day after birth.
→ Infection from maternal Vaginal canal
→ Soft white / bluish white, adherent Patches on oral mucosa
→ Painless
→ Removed with little difficulty.

Adults:-

Site: roof of mouth, retromolar area, mucobuccal fold,
sex → female.
Symptom → rapid onset of bad taste & discomfort from spicy food.

clinical type	Appearance & symptoms	Common sites	Associated Factors & comments
Pseudomembranous	Creamy, white plaque,	Buccal mucosa, tongue,	Antibiotic therapy, Immunosuppression.

clinical type	Appearance & symptoms	Common sites	Associated Factors & comments.
pseudomembranous (thrush)	Creamy, white plaque, removable, burning sensation, foul taste	Buccal mucosa, tongue, palate.	Antibiotic therapy, Immunosuppression.
Erythematous	Red malules, burning sensation.	posterior hard palate, buccal mucosa, dorsal tongue.	Antibiotic therapy, Xerostomia, Idiopathic.
central papillary atrophy	Red, atrophic, mucosal areas, asymptomatic	Midline posterior dorsal tongue.	Idiopathic, immuno suppression.
chronic multifocal	Red areas, often with removable white plaque. burning sensation.	posterior palate, posterior dorsal tongue, angles of mouth.	Immunosuppression Idiopathic.
Angular cheilitis	Red, fissured lesions irritated, raw feeling	Angles of mouth	Idiopathic, Immuno suppression loss of Vertical dimension.
Denture stomatitis	Red, asymptomatic	Confined to Palatal denture bearing mucosa.	Probably not true infection

6. Oral manifestation of HIV:-

Group 1	Group 2	Group 3.
Candidiasis i) Erythematous ii) pseudomembranous	Bacterial infection i) Mycobacterium avium ii) Mycobacterium tuberculosis	Bacterial infections. i) Actinomyce Israelii ii) Escherichia idi iii) Cod - Scratch disease.
Oral hairy leukoplakia	Melanotic hyper pigmentation	Drug reaction (Ulcerative, toxic epidermolysis)
Kaposi sarcoma	Necrotising Ulcerative stomatitis	epitheloid Angiomatus
Non-Hodgkin lymphoma	→ Salivary gland diseases. Dry mouth → Thrombocytopenia purpura	Fungal infection → Cryptococcus Neoformans → Histoplasma capsulate → mucormycosis → Aspergillus flavus.
Periodontal diseases i) Linear gingival erythema ii) Necrotising Ulcerative gingivitis	Viral infections - Hsv, Human papilloma virus, VZV.	Neurological disturbances i) Facial Palsy. Viral infection i) cytomegalovirus

7. Verrucous Carcinoma:-

Variant of squamous cell carcinoma characterized by a predominantly exophytic overgrowth of well. differentiated keratinizing epithelium having minimal atypia.

Pathogenesis:-

→ Unknown

→ oral mucosa in people who chronically use chewing tobacco

→ Human papilloma virus type 16 & 18.

clinical features:-

- Age - 60 - 70 years
- Gender - Male predilection
- Site - Buccal mucosa, gingiva, alveolar ridge, palate, & floor of the mouth.

Sign & symptoms:-

→ Exophytic & appears papillary in nature Puffy surface carried by white leukoplastic film.

→ Rugae-like folds with deep clefts

→ Pain & difficulty in mastication, bleeding.

Histopathological features:-

↳ Parakeratin surface layer: this tumor is parakeratinized with plugging into epithelial clefts.

→ Minimal dysplasia → epithelial dysplasia is usually minimal unlike squamous cell carcinoma

→ Acanthosis: the epithelium is thickened.

→ Connective tissue - showing moderate chronic Inflammation.

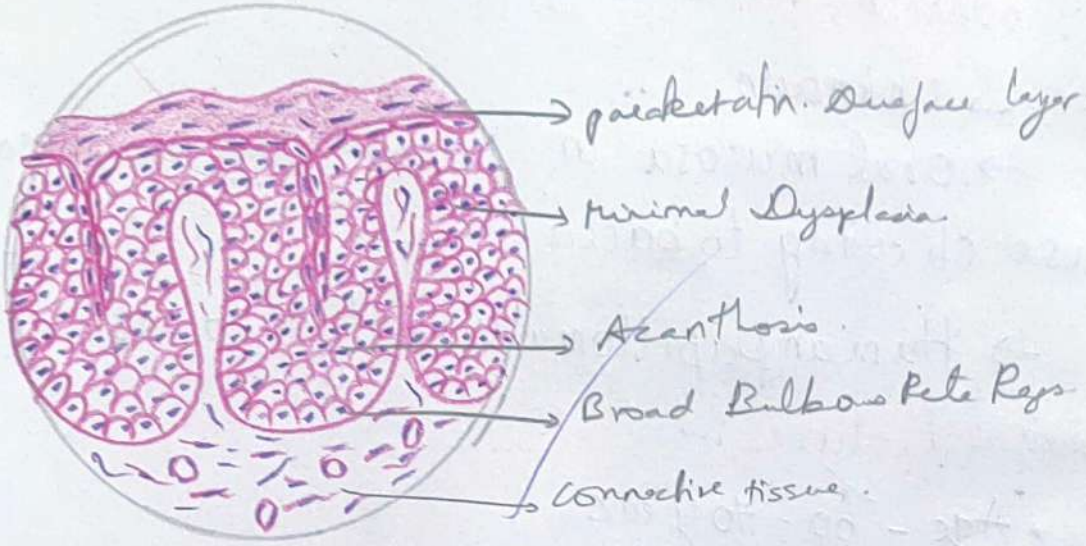

Treatment:-

↳ Surgical excision without radial Neck dissection.

→ Radiotherapy
→ chemotherapy.

8. Pyogenic granuloma:-

It is not associated with pus and doesnot represent granuloma histologically.

↳ Benign, highly Vasular, variant of capillary Haemangioma.

↳ It is common, non-Neoplastic, exuberant tissue.

Pathogenesis:-

Concentration
↓
Inflammation
↓
Differentiation & Maturation.
↓
cells are widely seperated
↓
Little growth occurs
↓
pyogenic granuloma.

Predisposing factors:-

→ Idiopathic, Trauma
→ Poor oral hygiene
→ Homonal stimulation, chronic oral irritants.

C/F:-

Age: young adults.
sex: female predilection
Site: Gingiva, lips, tongue (dorsal surface).
buccal mucosa:-
Signs & symptoms:-

→ Female is more susceptible because of the hormonal changes during puberty, pregnancy menopause.

→ lesion appears on gingiva of pregnant Common called pregnancy tumor (or) granuloma.

→ Maxillary gingiva involved more frequently.

Histopathological features :-

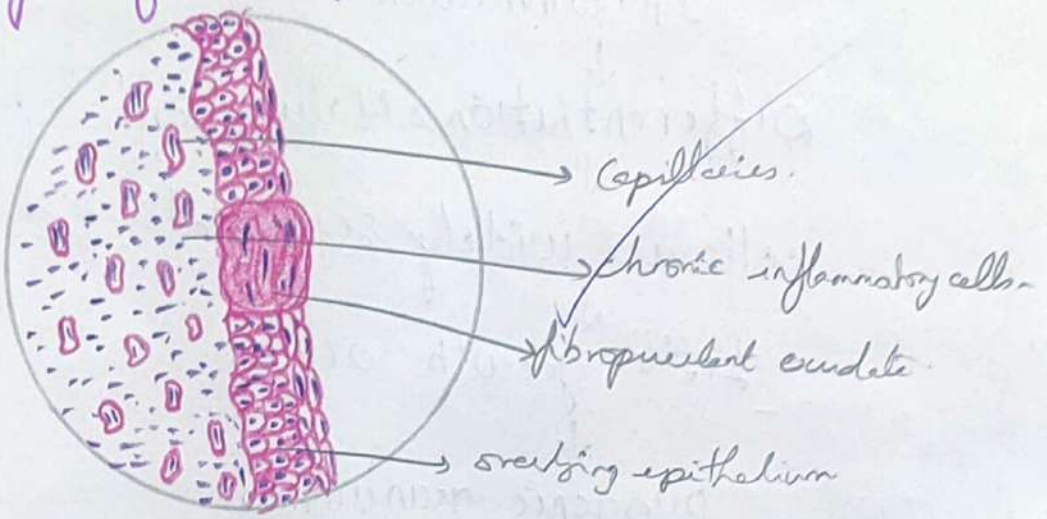

Capillaries: small blood Vessels seen more Numerous beneath the epithelium.

chronic Inflammatory cells:-

Composed Healthy of Lymphocytic & plasma cells with Neutrophils during acute, exacerbation of the Inflammation.

- Overlying epithelium:- is either Ulcerated or Normal sometimes atrophic.

This tumor like growth is Composed of granulation tissue formed is response to gingival irritation.

VENKATESWARA DENTAL COLLEGE & HOSPITAL
DEPT OF ORAL & MAXILLOFACIAL PATHOLOGY

9. oral submucous fibrosis :-

It is an insidious chronic disease affecting any part of oral cavity & sometimes pharynx. Although occasionally preceded by associated with vesicle formation, always followed by a fibro elastic changes of lamina propria with epithelial atrophy leading to stiffness of the oral mucosa & causing trismus.

Etiology - Unknown :-

predisposing factors :- chillies, lime, tobacco, betal nut.

→ Genetic factors
→ Autoimmunity
→ Defective iron metabolism.
→ Bacterial infection
→ Collagen disorders.

clinical feature :-

Age : 20 - 40 years.
sex : No sex predilection
Site : Buccal mucosa, retromolar area, soft palate, palatal, tongue & labial mucosa, floor of the mouth & gingiva.

Staging of OSMF:-

Stages I: Stomatitis & Vesiculation

→ Stomatitis include erythematous mucosa, Vesides mucuosal ulcers, Melanotic mucosal pigmentation.

Stage II: Fibrosis.

These is inability to open mouth completely stiffness in mastication. As disease advance. there is difficulty in blowing out cheek & protruding tongue.

Stage III: Sequence & Complication:

patient present with all the Complaints as in stage II, also these may be evidence of leukoplakia.

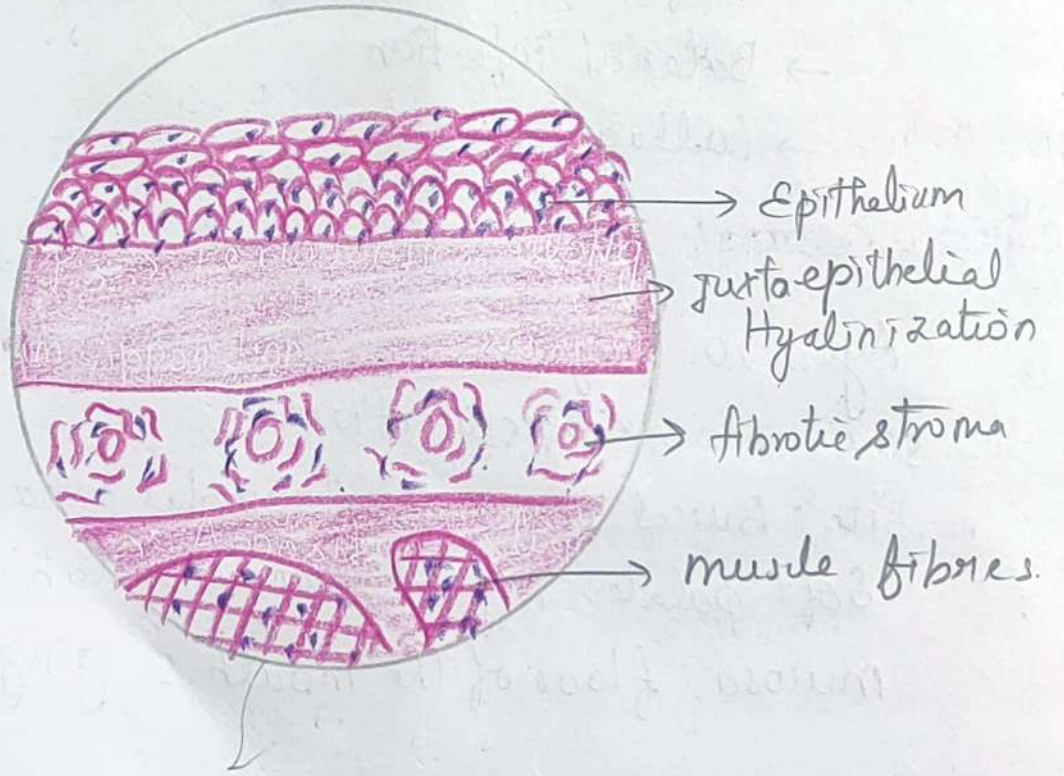

→ Atrophic & epithelium
→ loss of rete pegs, epithelial Atypia may be Obsessed
→ Hyalinization of collagen bundles.

Treatment:-

→ Restriction of habits/ behavioural therapy
→ Non-surgical therapy.
→ Surgical therapy
→ Oral physiotherapy
→ Steroids.
→ Hyaluronidase.

10. Gustafsons age estimation:-

In 1950, Gosta Gustafsons developed as method after age estimation based on. Morphological & histological changes of the teeth.

Assessed regressive changes Such as

A → amount of occlusal attrition
S → secondary dentin deposition
P → loss of periodontal attachment.
C → Cementum apposition at the root Apex
R → Root resorption at the Apex.

T → Dentin translucency.

Attrition:-

A0 → No attrition
A1 → Attrition is enamel
A2 → Attrition reaches Dentin
A3 → Attrition is pulp

Secondary dentin:-

S1 → No formation of secondary dentin
S2 → Secondary dentin has start to begin in pulp.
S3 → pulp cavity half filled with secondary dentin
S4 → pulp cavity fully filled with secondary dentin.

Periodontis:-

P0 → No periodontitis
P1 → Slight lossening of teeth
P2 → Periodontisis along upper 1/3rd of root
P3 → Periodonties along upper 2/3rd of root.

cementum Apposition:-

C0 → No deposition of cementum
C1 → Apposition slightly greater than Normal
C2 → Greater layer of cementum
C3 → Very heavy layer of cementum.

Root resorption :-

R_0 → No resorption.

R_1 → only small isolated spots of resorption

R_2 → lower 1/3rd root resorption is there

R_3 → Greater area of resorption.

Transparency of the root :-

T_0 → No transparency

T_1 → slightly transparency

T_2 → Transparency over 1/3rd apical root

T_3 → Transparency over 2/3rd Apical root.

20/8/22

ORAL PATHOLOGY

VENKATESWARA DENTAL COLLEGE
DEPT OF ORAL & MAXILLOFACIAL PATHOLOGY

29/20

NAME:- Vijaya priyadharshini

ROLL NO:- 99

1). Orofacial cleft :-

A facial cleft results due to the lack of fusion of facial embryonic processes.

There are cleft lip and cleft palate, the combination of cleft lip and cleft palate, isolated cleft lip & median cleft of upper lip.

clinical features :-

Isolated cleft palate is more common in females.

cleft lip / palate are more common in males.

A cleft palate creates a communication between the oral and nasal cavities, patients often feel difficulty in taking food and drinks due to nasal regurgitation.

Breast feeding is very difficult as babies cannot generate sufficient suction.

In case of cleft palate, maxillary anterior teeth may be misplaced, deformed or impacted.

Usually retrusion of maxilla with narrow palate arch is seen.

Deflection of nasal tip towards the noncleft side & large nares on the cleft side.

Bilateral complete cleft shows complete separation of the anterior palate, which projects towards the mid portion of the lip and is attached only by nasal septum.

Prognosis :-

It is a team effort. The team consist of genetic counsellor, prosthodontist, plastic surgeon

Spical treatment includes primary lip closure, which is done by following the rule of 10:-

10 pounds of weight.
10 weeks of age.
10 g/dl of haemoglobin.

Prosthesis should be provided to avoid nasal regurgitation and allow proper feeding of child.

Developmental disturbances affecting structure of teeth

* Amelogenesis imperfecta :-

* It is a group of hereditary defect unassociated with any other generalized defect or systemic disorder. It is entirely an ectodermal disorder.

Amelogenesis imperfecta can be of three types :-

i, Hypoplastic :- Defective matrix formation.

ii, Hypocalified :- Defective mineralization of matrix.

iii, Hypomaturation :- Enamel to mature

Clinical features :-

* Type I :- In generalized pitted pattern, there are pinpoint pits which undergoes staining.

* Type II :- The teeth are normal in shape but the enamel is much softer.

* Type III :- The teeth are shaped normally but after a period of function the enamel is lost

Prognosis :-

* Improve the cosmetic appearance by full crown & veneer.

* Full denture can be provided in cases of enamel agenesis

* Dentinogenesis Imperfecta :-

It is the heredity developmental disturbance of dentine.

The gene affected is present on chromosome 4 & it codes for DSPP.

Dentine defect associated with opalescent teeth and bone disease is termed as osteogenesis imperfecta

Prognosis :-

It is directed primarily towards preventing the loss of enamel and subsequent loss of dentine through attrition.

* Dentine dysplasia :-

It is a genetic disorder of teeth, commonly exhibiting an autosomal dominant inheritance.

It is characterized by the presence of normal enamel but atypical dentine with abnormal pulpal morphology.

There are two types of dentine dysplasia.

i, Type I :- Radicular dentine dysplasia

ii, Type II :- Coronal dentine dysplasia.

Radicular Cyst :-

Radicular cyst are the most common inflammatory cysts and arise from the epithelial residues in the periodontal ligament as a result of periapical periodontitis following death and necrosis of the pulp.

clinical features :-

=> Age :- 40-50 years.
=> Gender :- No gender predilection.
=> Location :- Maxillary anterior region.
=> Sign & Symptoms :-

Usually radicular cysts are asymptomatic and are discovered when periapical radiographs are taken due to tooth discoloration.

The bony hard, slow-growing swelling is often seen. The lesion will be fluctuant.

Pain will be elicited due to secondary infection. Occasionally, a sinus may lead from the cyst cavity to the oral mucosa.

Involved tooth will be nonvital. Vitality test elicits negative response

Radiographic features :-

Usually, the lesion measuring 10-14 mm is granuloma, the lesion measuring 15mm.

classically, radicular cysts appear well-defined round or ovoid-shaped radiolucency with a thin sclerotic border, which indicates a reaction of the bone to the slowly expanding lesion.

Root resorption may be seen in few lesions

Prognosis :-

Small cysts → root canal treatment of the affected teeth and apical curettage.

Large cysts - Surgical enucleation.

4) Actinomycosis :-

It is a chronic bacterial infection caused by Actinomyces species.

It is characterized by chronic suppurative and granulomatous inflammation & formation of multiple abscesses & sinus tracts that may discharge sulphur-like granules.

The most common clinical forms of actinomycosis are cervicofacial, thoracic and abdominal.

Clinical features :-

* Age :- 20-50 years.

* Sex :- Male predilection.

* It may be acute lesions, rapidly progressive infection & chronic lesions, slowly progressive infection that is associated with fibrosis.

* Cervicofacial actinomycosis :-

⇒ Fever, ~~weight~~ loss, malaise & cough are seen.

⇒ The abscess breaks through the skin surface to produce a draining sinus

⇒ localized abscess without fibrosis is seen in tongue.

* Thoracic actinomycosis :-

⇒ It involves lungs & mediastinum.

⇒ It represents osmars, which spreads to involves the pleura, pericardium and chest wall leading to the formation of sinuses that discharge sulphur granules.

Prognosis :-

Surgical drainage & removal of lesion.

Antibiotics like penicillin, for several months to a year.

If the condition is related to an IUD, the device must be removed.

5) Oral Candidiasis :-

Candidiasis is caused by yeast-like fungi, called Candida.

Candida albicans is the most frequent causative organism for candidiasis.

Clinical features :-

It may range from mild superficial mucosal involvement to severe fatal disseminated form as seen in immunocompised individuals

It is also known as oral thrush.

Age :- Any age.

Site :- Buccal mucosa, tongue, palate, gingiva & floor of the mouth.

Soft, white, slightly raised plaque that closely resemble to milk curds.

The palatal lesion contacts with dorsal tongue lesion when tongue is at rest - Kissing lesion

Prognosis :-

discontinuation of broad-spectrum antibiotics

Improved by oral hygiene.

Discontinuity of dentures, if possible.

Oral Manifestations of HIV:-

SRI VENKATESWARA DENTAL COLLEGE
DEPT OF ORAL & MAXILLOFACIAL PATHOLOGY

* Group 1:- Lesion strongly associated with HIV:
  - ⇒ Candidiasis
  - ⇒ Hairy leukoplakia.
  - ⇒ Angular cheilitis.
  - ⇒ Kaposi's sarcoma.
  - ⇒ Non-Hodgkin's lymphoma.
  - ⇒ Cervical lymphadenopathy.

* Group 2:- Lesion less commonly associated with HIV.
  - ⇒ Bacterial infection:- Mycobacterium tuberculosis.
  - ⇒ Melanotic hyperpigmentation.
  - ⇒ Necrotizing ulcerative stomatitis
  - ⇒ Unilateral ~~or bilateral~~ enlargement of salivary gland
  - ⇒ Thrombocytopenic purpura.
  - ⇒ Oral ulcerations.

* Group 3:- Lesion associated with HIV
  - ⇒ actinomycosis, cat scratch disease.
  - ⇒ Candidiasis, aspergillosis, toxoplasmosis
  - ⇒ Facial palsy & trigeminal neuralgia
  - ⇒ Recurrent aphthous stomatitis
  - ⇒ Erythema multiforme, lichen planus.
  - ⇒ Osteomyelitis.
  - ⇒ Thrombocytopaenic purpura.
  - ⇒ Delayed wound healing.

7. Verrucous carcinoma :-

It is a warty variant of squamous cell carcinoma characterized by a predominantly exophytic overgrowth of well differentiated keratinizing epithelium having minimal atypia & with locally destructive pushing margins at its interface with underlying connective tissue.

clinical features :-

* Age :- 60-70 years
* Gender :- Male predilection.
* Location :- Buccal mucosa, gingiva, alveolar ridge, palate & floor of the mouth.
* Sign & symptoms :-

The neoplasm is chiefly exophytic & appears papillary in nature, with a pebbly surface which is sometimes covered by a white leukoplakia film.

The lesion commonly has rugae like folds with deep clefts between them.

Lesions on the mandibular ridge & gingiva grow into the overlying soft tissue & rapidly become fixed to the periosteum, gradually invading & destroy mandible.

Regional lymph nodes often tender & enlarge stimulating metastatic tumours, but this node involvement is usually inflammatory.

Pain & difficulty in mastication are common complaints, but bleeding is rare.

Prognosis :-

Because metastasis is an extremely rare event in verrucous carcinoma, the treatment of choice is surgical excision without radical neck dissection. Radiotherapy is effective.

8) Pyogenic granuloma :-

It is a misnomer since the condition is not associated with pus & does not represent a granuloma histologically. It is highly vascular variant.

Clinical features :-

Age :- Any age

Sex :- Female predilection.

Location :- Gingiva, lip, tongue & buccal mucosa.

Signs & Symptoms :-

Females are more susceptible than males due to hormonal changes like puberty, pregnancy & menopause.

Lesion that appears on the gingiva of the pregnant women is called pregnancy tumors.

If lesion is surgically removed during pregnancy then it usually recurs.

The maxillary gingiva is involved more frequently than the mandibular gingiva.

It is painless.

It size varies from millimeter to centimeter. and red to purple in colour.

Prognosis:-

Remove the aetiology.

Surgical excision of the lesion.

9) Oral Submucous fibrosis:

It is defined as chronic insidious disease affecting any part of the oral ~~cavity~~ cavity & sometimes pharynx.

Clinical features:-

Age :- 20-40 years.

Gender :- No sex predilection.

Location :- Buccal mucosa, retromolar area, soft palate, palatal fauces, uvula, tongue & labial mucosa.

9.

vesiculation, ulceration, pigmentation, recurrent stomatitis & defective gustatory sensation.

Trismus.

The mucosa eventually blanched & opaque & fibrotic bands appear usually involving the buccal mucosa, soft palate, lips & tongue.

Prognosis :-

Discontinuation of habits.

Steroids :- hydrocortisone injection.

vitamin rich diet.

Surgical splitting.

10) Gustafson's age estimation :-

It is based on histological & morphology changes of teeth.

The method asses :-

A → attrition

S → Secondary dentin deposition.

A → Apical migration of PDL attachment

C → cementum deposition of root apex.

R → Root resorption of apex.

T → Root dentin translucency.

For the above variable gustayson's gave four grade ranges from 0 to 3. so a tooth grades of attrition eg:- A0, A1, A2, A3 by adding we get the variable X.

X is noted to increase in total score is present with increases in age.

formula $11.43 + (4.56 \times X)$

20/9/22

N. Chitradevi

①

30/50

SRI VENKATESWARA DENTAL COLLEGE & HOSPITAL
DEPARTMENT OF ORAL & MAXILLOFACIAL SURGERY
THAMMANAM, TEMPLE

① oro facial cleft:

A facial cleft results due to the lack of fusion of facial embryonic processes.

These are cleft lip, cleft palate, the combination of cleft lip and palate, median cleft of upper lip.

pathogenesis:

circulating substances like alcohol, drugs and toxins.

Infections like German measles.

Lack of developmental force.

classification:-

Veau's classification.

International conference of plastic and Reconstructive Surgery.

clinical features:-

Isolated cleft palate is more common in females.

cleft lip / palate is more common in males

Breast feeding is very difficult as babies cannot generate sufficient suction.

usually retrusion of maxilla with narrow palatal arch is seen.

Prognosis and predictive factors:

Surgical treatment includes primary lip closure, which is done by following the rule for the child.

(2) Radicular cyst:

Radicular cyst are the most common inflammatory cyst and arise from the epithelial residues in the periodontal ligament as a result of periapical periodontitis.

pathogenesis:-

phase of initiation
phase of cyst formation
phase of cyst enlargement.

SRIVENKATESWARA DENTAL COLLEGE & H
DEPARTMENT OF ORAL & MAXILLOFACIAL SURGERY
THALAMBUR, CHENNAI - 103

Clinical features:

=> Age : 40-50 yrs

=> Gender : No gender predilection.

=> Location : Maxillary anterior region

=> Signs and symptoms :- usually radicular cysts are asymptomatic and are discovered when Periapical radiographs.

pain will be elicited due to secondary infection.

Histopathology :-

The cystic fluid contents are usually brown due to breakdown of blood and when cholesterol crystals are present they impart a shimmering glod or straw colour.

Secretory product of odontogenic epithelial cells.

Differential diagnosis :

=> Periapical granuloma

=> Central giant cell granuloma.

(3) Actinomycosis

The most common clinical forms of actinomycosis are cervicofacial, thoracic and abdominal.

pathogenesis:-

=> Actinomycetes enter the facial tissues after trauma, surgery or infection.

=> The common triggering causes are dental abscess, oral surgery or intrauterine devices.

=> The bacteria produce the infection by elaborating a toxin or enzyme or by inhibiting host defence.

clinical features:-

=> Age : 20-50 yrs

=> Sex : Male predilection

=> It may be acute lesions, rapidly progressive infection, slowly progressive infection that is associated with fibrosis.

Histopathology:-

=> It shows granulomatous reaction with central abscess formation and characteristic

SRI VENKATESWARA DENTAL COLLEGE & HOS.
DEPARTMENT OF ORAL & MAXILLOFACIAL SURGERY
THALAMBUR, CHENNAI - 103

=> The tissue surrounding the lesion exhibit fibrosis.

prognosis and predictive factors:

=> surgical drainage or removal of the lesion.

=> Antibiotics like penicillin.

(4) Candidiasis:

It is caused by yeast like fungus called candida.

It is the common inhabitant of the oral cavity, vagina, git of normal person.

- predisposing factors:
  - * Radiation therapy
  - * chronic illness
  - * old age / infant.

clinical features:

Acute pseudomembranous candidiasis:

=> It is a common form of disease.

=> Also known as thrush

=> site: buccal mucosa, tongue, palate, gingiva & floor of the mouth.

=> Mild burning sensation & unpleasant taste in the mouth.

Erythematous candidiasis :-

=> only variant which is painful

=> Also known as kissing lesion.

Chronic hyperplastic candidiasis :-

site :- Lip commissures, buccal mucosa, tongue & palate.

Least common form of candidiasis.

Treatment :-

=> To identify & eliminate precipitating factor

=> Discontinuation of broad-spectrum antibiotics.

6 Oral manifestation of HIV:

Group I :- Lesion strongly associated with HIV

=> candidiatus

=> Hairy leukoplakia

=> Angular cheilitis.

Group II :- Lesion less commonly associated with HIV

=> Bacterial infection :- Mycobacterium tuberculosis.

=> Thrombocytopenic purpura.

Group 3:- Lesion associated with HIV

=> Bacterial infection:- Actinomycosis

=> Delayed wound healing

=> Facial palsy

=> Trigeminal neuralgia.

SRI VENKATESWARA DENTAL COLLEGE & HOSPITAL
DEPARTMENT OF ORAL & MAXILLOFACIAL SURGERY
THALAMBUR, CHENNAI - 103

7) Verucous carcinoma :-

It is a low grade variant of oral Squamous cell carcinoma.

clinical features :-

=> predominantly in men

=> Leukoplakia seen on mucosal surface

=> Enlarged cervical nodes

=> most common areas are mandibular vestibule, buccal mucosa, gingiva, tongue & hard palate.

Histopathology :-

=> Characterized by wide & elongated rete ridges that it appear to push into the connective tissue

Treatment :-

Surgical excision.

8. pyogenic granuloma:

It is a relatively common, non-neoplastic exuberant tissue response to localized irritation trauma.

=> predisposing factors.

- Idiopathic
- Trauma
- poor oral hygiene.

clinical features:

=> females are far more susceptable than males.

=> Lesion appears on the gingiva of the pregnant woman is called pregnant women.

=> Develops during first trimester.

=> Early lesion bleeds on probing.

Histopathological:

=> Capillaries:- small blood vessels seen more numerous beneath the epithelium.

=> epithelium is ulcerated / normal - sometimes atropic.

SRI VENKATESWARA DENTAL COLLEGE & HOSPITAL
DEPARTMENT OF ORAL & MAXILLOFACIAL SURGERY
THALAMBUR, CHENNAI - 103

Treatment:-

Remove the etiology

Surgical excision.

9) oral submucous fibrosis:

=> It is a high risk precancerous condition characterized by chronic, progressive scaring the oral mucosa.

=> Etiology - use of betel quiet, pan masala, gutkha.

clinical features:-

=> occurs in young adult betel quid.

=> Inability to open the mouth

=> oral burning sensation.

=> Intolerance to spicy foods.

=> Leukoplakia on the surface noted.

Histopathology:

=> Epithelium:- is atropic in nature.

=> fibrotic stroma is densely packed with collagen

=> Degenerated muscle tissue surrounded by collagen bundle are seen.

Treatment:-

Mild cases treated with extralesional corticosterone.

Vitamins & minerals.

10) Gustafson's age estimation.

⇒ It is based on morphological & histological changes of teeth.

⇒ This method assess changes are:-

* Attrition
* Secondary dentin deposition
* Apical migration.

⇒ For these above variables, Gustafson had given four grades which ranges from 0 to 3. eg:- A0, A1, A2, A3.

⇒ It was noted that increase in total score is present with increase in age.

⇒ Age was estimated by using the formula:

11.43 + (4.56 x x)

=> Since Lobo on some statistical errors noted in gustafson's method, Johanson had modified it,

=> Now the grade for particular variable's substituted in multiple regression formular for estimating the age

=> As per this estimated age =

11.02 + (5.14 x A) + (2.3 x S) + (4.14 x P) + (4.21 x C) + (3.57 x R) + (8.95 x T).

observation is such that more the no. of teeth are used, more is the age estimated

DEPARTMENT OF ORAL & MAXILLOFACIAL SURGERY
THALAMBUR, CHENNAI - 103

d 8/22

ORAL PATHOLOGY

Shanmugapriya Kumar

27/50

SRI VENKATESWARA DENTAL COLLEGE & HOSPITAL
DEPT OF ORAL & MAXILLOFACIAL PATHOLOGY
THALAMBUR

1) Orofacial clefts:

A facial cleft results due to lack of fusion of facial embryonic processes

The cleft lip, cleft palate, the combination of cleft lip and Palate, median cleft of upper lip, oblique facial cleft and lateral facial cleft

Cleft lip and palate.

occurence of cleft lip and cleft palate: ~~50%~~

50% of the cases are cleft lip and cleft palate,

20% are isolated cleft lip, 30% are isolated cleft palate.

Classification:

→ Kaw's classification:

class I: It is a defect of soft palate alone
class II: It is a defect of hard & soft palate
class III: It is a defect of soft palate extending to alveolus and lip
class IV: complete bilateral cleft.

→ ICPR classification:

class I: cleft of lip/alveolus
class II: cleft of secondary ~~lip~~ palate
class III: combined cleft of primary and secondary palates.

Clinical features:

~~Isolated~~ ·) cleft palate is seen more in males
·) Isolated cleft palate is seen more in females.
·) causes difficulty in in taking foods and drinks due the communication between oral and nasal cavities
·) Brest feeding is difficult in babies
·) Maxillary anteriors are misplaced
·) Bilateral complete cleft shows complete separation, of the anterior palate which is attached only by the nasal septum

Prognosis and predictive factors:

It is a team effort by prosthodontist, plastic surgeon, speech therapist, orthodontist.

rule of 10 is followed → 10 pounds weight
10 weeks of age
10 g/dl of Hb.

2) Developmental disturbances affecting structure of teeth

Amelogenesis imperfecta:

A group of hereditary defect unassociated with any other generalized defect or systemic disorder

three types → Hypoplastic
Hypocalcified
Hypomaturation

clinical features:

Type-I - generalized or pitted form
In smooth form enamel surface is thin, glossy the thickness is not enough

Type II - teeth is normal in shape but enamel is much softer

Type III - teeth are shaped normally but after a period of function the enamel is lost

Radiographic features:

The enamel may be completely absent
If present, it appears as a thin layer over crown

Histopathology:

Hypoplastic : Matrix formation is defective
Hypocalcification: Improper mineralization
Hypomaturation: Alteration in enamel rods.

prognosis:

Improve the cosmetic appearance by full crown or veneer.

Dentinogenesis Imperfecta:

Hereditary developmental disturbance of dentine

gene affected is DSPP (Dentine sialophosphoprotein) and

SAVEETHA DENTAL COLLEGE AND HOSPITALS

Classification

Shields classification

Dentinogenesis Imperfecta, type I: with osteogenesis imperfecta.
Dentinogenesis Imperfecta type II: with osteogenesis imperfecta.
Dentinogenesis Imperfecta, type-III: Brandywine type.

Then it was revised:

Dentinogenesis Imperfecta 1: without osteogenesis imperfecta.
Dentinogenesis imperfecta 2: with osteogenesis imperfecta.

~~Clinic~~ ~~Dentio~~

Clinical features:

Teeth are bluish grey colour / brownish
enamel spalls due to occlusal force.
The crowns of teeth wear rapidly after eruption.
The dentine is amber and smooth.

Radiographic features: The deciduous dentition shows very large pulp chamber and root canals.

Histopathological: the enamel appear normal
Dentine may contain few number of tubules

Prognosis crowns can be considered success

The main objective is towards preventing the loss of enamel and loss of dentine through attrition

3) Radicular cyst

Radicular cyst are the most common inflammatory cysts and arise from the epithelial residues eg in PDL as a result of periapical Periodontitis following death and necrosis of pulp.

Clinical features:

Age: 40-50 years
gender: no sex predilection
location: Maxillary anterior tooth

Signs and symptoms:

asymptomatic and are discovered during periapical radiographs.

Bony hard, slow-growing is often seen.
Pain caused. sudden infection

It doesn't affect the primary teeth due to the following reasons

→ pulpal and periapical infections drains readily
→ pulpal floor has numerous accessory canals.

Radiographic features:

lesion 10-15mm is granuloma, the lesion more than 15cm is cyst.

loss of lamina dura is seen.

root resorption is seen

Histopathology:

→ It has russell bodies along with cholesterol clefts which has giant cells.

Types → True radicular cyst
└→ periapical pocket cyst.

Prognosis: Small cyst: RCT of the affected tooth.
Large cyst: surgical enucleation.

Actinomycosis:

Bacterial infection caused by Actinomyces species

Quick features:

Age: 20-40 years
Sex: Male predilection

Cervicofacial actinomycosis:

Most type of infection
occurs in mouth, salivary gland, skin of face and neck.
Bacteria enters through the periodontium
It may arise from decayed tooth, diseased tooth, abscess or from extraction
weight loss, malaise, cough are seen
The abscess bursts through skin surface to produce a drainage sinus.
Thoracic and abdominal actinomycosis is also seen

Histopathology:

It shows granulation region with central abscess
The colony appears to float in a sea of PMNs and multinucleated giant cells.
Tissue surrounding the lesion exhibit fibrosis
The colony appears lobulated, made of mesh work of haematoxylin filaments

Diagnosis: culture of tissue / fluid

Prognosis: surgical removal of lesion
Antibiotics.

oral

Oral candidiasis:

caused by candida albicans.

It has three forms → pseudohyphae, yeast, chlamydia form

Clinical features:

Acute pseudomembranous oral candidiasis:

also called as thrush,

site: Buccal mucosa, tongue, palate, gingiva, and floor of mouth.

soft, white curd plaques seen in the mucosa.

on stripping away leaves a erythematous surface.

Erythematous candidiasis:

includes antibotic sore mouth, central papillary atrophy of tongue, occurs as a sequale of antibiotics.

The lesion appears erythematous, It is painful

Chronic hyperplastic oral candidiasis:

site: lip commissure, buccal mucosa, tongue, palate

palques can't be removed by scrapping

Plaques are bilateral, slightly elevated

Chronic atrophic oral candidiasis: Age: elders female

site: maxillary arch.

characterised by diffuse erythematous denture bearing area.

Histopathology:

chronic inflammatory cell infiltration can be seen in connective tissue

small collection of neutrophils is often identified in Palakeratin layer and the superficial spinous cell layer near the organisms

Prognosis:

to identify and eliminate the predisposing factor

discontinuation of broad spectrum antibiotics

Improve good oral hygiene.

SRI VENKATESWARA DENTAL COLLEGE & HOSPITAL
DEPT OF ORAL & MAXILLOFACIAL PATHOLOGY
THALAMBUR

Oral manifestations of AIDS

group I: lesion strongly associated with HIV

- → candidiasis
- → Hairy leukoplakia
- → Kaposis sarcoma
- → Angular chelitis
- → Non Hodkins lymphoma
- → cerical lymphadenopathy
- → PDL diseases: gingivitis, NUG, NUP

group II: lesion less commonly associated with HIV

- → Bacterial infection: Mycobacterium tuberculosis
- → Melanotic hyperpigmentation
- → Necrotizing ulcerative stomatitis
- → enlargement of salivary gland
- → Thrombocytopenia purpura.
- → oral ulcerations
- → viral infection: HSV, varicella zoaster virus

group III: lesion associated with HIV.

- → Bacterial infection: → eg actinomycoses, syphilis, cat scratch disease
- → viral infection: → cytomegalovirus
- → Fungal infection → candiasis, zygomycosis
- → neurological disorders → facial palsy etc.
- → Recurrent aphthous stomatitis
- → osteomyelitis
- → Thrombocytopenia purpura
- → Delayed wound healing
- → Dermatological disorder eg lichen planus.

7) Verrocous carcinoma:

It is a warty variant of squamous cell carcinoma characterized by a predominantly exophytic overgrowth of well-differentiated keratinizing epithelium having minimal atypia and locally destructive pushing margins at the interface.

clinical features: Age: 50-70yrs

gender: Male predilection.

signs and symptoms:

It is chiefly exophytic in nature, with a pebbley surface which is sometimes covered by a thick leukoplakic film

It has sugar like folds with deep clefts

Pain and difficulty in mastication is seen.

Histopathology:

epithelial proliferation with down growth of epithelium into connective tissue but usually without a pattern of true invasion.

cleft spaces lined by thick layer of parakeratin extended from the surface deep into lesion.

Parakeratin plugging is observed

Prognosis:

surgical excision without radical neck dissection

Radiotherapy is effective.

8) Pyogenic granuloma:

It is a benign, highly vascular variant of capillary hemangioma. it is non neoplastic, exuberant tissue response to localized irritation or trauma

clinical features:

Age: young adults

Sex: female predilection

Location: gingiva, lips, tongue, and buccal mucosa.

signs & symptoms:

females are far more susceptible to it cause of hormonal changes

During pregnancy the tumor is called pregnancy tumor due to hormonal changes.

Lesions ulcerated due to extreme vascularity and soft in consistency

It is painless and seen as pedunculated mass.

Histopathology -

The epithelium overlying is flattened or ulcerated and the adjacent is acanthotic

it is covered by fibropleresent membrane.

It is lobulated and is set in fibromyxoid matrix.

scattered in neutrophils and lymphocyte.

Mature lesion has more collagen

Prognosis:

Remove the aetiology

Surgical excision of lesion

9) OSMF:

It is defined as a chronic insidious disease affecting any apart of oral cavity and sometimes pharynx. it is always associated with Juxta-epithelial inflammatory reaction followed by fibroelastic change of lamina propria with epithelial atrophy leading to stiffness of oral mucosa.

Clinical features: Age: 20-40 years

gender: women predilection.

location: Buccal mucosa, retromolar area, soft palate, palatal fauces, uvula, tongue and labial mucosa.

Signs and symptoms:

late symptom are trismus

vesiculation ulceration is seen

During sensation of oral mucosa, aggravated by spicy food.

Histopathology:

The oral epithelium is atrophic with complete loss of rete ridges

underlying connective tissue shows hyalinization

homogenization of collagen bundles.

Prognosis

discontinuation of causative factor

10) Age estimation by gustafson's method:

It is based on morphological and histological changes of teeth.

The method assesses:

A → attrition
S → secondary dentin deposition
P → apical migration of PDL attachment
C → cementum apposition of root apex
R → Root resorption of apex
T → Root dentin transluceny

For the above variables of gustafson gave four grades ranges from 0 to 3. so a tooth has four grades of attrition eg: A_0, A_1, A_2, A_3 By adding we get the variable x.

x is noted to increase in total score so is present with increase in age.

formula:- $11.43 + (4.56 \times x)$

Oral pathology

8 hrs 10.8

21/50 IV



1) Orofacial clefts:-

Orofacial clefts are gaps (or) opening created due to incomplete fusion of various embryonic Processes during the intrauterine life.

Cleft lip: developmental anomaly characterized by wedge shaped gap (or) opening in the lips, which results from failure of two parts of the lips to fuse together at the time of development.

Cleft palate: non union of medial nasal Processes and maxillary process.

Etiology: hereditary & environmental factors

Common Syndromes

→ Pierre Robin syndrome.
→ Apert's syndrome.
→ Cleidocranial dysplasia
→ Downs syndrome

Treatment: Cosmetic repair of facial clefts

2) Distrabance in size of teeth:

Microdontia:- is a condition which characterized more teeth are smaller than normal in size

Causes: cleft lip and cleft palate, Supernumerary teeth, peg shaped lateral.

Types: True Generalized microdontia.
Relative Generalized microdontia

Macrodontia:- Is a condition in which teeth in the jaws are measurely larger than normal in size.

Causes: fusion of teeth, Idiopathic

Types:- True generalized macradontia.
- Relative generalized macrodontia.
focal macrodontion

Others:

->Anodontia.
->Supernumary teeth

Radicular cyst: Most common odontogenic cystic lesion of inflammatory origin which occurs in relation to apex of non vital tooth.

Types: True radicular cyst.
Bay cyst.

Clinical features:

50% (or) more among all types of jaw cysts.

→ Mostly 3rd 4th and 5th decade of life
→ More common among males.
mostly occurs in maxilla 60%.

Radiological features:

→ well defined, unilocular, and round shaped radiolucent area of variable size.

→ Histopathology:

→ Presence of cystic cavity.
→ discontinuous of epithelial lining is seen

Treatment: apical curettage.

4) Actinomycosis:

-chronic granulomatous, suppurative and fibrous infection

Types: Actinomycosis Predominantly occurs in 3 forms:

→ Cervicofacial actinomycosis
→ Abdominal actinomycosis
→ Pulmonary actinomycosis

Clinical features:

occurs mostly in 4th and 5th decade of life
Sex: more prevalent among males.
Site: disease commonly involves the Jaw bone, upper neck and salivary glands of

Diagnosis:

→ Bacterial culture.
→ Immunofluorescence.

Treatment:

high dose of penicillin drugs (like penicillin, Cephalosporin, clindamycin and Lincomycin etc

5) Candidiasis:- Candidiasis is most common type of mycotic (or) fungal infection that occurs in the oral cavity and is predominately caused by Candida albicans.

Types:-

→ Acute pseudo membranous Candidiasis
→ Acute Atrophic Candidiasis.
→ Chronic Atrophic Candidiasis
→ Candida associated angular cheilitis.
→ Chronic hyperplastic candidiasis

Systemic Candidiasis:-

→ chemical burn.
→ Mucous patch of syphilis
→ Traumatic ulcer.
→ Leukoplakia
→ Lichen planus.

Treatment:-

→ administration of nystatin is done
Systemic administration of amphotericin
- B.

6) Oral manifestation of AIDS:-

Oral candidiasis:

- Erythematous, hyperplastic and pseudo membranous.

Viral infections of oral mucosa: Herpes simplex and herpes zoster, Epstein Barr virus.

Stomatitis:

→ Progressive necrotizing ulceration of oral mucosa.

→ Recurrent major aphthous.

Salivary gland disease:-

→ parotitis and enlarged parotid

→ Sjogren's syndrome

→ Xerostomia

Neurological disorder:

→ facial palsy.

→ Trigeminal neuropathy

Verrucous carcinoma:

→ It is diffuse papillary, non metastasing well differentiated malignant neoplasm of oral epithelium

clinical features:

- mostly affects over 60 years of age and never before 35 years of age
→ Predominantly affects male.
→ Intraorally ~~buccal~~ mucosa accounts for more than half of cases other common intraoral location include gingiva and alveolar mucosa

Histopathology:

→ differentiated malignant epithelial cells
→ bulbulous appearance

Treatment:

Surgical excision

20-08-22 Oral pathology 18/50 M. Roshini

1. Orofacial cleft:

It occurs due to the lack of fusion of facial embryonic processes.



The orofacial clefts are cleft lip, cleft palate, combination of cleft lip and cleft palate, median cleft of upper lip, oblique facial cleft and lateral cleft lip.

Pathogenesis:

1. Congenital anomalies
2. Infections like German measles.
3. Alcohol, drugs, toxins
4. Late pregnancy
5. Emotional stress.

Classification

Veau's

Group I - Defect of soft palate only

Group II - Defect of hard and soft palate

Group III - Defect of soft palate extending to alveolus and lip.

Group IV - complete bilateral cleft.

Clinical features:

Cleft palate common in females

Cleft lip common in males.

Impacted teeth, supernumerary teeth

Retrusion of maxilla.

Pierre Robin syndrome

Treacher collins syndrome

Treatment and prognosis:

It is a multidisciplinary approach.

surgical treatment of cleft lip:

Rule 10

10 pounds of weight

10 weeks of age

10 g/dl of Hb.

2. Developmental disturbance of structure of tooth

1. Microdontia:

This term is used to describe teeth without smaller than normal

3 types

* True generalized microdontia.
* Retaline generalized microdontia.
* Microdontia involving a single tooth.

2. Macrodontia.

Teeth are larger than normal

3 types

* True generalized
* Relative generalized
* Macrodontia involving a single teeth.

3. Hemination:

which arises from an attempt at division of

single tooth germ by an invagination of the resultant in complete formation of two teeth.

4. Fusion:

Fused tooth arises through union of two normally separated tooth germ.

5. Concrescence:

Teeth are united by cementum only.

Most commonly seen in maxillary posterior.

6. Dilaceration:

Refers to an angulation or a sharp bent in root of a teeth

7. Talon's cusp.

Talon's cusp is an anomalous structure resembling eagle's talon.

3. Radicular cyst

It is also known as peri apical cyst or apical pe
-l cyst

the apex of a nonvital tooth can be stimulat
by inflammation to form a true epithelium lined cyst

source - rest of malassez.

perifapical cyst is fibrous connective tissue wall
lined by epithelium.

Lateral radicular cyst - appears along the lateral
aspect of the root.

clinical features.

perfapical cyst - large cyst with mild sensitivity & swelling
Movement of adjacent cyst possible.

No symptoms unless acute inflammation occurs.

Radicular cyst - Appears as round to oval radiolucency
dystrophic calcification
central luminal radiopacity occurs.

Histopathological features.

lined by stratified squamous epithelium.
pseudostratified columnar epithelium is seen.
Arcading pattern of epithelial cell seen
which enclose capsular tissue.
cholestrol clefts and giant cell of multinucleated
foreign bodies reaching to cholesterol crystals.
Rhuton bodies are seen.

Treatment & prognosis.

Extraction

Diagon

Non surgical endodontic therapy

Decompression

Masupilization.

SHAKSHAKATEWARA DENTAL COLLEGE & HOSPITAL
DEPT OF ORAL & MAXILLOFACIAL PATHOLOGY
THALAMBUR

4. Actinomycosis.

Fungal infection, infection of filamentous branching, gram +ve anaerobic.

Causative organism - Actinomyces Israelii

Clinical Features:

Acute, rapidly progressing,

superficial skin infections

yellowish discharge is seen called sulphur granules.

Trauma, Tonsillar hypoplasia occurs, periodontal infections, Non-vital teeth

Histopathological Features:

Masses of filamentous bacteria.

Neutrophils surrounds the bacterial colonies.

chronically inflammed granulation tissue.

stain used Methcamine silver stain.

Diagnosis: culture >50% grow

sulfur granules infections demonstration

Fluorescent conjugated antiserum.

Treatment.

penicillin

Tetracyclin.

3. Radicular cyst

5. candidiasis:

It is caused by candida albicans.

It is a most common oral fungal infection in humans

3 factors are determined factors:

The immune status of the host

The oral mucosal environment

The strain of candida albicans.

It may range from mild, superficial mucosal involvement seen in most patients.

clinical features:

1. pseudomembranous candidiasis.

It is also called oral thrush

superficial infection of upper layer of oral mucosa.

soft, white adherent patches on oral mucosa.

painless

Removed with little difficulties.

2. Erythematous candidiasis:

Red macules, burning sensation in the posterior hard palate, buccal mucosa, dorsal tongue.

Associated factor - xerostomia, antibiotic therapy, idiopathic.

3. central papillary atropy:

Red, atrophic mucosal area, asymptomatic.

occur in midline posterior dorsal tongue.

Associated factor - immunosuppression, idiopathic.

4. chronic multifocal.

6.

Red area after with removable white plaque, burning sensation.

5. Angular cheilitis.

Red fissured lesion, irritated, occur in angle of mouth.

6. Denture stomatitis:

Red, asymptomatic.

confined to palatal denture bearing area.

7. Hyperplastic candidal leukoplakia

White plaque that are not removed.

8. Mucocutaneous candidiasis:

white plaque, some of which is.

loss of lamina dura.

~~Pseudomembranous~~ Removable, red areas.

occur in tongue, buccal mucosa, palate.

Treatment:

Antifungal therapy.

6. oral manifestations of HIV

1. candidiasis.

Most common oral manifestation of HIV

2. oral hairy leukoplakia.

White mucosal plaque that donot ruboff.

It occurs on the lateral border of tongue

3. Kaposi's sarcoma:

vascular endothelial neoplasm caused by human herpes virus 8

single / multiple bluish swelling

occur in gingiva, hard palate, tongue

pain, bleeding, necrosis are present.

4. Non Hodgkin lymphoma.

Malignancy of HIV infected individuals.

It involves extraoral site and CNS.

5. HIV associated periodontal disease.

a. Linear gingival erythema.

Linear band of erythema in free gingival margin

b. Necrotizing ulcerative gingivitis.

6. Less commonly affected are

a. Herpes simplex virus:

It involves when CD4 cells count below 50 cells /mm^3.

b. Human papilloma virus

c. Hyperpigmentation:

Hyperpigmentation is seen in skin, nail, mucosa.

7. Other lesions:

Aphthous ulcerations

Histoplasmosis

Molluscum contagiosum.

verrucous carcinoma.

Variant of squamous cell carcinoma

Well differentiated keratinized epithelium having minimal atypia.

pathogenesis: chewing tobacco

human papilloma virus type 16 and 18.

clinical features:

site: Buccal mucosa, gingiva, alveolar ridge, palate and floor of mouth

sign and symptoms: exophytic and appears papillary in nature.

Rugae like fold with deep cleft

lesions on mandibular ridge into the overlying soft tissue and become fixed to the periosteum.

Regional lymph nodes often tender and enlarged stimulating metastatic tumor.

pain and difficult in mastication, bleeding.

Histopathological features.

Epithelial proliferation

Mitotic activity, pleomorphism (or) hyperchromatism.

cleft like spaces lined by a thick layer of parakeratin

Basement membrane is intact

chronic inflammatory infiltrate in the underlying the connective tissue

treatment:

surgical excision without radical neck dissection

Radiotherapy

chemotherapy.

8. oral submucous fibrosis

It is a chronic disease affecting any part of the oral cavity.

Etiology unknown

predisposing factor: Tobacco, betelnut
Genetic factor
Autoimmunity
Bacterial infection
collagen disorder

clinical features: site: Buccal mucosa, retromolar pad, soft palate, palatal fores, tongue, labial mucosa.

signs and symptoms: Burning sensation on eating spicy food
Difficulty in opening mouth
Difficult in swallowing
Blisters on palate
Excessive salivation.
Dryness of mouth
Ulceration.

stages: stage I - stomatitis and vesiculation
stage II - fibrosis
stage III - sequelae and complication.

Histopathological features:
Atropic oral epithelium
loss of rete pegs
Epithelial atypia may be seen.
Hyalinization of collagen bundles.

Treatment: Non-surgical therapy
Restriction of habits and behavioural therapy
oral physiotherapy
steroids
Hyaluronidase.

pyogenic granuloma

Benign condition, highly vascular variant of capillary hemangioma.



Non-neoplastic.

Pathogenesis: Inflammation

↓

Differentiated and matured

↓

cells are widely separated

↓

little growth occur

↓

pyogenic granuloma.

clinical Features: site: Gingiva, lip, tongue

signs and symptoms: Females are more susceptible

lesion appears on pregnancy women called pregnancy tumor (or) granuloma gravidarum.

Maxillary gingiva involved more freuently

painless and represent pedunculated or sessile rapid growth

Red purple colour

soft, moist glistening surface, ulcerated.

Histopathological Features: Epithelium is flattened, atrophic

Ulcerated epithelium often covered with fibrinopurulent membrane.

Endothelial cell with vascular channels

scattered mixed inflammatory cell

Basic lesion is lobular hemangioma.

Differential diagnosis: peripheral ossifying fibroma

peripheral giant cell granuloma.

well-differentiated angiosarcoma.

Treatment:

Remove the etiology

surgical excision of lesion.

10. Gustafson age estimation

The following 6 dental changes were studied for age estimation.

1. Attrition - physiological wear and tear of occlusal surface of teeth due to mastication

A_0 - No attrition A_1 - attrition in enamel, A_2 - Attrition reaches dentin A_3 - Attrition in pulp

Secondary dentin: produced after root completion

S_1 - No formation of secondary dentin S_2 - secondary dentin has started to begin in pulp

S_3 - pulp cavity has half filled with secondary dentin S_4 - pulp cavity fully filled with secondary dentin

Periodontitis: Inflammation of periodontal tissue

P_0 - No periodontitis P_2 - periodontitis along upper 1/3rd of root

P_1 - slight loosening of tooth P_3 - periodontitis along upper 2/3rd of root

Cementum apposition: deposition of cementum around the root of tooth

C_0 - No deposition of cementum C_1 - Apposition greater than normal

C_2 - greater layer of cementum C_3 - very heavy layer of cementum

Root resorption:

Root resorption is the progressive loss of dentin and cementum by action of odontoclast.

R_0 - No resorption R_2 - lower 1/3rd of root resorption

R_1 - only small isolated spot of resorption R_3 - greater area of resorption.

Transparency of root: with age of the dentinal tubules are filled with minerals and turn opaque.

T_0 - No transparency

T_1 - slight transparency

T_2 - Transparency over 1/3rd of apical root

T_3 - Transparency over 2/3rd of apical root.

20/8/22 - V. Varshini 98.

D Actinomycosis -

Fungal infection, infection of filamentous branching, gram +ve anaerobic

Causative org = Actinomycosis israeli.

25/50

Features:

Acute, rapidly progressing infections or chronic, slowly spreading lesion.

Superficial skin infection.

Tonsillar hyperplasia.

Trauma

Periodontal infections

Non-vital tooth.

Histopathological Features.

Colonies of Filamentous bacteria = masses of filamentous bacteria.

Methamine silver stain demonstrate the organisms well.

chronically inflamed granulation tissue surrounding large collection of PMN leukocytes

Culture - 50% grow
Sulfur granule infections
Fluorescent conjugated antiserum.

Penicillin
Tetracycline.

2) PerIApical cyst (Radicular cyst)

The apex of nonvital tooth can be stimulated by inflammation to form a true epithelium lined cyst.

Source = Rest of Malassez.

Clinical Features:

No symptoms unless acute inflammation occurs.

Large cyst → swelling & mild sensivity.
Movement of adjacent teeth are possible.
Cone beem CT is used.
Involves deciduous teeth - molar teeth & appears as a radiolucent zone that sorrounds the roots.

Types ⇒ Lateral Radicular cyst
Residual Periapical cyst.

Histo Pathological Features:

Lined by stratified squamous epithelium, may be at place of hyperplastic
"Rushton bodies" are seen.

cholesterol clefts arises due to [illegible] breakdown seen as needle shaped spaces.

Giant cells of multinucleated foreign body reacting to cholesterol crystals

DEPT OF ORAL & MAXILLOFACIAL PATHOLOGY

Treatment:

Extraction
Marsupialization
Nonsurgical endodontic therapy.
decompression.

Candidiasis:

Causative organism = Candida albicans.

It is a most common and fungal infections in humans.

Range from Mild superficial mucosal involvement seen in most patients.

clinical features:

Pseudomembranous candidiasis:

* Thrush
* Superficial infections of upper layer of oral mucous membrane.
* Fungal growth - desquamation of epithelial cell and accumulation of bacteria, keratin and necrotic tissue forming.

Clinical Features:

Infants ⇒ 6th – 10th day after birth.
Infection from maternal vaginal canal
Soft white/bluish whit
Painless
Removed with little difficulty.

Adult:

Symptom ⇒ Rapid onset of bad taste & discomfort from spicy food.

Type	Appearance	Common sites.
Pseudo membranous (thrush)	Creamy-white plaque burning sensation	Buccal mucosa, tongue, palate
Erythematous	Red macules, burning sensation	Posterior hard palate.
chronic multifocal	Red areas, often with Removable white plaque, burning sensation	Posterior palate, posterior dorsal tongue, angles of mouth.
Angular chelitis	Red, fissured lesions; irritated, raw feeling	Angles of mouth.
Denture stomatitis	Red, asymptomatic	confined to palatal denture-bearing mucosa.

Diagnosis = can be scrapped off

Diff. diagnosis = plaque from lichen planus
Leukoplakia
chemical burns

4) Verrucous carcinoma.

Snuff Dipper's cancer
Ackerman's tumor.

⇒ variant of squamous cell carcinoma
⇒ predominantly exophytic overgrowth of well-differentiated keratinizing epithelium.

Features:

Sex = Male Predelection.

site = Buccal Mucosa,
Gingiva, alveolar ridge, palate,
Floor & Mouth.

Signs & Symptoms:

Exophytic & appears papillary in nature, pebbly surface covered by white leukoplakic film
Rugae-like folds with deep clefts
Pain in difficulty in mastication, bleeding.
Lesions on mandibular ridge into the overlying soft tissue & become fixed to the periosteum.

Histopathological Features.

Epithelial proliferation with down growth of epithelium into connective tissue.
Little mitotic activity, pleomorphism (or) hyperchromatism. cleft-like spaces lined by thick layer of parakeratin.

Basement membrane is intact.
chronic inflammatory cell infiltration in the underlying connective tissue may be not present.

Treatment:
Surgical excision without radical neck dissection.

5) Orofacial clefts:
cleft lip & palate.

Etiology ⇒ lack of developmental force.
infection like german measles
Alcohol, drugs, toxin.

clinical features ⇒ Sex: Female ⇒ more of isolated cleft palate.
More common in males
Difficult in breast feeding.
Anterior teeth may be displaced, deformed, impacted.
Retrusion of maxilla, with narrow palatal arch is seen.
Pierre robin syndrome
Treacher collin syndrome.
Airway obstruction.
Posterior displacement of tongue.

Treatment:
Placement of nasopharyngeal airway done
Rule 10 for child.
10 pounds of weight
10 weeks of age
10 g/dl of Hb.

Gustafsons Method for Age Estimation:

Based on morphological and histological changes of teeth.

1. Amount of occlusal attrition (A)
2. Coronal Secondary dentin deposition (S)
3. Loss of Periodontal attachment (P)
4. Cementum apposition at the root apex (C)
5. Root resorption at the apex (R)
6. Dentin Translucency (T)

Formula = $11.43 + 4.56X$

$X = An + Pn + Rn + Tn + Cn + Sn.$

7) Pyogenic granuloma.

common, non-neoplastic.

benign, highly vascular variant of capillary haemagioma.

Pathogenesis:

concentration → Inflammation (Stimulated substances) → differentiated & matured

cells are widely separated → little growth occurs → Pyogenic granuloma.

Predisposing factors.

Idiopathic, Trauma, Poor oral hygiene.
Hormonal stimulation
chronic and irritants.

C.F Age = Any age to young adults.

Sex: Female predelection.

SRI VENKATESWARA DENTAL COLLEGE & HOSPITAL
DEPT OF ORAL & MAXILLOFACIAL PATHOLOGY
SRI VENKATESWARA ★ THALAMBUR

Signs & Symptoms ⇒

Painless
Red-purple colour
Pregnancy tumor (or) granuloma gravidarum.
Soft, moist, glistening surface, ulcerated
Maxillary gingiva involved more frequently
Painless & Represents pedunculated (or) sessile rapid growth.

Histopathological Features:

Epithelium is flattened, atrophic & acanthotic
Mature cell has more collagen fibre bundle with fibroblast
Basic lesion is lobular haemangioma.
Scattered mixed inflammatory cells.
Ulcerated epithelium often covered with fibrinopurulent membrane.
Mature cell has more collagen fibre bundle with fibroblast.

Diff. diagnosis:

Peripheral ossifying fibroma
Peripheral giant cell granuloma
well-differentiated angiosarcoma.

Treatment:

Remove the etiology
Surgical Excision of Lesion

General Medicine

Answer Papers

GENERAL MEDICINE
REMEDIAL TEST

Essay:-

① Etiology, classification, clinical features, investigation, and treatment of cardiac failure.

Cardiac failure:

It is a pathophysiological process in which the heart as a pump is unable to meet the metabolic requirements of the tissue for oxygen and substrates despite the venous return to heart is either normal or increased.

Etiology:-

i) systolic failure- most common.
- decrease in left ventricular ejection function <40
due to impaired contractile function
increased afterload (hypertension)
cardiomyopathy.

ii) diastolic failure-
impaired ability of ventricle to relax and fill during diastole → decrease stroke volume and CO.
- diagnosis based on presence of pulmonary congestion, pulmonary hypertension, ventricular hypertrophy.

iii) mixed systolic and diastolic failure.
- seen in disease states such as dilated cardiomyopathy.

iv) Biventricular failure.
- Both ventricles may be dilated and have

Certified

PRINCIPAL
SRI VENKATESWARA DENTAL COLLEGE & HOSPITAL
OFF. OMR NEAR NAVALUR
THALAMBUR, CHENNAI-600 130

poor filling and emptying capacity.

Classification :-

Class I (Mild)

Symptoms :-

No limitation of physical activity, ordinary physical activity does not cause undue fatigue rapid / irregular heart beat or shortness of breath.

Class II (Mild)

Symptoms :-

Slight limitation of physical activity.

Comfortable at rest but ordinary physical activity results in fatigue.

Palpitation, shortness of breath.

Class III :- (Moderate)

Symptoms :-

- Marked limitation of physical activity.
- Comfortable at rest but less than ordinary activity causes fatigue
- Palpitation, dyspnea seen.

Class IV (Severe)

- unable to carry out any physical activity without discomfort
- symptoms of fatigue, palpitation, dyspnea

Clinical features :-

- Signs and symptoms.
- Dyspnea

Certified

PRINCIPAL
SRI VENKATESWARA DENTAL COLLEGE & HOSPITAL
OFF. OMR NEAR NAVALUR
THALAMBUR, CHENNAI-600 130

SRI VENKATESWARA DENTAL COLLEGE & HOSPITAL
DEPARTMENT OF ORAL MEDICINE, DIAGNOSIS & MAXILLOFACIAL RADIOLOGY
THALAMBUR, CHENNAI

- Orthopnea &
- Chyne stokes
- fatigue
- Anxiety
- Rales.

→ Orthopnea: dyspnea on lying.
Blood to the pulmonary circulation while recumbent

→ paraoxysmal Nocturnal Dyspnoea.
Attacks of severe shortness of breath and coughing that generally occur at night usually awakens the person from sleep and may be quite frightening.

- Acute decompensated heart failure.

Early:- ↑ the respiratory rate
↓ in PaO_2 (hypoxia).

Late:- Tachypnea
Respiratory acidosis.

- Right heart failure

Signs and symptoms.

- fatigue weakness, lethargy
- weight gain
- ↑ abdominal girth
- Hepatomegaly
- may not see signs of LVF

- Rt. upper quadrant pain
- elevated neck veins.

Certified
PRINCIPAL
SRI VENKATESWARA DENTAL COLLEGE & HOSPITAL
OFF. OMR NEAR - NAVALUR
THALAMBUR, CHENNAI-600 130

(*) Investigations:-

→ ECG

→ Chest x-ray

- Complete blood count
- Urinalysis
- Serum electrolytes
- Blood urea nitrogen and serum creatine
- Glucose
- Fasting lipid profile
- LFT
- Cardiac Troponins.
- Beta natriuretic peptide
- ~~Arterial~~ Blood gas.

* Management / Treatment:

→ Management of Chronic heart failure

› General measures.

› Correct underlying cause

› Remove precipitating cause

› Prevention of deterioration of Cardiac function

› control congestive HF state

→ Correction of systemic factors.

› thyroid dysfunction

› Infections

› uncontrolled diabetes

› Hypertension

Certified

PRINCIPAL
SRI LENKALESWARA DENTAL COLLEGE & HOSPITAL
OFF. OMR NEAR NAVALUR
THALAMBUR, CHENNAI-600 130

SRI VENKATESWARA DENTAL COLLEGE
DEPARTMENT OF MEDICINE, ORAL AGNOSIS & MAXILLOFACIAL RADIOLOGY
HALAMBUR, CHENNAI

* Non pharmacologic therapy:-
- Exercise training.
- weight loss in obese patients.
- Dietary Na restriction
- Oxygen
- Fluid and free water restriction.

* Order of drug therapy.
- Loop diuretics.
- ACE inhibitors
- Beta Blockers
- Digoxin
- Hydralazine, Nitrate
- Potassium sparing diuretics.

(2). Classification of Anemia.

Anemia:- A reduction in
Red cell mass.
O_2 carrying capacity.

Reduction in the concentration of Hb (RBC)
Compared to values obtained from a reference popu

Hb level - Women → should not be < 12g/dl
Men → should not be < 13g/

Classification of Anemia:-

* Morphologic:
- Normocytic MCV = 80-100 fl
- Macrocytic: MCV > 100 fl
- Microcytic: MCV < 80 fl

* Pathogenic.
- Blood loss (Bleeding)
- Decreased RBC production
- Increased RBC destruction.

Hemolytic Anemia.
- Increased destruction of RBC outside the bone marrow resulting in shortened RBC lifespan

Destruction may be
- within vessels (intravascular)
- within spleen (extravascular).
- Both.

General Diagnostic findings.
- ↑ serum unconjugated bilirubin
Product of breakdown of hemoglobin released by lysed RBC
- decreased serum haptoglobin.
- increased lactate dehydrogenase.
- ± hemoglobinuria.
- ± hemoglobinemia.

Diagnosis of Hemolysis.
- symptoms depend on degree of anemia.
- Clinical features: anemia, jaundice, reticulocytosis, high MCV, RDW, elevated Indirect bili, elevated LDH, low haptoglobin
- smear: polychromatophilia, spherocytosis and autoagglutination.

SRI VENKATESHWARA DENTAL COLLEGE & HOSPITAL
DEPARTMENT OF ORAL MEDICINE, DIAGNOSIS & MAXILLOFACIAL RADIOLOGY
HALAMBUR, CHENNAI

Symptoms:-

- Jaundice.
- shortness of breath
- Fatigue
- Fast heartbeat
- hypotension
- hematuria
- Enlarged spleen or liver

Investigations:

- CBC
- coombs test
- Reticulocyte count
- Hepatoglobin test
- Lactate dehydrogenase
- unconjugated bilirubin
- peripheral blood smear.

Management:

- Vitamins
- corticosteroids
- Prednisolone
- Monoclonal antibody
- monoclonal antibody.
- Anti CD20.

SHORT :-

(2). Status Asthamaticus.

A severe form of asthma in which the airway obstruction is unresponsive to usual drug thrapy.

Contributing factor :-

> infection
> inhalation of air pollution and allergens to which sensitized.
> Non compliance in taking medication
> Aspiration of gastric acid.

Clinical feature :-

> Tachypnea, labored respiration with increase effort on exhalation
> Suprasternal retraction of accessory muscles of respiration
> Anxiety, irritability, fatigue, headache
> muscle twitching.
> Tachycardia.

management :-

> monitor respiratory rate and oxygen saturation continously.
> frequently monitor arterial blood gas level, BP, electrocardiogram.

SRI VENKATESWARA DENTAL COLLEGE & HOSPITAL
DEPARTMENT OF ORAL MEDICINE, D'AGNOSIS & MAXILLOFACIAL RADIOLOGY
HALAMBUR, CHENNAI-103

Administer repeated aerosol treatment with beta 2- agonist bronchodilators such as albuterol or levalbuterol.

- Monitor IV therapy.
- Administer with caution until the metabolic and respiratory acidosis and hypoxemia have been corrected.
- Mechanical ventilation.
- Chest physio-therapy.

---

(2). **Jaundice**

yellowish discoloration of the skin sclera and mucous membrane due to hyperbilirubinemia and deposition of bile pigments.

Types:-

Jaundice

- Prehepatic Jaundice → Arising from the Blood, before it enters the liver → serum total Bilirubin 5-7 µmol/L 0.3-1.0 mg/dL
- Intrahepatic → Due to disease of liver parenchyma → 50-350 µmol/L 0.3-20 mg/dL
- Post hepatic → Result of obstruction of biliary tree outside the Liver → 100-400 µmol/L 0.6-45 mg/dL

DEPARTMENT OF ORAL MEDICINE, DIAGNOSIS & MAXILLOFACIAL RADIOLOGY

Aetiology

Prehepatic :- ↑ Haemolysis

Causes :- Hemolytic Anemia
Malaria
Reduced red cell lifespan.

Intrahepatic :- Obstruction of small bile ducts.
Alcoholic Cirrhosis
Autoimmune Liver disease
Hepatic tumor.
Gall Stones.

Post hepatic :- Obstruction of large bile ducts.
Infection of biliary tree
Gall stones.
Drugs.
pancreatitis.

Signs and Symptoms :-

- Light Coloured stools
- fever
- Headache
- Weakness
- Lost of apatite
- Yellowish discolouration skin
  Mucous membrane
  eyes
- Nausea, vomiting
- Dark coloured urine.

SRI VENKATESWARA DENTAL COLLEGE & HOSPITAL
DEPARTMENT OF ORAL MEDICINE, DIAGNOSIS & MAXILLOFACIAL RADIOLOGY
HALAMBUR, CHENNAI-103

Management

> Iv fluids, medications, antibiotics, blood transfusion
> drug/toxin must be discontinued
> Surgical treatment in case of obstructive Jaundice.

(4) Complications of Diabetes Mellitus.

> Heart and blood vessels.
> Nerve damage
> Kidney damage
> Eye damage
> Foot damage
> Skin and Mouth conditions.
> Alzheimer's disease.
> Hearing impairment
> Depression.

Cardiovascular:-

↑ the risk of many heart problems include coronary artery disease with chest pain, heart attack, stroke, narrowing of arteries.

Neuropathy:- tingling Numbness, burning or pain that usually begins at the tips of toes or fingers and gradually spreads upwards.

Nephropathy :-

damage the filtering system.

Retinopathy :-

Could leads to Blindness.

④ Myxoedema.

extreme manifestations of hypothyroidism.

clinical features :-

- Deterioration in Mental state
- Reduced cerebral blood flow
- Apathy.
- psychosis.
- hyponatreemia.

Metabolic

- Reduced metabolic rate causes weight gain, growth Reduction lower energy Production and many other effects.
- significantly metabolic effects impair drug Metabolism.

Skin - Dry coarse, rough skin - Non Pitting oedema of the hands and feet

Hair Loss (alopecia)

- Cardiovascular.

Reduced heart sounds and reduced apical impulse are typically found.

Management

> early recognition
> presumptive thyroid hormone replacement
> hydrocortisone and appropriate supportive care

(5) SHOCK

Shock is a life-threatening situation due to poor tissue perfusion with impaired cellular metabolism manifested in turn by serious pathophysiological abnormalities.

Classification

> primary (initial shock)
> secondary shock (true shock)
> Anaphylactic shock
> Circulatory shock

Acc to etiology

> Hypovolamic shock
> Cardiogenic shock
> Septic shock
> Traumatic
> Neurogenic
> Hypoadrenal.

→ Due to low flow.
Hypovolemic
Cardiogenic
Obstructive.

Hypovolamic shock → ↓ Effective circulating Blood volume

Hemorrhage
trauma
surgery
dehydration

↓ Venous Return to heart
↓ Cardiac output
↓ Blood flow
↓
↓ supply of oxygen
↓
Anoxia
↓
Shock

Septic Shock

gram +ve Septicemia
gram -ve Septicemia

Cardiogenic shock

deficiency of emptying
Filling outflow obstruction

Management-

> lay the person down, if possible
> Begin CPR ; if necessary
> Treat obvious injuries
> keep person warm and comfortable
> follow up.

(6.)

Herpes zoster

- also known as shingles
- An acute viral infection of nerve cells and surrounding skin
- Caused by the varicella zoster virus that also causes chickenpox.

SRI VENKATESWARA DENTAL COLLEGE & HOSPITAL
DEPARTMENT OF ORAL MEDICINE, DIAGNOSIS & MAXILLOFACIAL RADIOLOGY
HALAMBUR, CHENNAI-103

Shingles usually appears band of blisters on one side of the chest, but it can occur anywhere on the body, including on the face and near the eyes.

Caused by Herpes virus (DNA)

> primary infection results in Chicken pox
> Recurrent infection results in herpes zoster (Shingles).

4 Clinical symptoms:-

Headache
Feeling generally unwell
Myalgia
Fever

Complications:-

> Post herpetic Neuralgia
> Opthalmic Shingles
> Ramsay hunt syndrome
> Hearing problems
> Bacterial infections

Management-

Antiveral medication
Acyclovir
Valacyclovir
Famiciclovir
Topical anesthetics
Opioids, morphine

(7) Scurvy.

Vit-c known as ascorbic acid

Scurvy is a vitamin c deficiency that results from a few weeks to months of no vit c.

Symptoms:-

Early symptoms.

- Appetite loss
- poor weight gain
- diarrhea.
- rapid breathing fever
- swelling over long bones

Progressed symptoms:-

- Bleeding gums.
- Loosened teeth
- corkscrew hair
- petechial hemorrhage of skin
- sicca syndrome.

Prevention

intake of vit c rich foods

Treatment

- Adult RDA for vit c 75mg to 90mg
- Smokers need 35mg more of vit c

VEERAMANI DENTAL COLLEGE & HOSPITAL
DEPARTMENT OF ORAL MEDICINE, DIAGNOSIS & MAXILLOFACIAL RADIOLOGY
HALAMBUR, CHENNAI-102

HIV transmission

Mode - through Bodily

- Blood products
- semen
- vaginal fluids.

sharing needles

- without Sterilization increase that chances of contracting HIV
- unsterilized blades.
- unprotected intercourse

mother to Baby.

Stage 1 - primary

Stage 2 - Asymptomatic

Stage 3 - Symptomatic

Stage 4 - HIV / AIDS.

Treatment options :-

HAART - highly active anti-Retroviral treatment

Nucleoside Reverse transcriptase Inhibitors

Protease Inhibitors

NON - Nucleoside transpritase Inhibitors.

(9) Anaphylaxis

A severe, potentially life threatening allergic Reaction.

Symptoms:-

Skin Rash, nausea, vomiting, difficulty breathing and shock.

treatment

vasoconstrictor.

- If not treated in right way early with adrenalin it can result in unconsciousness or death.

Signs:-

- Skin Reactions
- Low BP
- A weak and Rapid pulse
- Nausea
- Vomiting
- Dizziness.
- Constriction of air ways
- diarrhea.

SRI VENKATESWARA DENTAL COLLEGE & HOSPITAL
DEPARTMENT OF ORAL MEDICINE, DIAGNOSIS & MAXILLOFACIAL RADIOLOGY
CHENNAI-603

Antihypertensive drugs.

- Diuretics
- Beta Blockers
- ACE Inhibitors
- Angiotensin II receptor blockers
- Calcium channel blockers
- Alpha blockers
- Combined alpha and beta blockers
- Calcium channel Blockers
- vasodilators
- central agonists
- peripheral adrenergic Inhibitors.

Chitradevi

6/8/22 General Medicine III - BDS.

Remedial Exam

T.

1. Cardiac Failure:

Cardiac failure is the pathophysiological process in which the heart is unable to meet the metabolic requirements.

classifications:

- Systolic failure
- Diastolic failure.
- Mixed.

Etiology:

Systolic failure - most common.

It is due to

- Impaired contractile function
- Increased afterload.
- Cardiomyopathy.

Diastolic failure:

- Impaired ability of ventricles to relax and fill during diastole.

- Diagnosis based on presence of pulmonary congestion, pulmonary hypertension, ventricular hypertrophy.

Mixed systolic and diastolic failure:

- Seen in disease states such as dilated cardiomyopathy (DCM).

- High pulmonary pressures.

Biventricular failure:

- Both ventricles may be dilated and have poor filling and emptying capacity.

Emergency Management.

- Upright position.
- Nitrates

SRI VENKATESWARA DENTAL COLLEGE & HOSPITAL
DEPARTMENT OF ORAL MEDICINE, DIAGNOSIS & MAXILLOFACIAL RADIOLOGY
HALAMBUR, CHENNAI-600

Treatment:

- Treatments can include low salt, limiting fluid intake and taking prescription medication.

- Physical exercise, quitting smoking, Weight loss and low sodium diet.

- Medication such as Diuretic, Beta blocker, ACE Inhibitor, Antihypertensive drug, Dietary supplement, Blood pressure support

- Cardiac resynchronization therapy.

- Implantable cardioverter defibrillator.

- Coronary artery bypass surgery.

SRI VENKATESWARA DENTAL COLLEGE & HOSPITAL
DEPARTMENT OF ORAL MEDICINE, DIAGNOSIS & MAXILLOFACIAL RADIOLOGY
HALAMBUR CHENNAI

Treatment:

- Treatments can include low salt, limiting fluid intake and taking prescription medication.

- Physical exercise, quitting smoking, weight loss and low sodium diet.

- Medications such as Diuretic, Beta blocker, ACE inhibitor, antihypertensive drug, Dietary supplement, Blood pressure support

- Cardiac resynchronization therapy.

- Implantable cardioverter defibrillator.

- Coronary artery bypass surgery.

2. Anemias :-

Anemias is a decrease in number of red blood cells (RBCs) or less than the normal quantity of hemoglobin in the blood.

Men.

Hb < 13.5 gm / 100ml.

Women.

Hb < 12.0 gm / 100ml.

Types of Anemia:

- Iron - deficiency anemia.
- Pernicious Anemia
- Aplastic Anemia.
- Hemo - lytic Anemia.

Causes of Anemia

SRI VENKATESWARA DENTAL COLLEGE & HOSPITAL
DEPARTMENT OF ORAL MEDICINE, DIAGNOSIS & MAXILLOFACIAL RADIOLOGY
HALAMBUR, CHENNAI-600

- Iron deficiency.
- Vitamin B12 deficiency
- Folate deficiency.
- Certain medication
- Destruction of red blood cells.

Hemolytic Anemias:

Increased destruction of RBC outside the bone marrow resulting in shortened RBC lifespan.

Destruction may be

- within vessels (Extravascular).
- within the spleen (Intravascular).
- or both

classification of Hemolytic Anemias:

- Hereditary.
- Acquired.

Drugs that can cause hemolytic Anemia:

- cephalosporins.
- Dapsone.
- Levodopa.

Treatment:

Treatment of hemolytic Anemia includes;

- Blood transfusions.
- Medicines.
- Plasmapheresis
- Surgery.
- Blood and marrow stem cell transplants.
- Lifestyle changes.

(11).

1. Status Asthmaticus :-

SRM DENTAL COLLEGE & HOSPITAL
DEPARTMENT OF ORAL MEDICINE & MAXILLOFACIAL RADIOLOGY
SRMIHALAMBUR, CHENNAI-603

Status asthmaticus is a medical emergency, an extreme form of asthma exacerbation characterized by hypoxemia, hypercarbia and secondary respiratory failure.

The most common asthma triggers include allergies, air pollution and other airborne irritants

Other health conditions including respiratory infection, increase or physical activity, weather and air temperature, strong emotions and some medicines.

Status asthmaticus is considered a medical emergency. It is the extreme form of an asthma exacerbation that can result in hypoxemia, hypercarbia and secondary respiratory failure.

Pharmacologic treatment of status asthmaticus includes

- Short acting β_2 agonists such as salbutamol administered by oral corticosteroids.

Treatment:

- Beta-agonists
- Corticosteroids
- Theophylline

2. Jaundice:

SRI VENKATESWARA DENTAL COLLEGE & HOSPITAL
DEPARTMENT OF ORAL MEDICINE, DIAGNOSIS & MAXILLOFACIAL RADIOLOGY
VALAMBUR, CHENNAI-103

Jaundice is a condition in which yellowish tinge appears on the skin, mucous membranes and the whites of the eye.

Body fluids may also change colors.

Causes:

- side effects to certain medications
- gallstone disease
- Excessive alcohol consumption.
- cirrhosis, hepatitis

Treatment:

As Jaundice may sometimes indicate damage to the liver, a liver transplant may be necessary in some cases, depending on the severity of the injury. Eating Balanced diet. limiting alcohol consumption.

4. Myxoedema :-

Swelling of the skin and underlying tissues giving a waxy consistency, typical of patients with underactive thyroid glands.

Associated with

- Hypothyroidism
- Including weight gain
- Mental dullness
- Sensitivity to cold.

Myxoedema is a result of undiagnosed or untreated severe hypothyroidism.

It can also develop when someone stops taking their thyroid medication.

Symptoms:

SRM VENKATESHWARA DENTAL HOSPITAL
DEPARTMENT OF ORAL MEDICINE, DIAGNOSIS & MAXILLOFACIAL RADIOLOGY
HALAMBUR, CHENNAI-103

- Fatigue
- constipation
- Weight gain
- cold intolerance.
- coarse hair
- Dry, pale, cool skin.

2 1/2

Treatment involves administrating thyroid hormone replacement medication into a vein.

5. shock:-

shock is defined as a condition where the tissues in the body don't receive enough oxygen and nutrients to allow the cells to function.

classification :-

- Cardiogenic shock.
- Hypovolemic shock.
- Obstructive shock.
- Distributive shock.
  - → Neurogenic shock.
  - → Anaphylactic shock.
  - → Septic shock.

Etiology :-

- Severe allergic reaction
- Significant blood loss.
- Heart failure.
- Burns.

Treatment :-

- Wound debridement, Angioplasty, Tracheostomy.
- Vasodilators, Diuretics, Corticosteroids.

SRI VENKATESWARA DENTAL COLLEGE & HOSPITAL
DEPARTMENT OF ORAL MEDICINE, DIAGNOSIS & MAXILLOFACIAL RADIOLOGY

4. scurvy :-

scurvy results from a lack of

Vitamin c (ascorbic acid).

Early symptoms of deficiency

Include.

- weakness & fatigue.
- Feeling tired
- arms and legs.
- Gum disease
- Easy bleeding.
- Scorbutic Gums.

Complications :

- skin problems
- Oral problems
- Heart & lung problems.

Treatment:

- Vitamin c supplements taken orally.
- The adult dose is 500 - 1000 mg / day

for at least 1 week, then 400 mg / day until

complete recovery.

9. Anaphylaxis:

Acute multi-systemic allergic reaction involving the skin, airway, vascular system and GI.

Severe immediate (type I) hypersensitivity reaction.

True & pseudo-anaphylaxis.

Causes:

- Foods - milk, fish, eggs...
- Medicines - Antibiotics, non-steroidal anti-inflammatory drugs
- Insect stings
- General anaesthetic.

SRIMATHESWARA DENTAL COLLEGE & HOSPITAL
DEPARTMENT OF ORAL MEDICINE, DIAGNOSIS & MAXILLOFACIAL RADIOLOGY
HALAMBUR, CHENNAI-119

Types of Allergic reactions :-

- Immediate (Type I).
- cytotonic (Type II)
- Immune Complex - mediated (Type III).
- Delayed hypersensitivity (Type IV).

Treatment :

- Epinephrine (first + most important).
- vasoconstrictor, Bronchodilator, Antihistamine and steroid.
- Tracheal Intubation, CPR.

2/2

10. Antihypertensive drugs :-

- Antihypertensives are a class of drugs that are used to treat hypertension.

- Antihypertensive therapy seeks to prevent the complications of high blood pressure, such as stroke and myocardial infarction.

Antihypertensive drugs are very common.

Health care providers have several first-line or first choice blood pressure medications. They are,

- Thiazide
- ACE inhibitors
- Calcium channel blockers.

Medications :-

- Diuretics
- β-Blockers
- α-blockers.

Ruban
III - BDS.

General Medicine (Remedial Test)

SRI VENKATESWARA DENTAL COLLEGE & HOSPITAL
DEPARTMENT OF ORAL MEDICINE, DIAGNOSIS & MAXILLOFACIAL RADIOLOGY
HALAMBUR, CHENNAI-130

II) Write notes on.

6) Herpes Zoster.

-> It's an acute viral infection of the nerve cells and surrounding skin.

-> Characterized by rash of blisters.

-> It is due to varicella zoster virus.

Transmission: Transmission occurs through direct contact with open sores of shingles rash.

High incidence: In anyone who were previously affected by chickenpox.

-> >50 years of age.

Pathophysiology:

Varicella zoster virus enters through respiratory tract.

↓

Replication of virus occur in regional lymphnodes.

↓

Primary viremia in bloodstream.

↓

Further viral replication in liver and spleen.

↓

Secondary viremia.

↓

Enter into nerve endings and transport to

dorsal root ganglia where it lies dormant in sensory nerve ganglia, dorsal root

↓

Reactivation in dorsal root ganglia

↓

Infection of nerves and dermatome

↓

Herpes Zoster

Causes & risk factors

→ >50 years of age.
→ In diseases like HIV and cancer.
→ Patients undergoing radiation therapy & chemotherapy.
→ Patients under immunosuppressant drugs like steroids.

Signs and Symptoms:

→ Headache
→ Fever.
→ Myalgia.
→ Rash begin to develop along with pain.
→ Aching or tingling sensation in area of affected nerve.
→ Blisters which are filled with fluid develops and later they break open and crust over in 7-10 days.
This clears within 2-4 weeks.

Implications:

→ Post herpetic neuralgia
→ Ophthalmic shingles
→ Ramsay Hunt Syndrome
→ Encephalitis
→ Hearing problems
→ Bacterial infections on skin

SRI VENKATESWARA DENTAL COLLEGE & HOSPITAL
DEPARTMENT OF ORAL MEDICINE, DIAGNOSIS & MAXILLOFACIAL RADIOLOGY
NALAMBUR, CHENNAI-103

Management:

→ Antiviral medication like acyclovir, valacyclovir & famciclovir can be given.
→ Prevention can be done by giving Shingles vaccine.

(6) Antihypertensive drugs:

1) ACE inhibitors: Captopril, enalapril, lisinopril, perindopril

2) Angiotensin antagonist: Losartan, irbesartan, Candesartan.

3) Calcium Channelblockers: Verapamil, diltiazem, nifedipine, felodipine

4) Diuretics: Thiazide: Hydrochlorothiazide, chlorthalidone.
High ceiling: furosemide
K+ Sparing = Spironolactone, amiloride

Pathophysiology

6) β - adrenergic blockers : Propanolol, metaprolol, atenolol.

6) α + β adrenergic blockers : Labetalol, carvedilol.

*) α - adrenergic blockers : prazosin, terazosin.

8) Central Sympatholytic : clonidine, methyldopa.

9) Vasodilators : Hydralazine, minoxidil sodium

9) Anaphylaxis.

→ Acute multi systemic allergic reaction involving the skin, airway, vascular system and GI

→ Severe immediate (type I) hypersensitivity reaction.

→ True and pseudo anaphylaxis.

Etiology : 1) Food - like peanuts, seafood, wheat.
2) Idiopathic.
3) Drugs - like antibiotics (penicillin), aspirin etc.
4) Exercise.
5) Latex, hormones, insect bites

Pathophysiology.

SRI VENKATESWARA DENTAL COLLEGE & HOSPITAL
DEPARTMENT OF ORAL MEDICINE, DIAGNOSIS & MAXILLOFACIAL RADIOLOGY
THALAMBUR, CHENNAI-103

1) Foist exposure.

activation of TH2 cell

Switching

↓

IgE production

↓

IgE → bind to mast cell.

2) Second exposure

Recognition

↓

Activation of mast cell to release histamine and other mediators.

Signs and Symptoms:

On Skin : 1) Itching.
2) Flushing.
3) Hives
4) Swelling.

Eyes : 1) Itching
2) Tearing.
3) Redness
4) Swelling around the eyes

Nose & mouth : 1) Sneezing
2) Runny nose.
3) Nasal congestion.
4) Swelling of tongue.
5) Metallic tongue taste.

Lungs and throat : 1) Difficulty breathing.
2) Coughing.
3) Chest tightness.
4) Wheezing
5) Increased mucus production.
6) Throat swelling or itching
7) Change in voice

Heart circulation : 1) Dizziness.
2) Weakness.
3) Fainting.
4) Rapid, slow or irregular heart rate.
5) Low blood pressure.

Digestive system : 1) Nausea
2) Vomiting.
3) Cramps
4) Diarrhea

Nervous system : 1) Anxiety.
2) Confusion.
3) Sense of impending doom

DIAGNOSIS : 1) Increased amount of tryptase protein can be measured in blood sample collected during the 1st hours after anaphylaxis symptoms begun

Treatment
1) Epinephrine
2) Diphenhydramine.
3) Cimetidine.
4) Corticosteroid therapy.

Complications of Diabetes Mellitus

SRI VENKATESWARA DENTAL COLLEGE & HOSPITAL
DEPARTMENT OF ORAL MEDICINE, DIAGNOSIS & MAXILLOFACIAL RADIOLOGY
HAMBURG CHENNAI-100

> Metabolic disease affecting carbohydrate and fat metabolisms due to insulin deficiency or inefficiency

→ 2 types:
- Type I (insulin dependant)
- Type II (insulin independent)

COMPLICATIONS OF DIABETES MELLITUS.

I. Acute complications:

1) Diabetic Ketoacidosis.
2) Hypoglycemia.
3) Diabetic nonketotic hyperosmolar coma.

II) Chronic complications.

★ Microvascular: → Retinopathy.
→ Nephropathy.
→ Diabetic foot.
→ Neuropathy.
→ Dermopathy.

★ Macrovascular: → Cerebrovascular.
→ Cardiovascular.
→ Peripheral vascular disease.

DIABETIC KETOACIDOSIS

→ Result from absolute insulin deficiency or increase requirement.

Pathophysiology: 1) Ketosis.
2) Dehydration.
3) Electrolyte imbalance

Diagnosis: 1) Hyperglycemia.
2) Ketonuria and Ketonemia
3) Acidosis (pH ≤ 7.3)

Clinical presentation of DKA

1) Polyuria and Polydepsia.
2) Nausea and vomiting
3) Anorexia and abdominal pain
4) Tachycardia
5) Fruity odor of breath
6) Hypotonia, stupor and coma.
7) Sign of dehydration.

Treatment: 1) Fluid replacement.
2) Insulin therapy hyperglycemia
3) Electrolyte correction
4) Acidosis correction
5) Treatment of precipitating cause

scurvy.

→ Scurvy is a vitamin C (ascorbic acid) deficiency that results from a few weeks to months of no vitamin C (or) 20 to 40 days.

SRM VENKATESWARA DENTAL COLLEGE & HOSPITAL
DEPARTMENT OF ORAL MEDICINE, DIAGNOSIS & MAXILLOFACIAL RADIOLOGY
HALAMBUR, CHENNAI-600

Symptoms.

* Early symptoms: Apetite loss.
Poor weight gain
Diahorrhea
Rapid breathing
Swelling and long bones.

* Progressed symptoms: 1) Bleeding of gums.
2) Loosened teeth.
3) Petechial hemorrhage of skin and mucous membrane.
4) bleeding in eye.
5) Proptosis of eyeball.
6) Corkscrew hair.
7) Hyperkeratosis.
8) Corkscrew hair.
9) Sjoa syndrome.

2 1/2

Treatment → Adult RDA for vit C is 75 mg to 90 mg.
→ Smokers need 35 mg more of vitamin C.
→ It is recommended to take 250 mg of vit C if you have scurvy.
→ Eating vitamin C rich foods.

8) HIV Transmission.

→ Transmission occurs through:

1) Blood Products.
2) Semen.
3) Vaginal fluids.

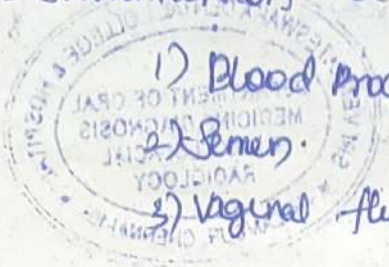

Intravenous Drug Abuse

→ Sharing needles
→ Unsterilized blades.

- Transmits through unprotected sex
→ And from fetus to mother.

y.

Anemia is a hematologic condition in which there is quantitative deficiency of hemoglobin, often accompanied by a reduced number of erythrocytes.

SRM DENTAL COLLEGE & HOSPITAL
DEPARTMENT OF ORAL MEDICINE, DIAGNOSIS & MAXILLOFACIAL RADIOLOGY
HALAMBUR, CHENNAI-89

Classification:

1) According to morphology of RBC.

1) Normocytic normochromic
2) Microcytic hypochromic
3) Macrocytic normochromic.

2) Based on etiology.

1) Increased RBC loss.
2) Decreased or defective cell production.

HEMOLYTIC ANEMIA

→ Due to increased rate of red cell destruction.

→ 2 types: acute / chronic
extravascular / intravascular.
Hereditary / acquired.

Clinical manifestation

→ Compensated or symptomatic anemia
→ Dizziness / weakness
→ fever, weight loss, fatigue
→ Pallor, icterus, dark urine
→ Splenomagaly, lymphadenopathy.

Investigations : Incubated fragility test
Glycerol lysis test.

Enzymatic deficiency : G6PD deficiency.
Pyruvate kinase deficiency

---

1) Cardiac failure.

→ Due to any structural or functional cardiac disorder that impairs ability of ventricle to fill with (or) eject blood

Types : Systolic failure
Diastolic failure
Mixed

Heart failure

↓

Decreased cardiac output

↙ ↘

Activation Sympathetic Nervous System

↓

Increased heart rate

↓ Renal blood flow.

↓

Renin angiotensin aldosterone activation.

→ Arterial and venous vasoconstriction ←

↓

Salt & water retention

↓

Remodelling of heart

↓

Stretching of myocardium

↓

Ventricular hypertrophy.

SRI VENKATESWARA DENTAL COLLEGE & HOSPITAL
DEPARTMENT OF ORAL MEDICINE, DIAGNOSIS & MAXILLOFACIAL RADIOLOGY
, HALAMBUR, CHENNAI-126

II) Write notes on :

Jaundice

5) Shock

Shock may be defined as inadequate delivery of oxygen and nutrients to maintain normal tissue and cellular function.

Types:

→ Hypovolemic shock.

→ Cardiogenic shock

→ Septic shock.

Due to low flow : Hypovolemic
Cardiogenic
Obstructive

Due to low peripheral arteriolar resistance.

→ Septic
anaphylactic
neurogenic

Signs & symptoms : Anxiety, restlessness
Hypotension
Rapid, weak thready pulse.
Rapid and shallow respiration
Hypothermia
Dry mouth

Jaundice.

→ Jaundice is yellowish discoloration of skin, sclera and mucous membranes due to hyperbilirubinemia

KATESWARA DENTAL COLLEGE & HOSPITAL
DEPARTMENT OF ORAL MEDICINE D'AGNOSIS & RADIOLOGY

Types.

Jaundice

- **Prehepatic jaundice** → Arising from blood before it enters liver. → Serum total bilirubin 0.3 — 1.0 mg/dL.
- **Intrahepatic** → Due to disease of Liver parenchyma → Serum total bilirubin 0.3-20mg/dL.
- **Post hepatic** → The result of obstruction of biliary tree outside Liver → Serum total bilirubin 100-750 μmol/L

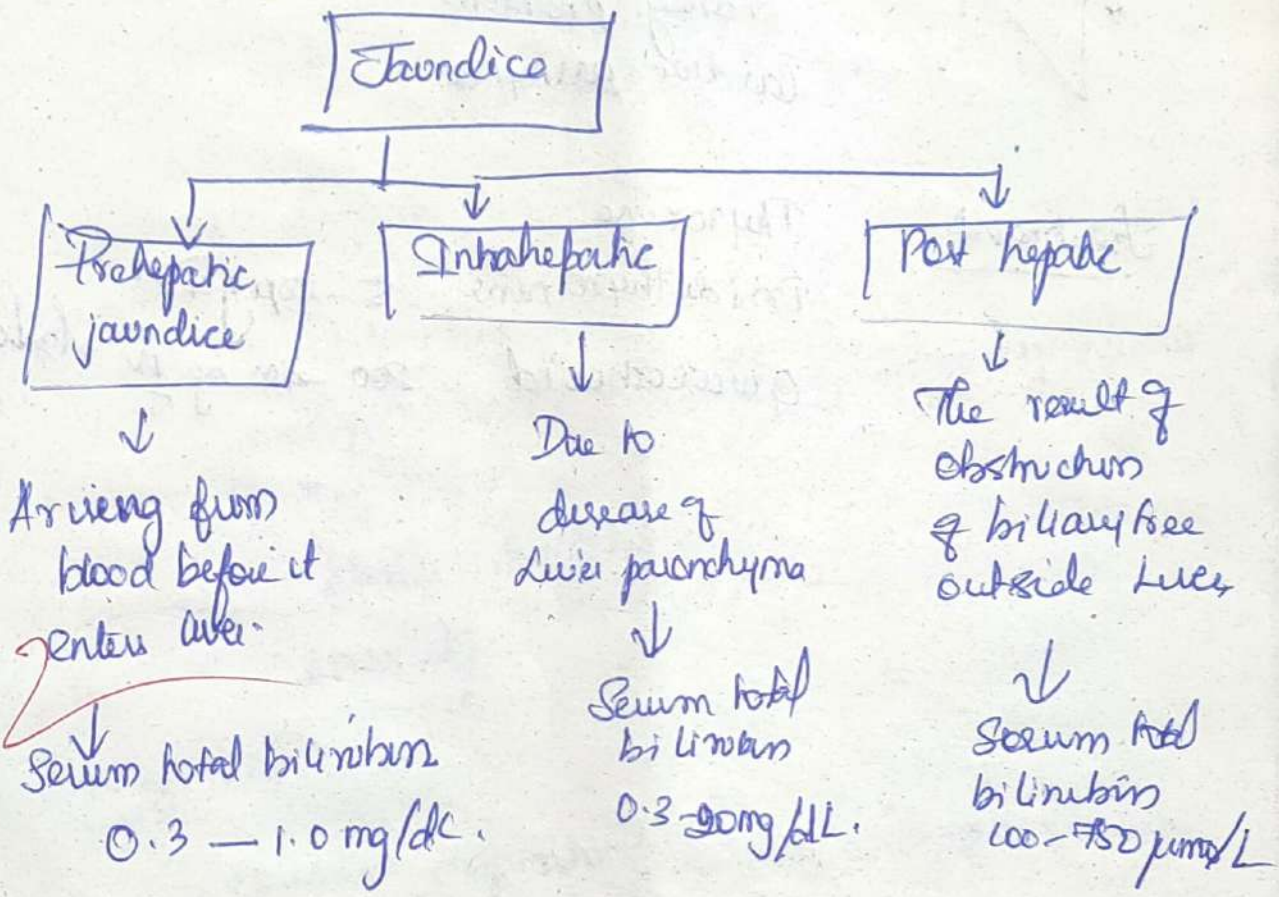

A) Myxoedema.

Myxoedema coma is defined as severe hypothyroidism leading to decreased mental status, coma, hypothermia.

Signs & Symptoms : 1) Hair dry coarse, sparse.
2) Lateral eyebrows thin

5) Periorbital edema.

4) Puffy face.

Complications: 1) Depression
Heart attack
Heart failure
Kidney problem
Cardiac arrhymea.

Treatment: Thyroxine
Triiodothyronine 5-20μg IV.
Glucocorticoid 200-400 mg IV daily

us asthmaticus.

SRI VENKATESWARA DENTAL COLLEGE & HOSPITAL
DEPARTMENT OF ORAL MEDICINE, DIAGNOSIS & MAXILLOFACIAL RADIOLOGY
THALAMBUR, CHENNAI.

→ Severe bronchospasms that doesn't respond to aggressive therapies

Contributing factor 1) Infection
2) Inhalation of air pollution
3) Allergen.

Clinical feature

Tachypnea.
Suprasternal retraction of accessory muscles of respiration
Muscle twitching
Anxiety.

Management

→ Monitor respiratory rate & oxygen saturation

General Medicine - Remedial test

Roshini

III yr BDS

VENKATESWARA DENTAL COLLEGE & HOSPITAL
DEPARTMENT OF ORAL MEDICINE, D'AGNOSIS & MAXILLOFACIAL RADIOLOGY
NALANDAM, CHENNAI-100

1) Cardiac failure

* Heart failure is a clinical syndrome in which the heart is not able to pump adequate amount of blood to meet the metabolic demands of the body

⇒ causes of heart failure:-

* Ischemic heart disease
* cardiomyopathy
* Myocarditis
* Valvular heart disease
* congenital heart disease.

32/70

⇒ Precipitating factors:-

* Infection
* Arrhythmias
* Myocardial ischemia
* Anemia
* physical stress

⇒ Pathophysiology:-

* Heart failure → low cardiac output
↓
Activates mechanisms:-
↓
→ * Activation of Renin, (RAAS) sys.
→ * ↑ sympathetic stimulation

⇒ signs & symptoms:

Symptoms:-

* Dyspnea
* Orthopnea
* Pink frothy sputum
* Right upper quadrant pain

Signs:-

* Physical examination:-
→ Tachycardia
→ Pulses alterans
→ Elevated jugular venous pressure
→ Bilateral pitting edema

⇒ Abdomen:-
* Ascetis
* Tender hepatomegaly

⇒ Pulmonary-
* Wheezing
* Crepitation
* Pleural effusion

⇒ Cardiac:-
> Cardiomegaly
> S_3

⇒ Types of heart failure:-
→ Acute or chronic heart failure:-

Acute heart failure:-
→ Massive MI,
→ Acute infective endocarditis

Chronic heart failure:-
→ Valvular heart disease
→ Cardiomyopathy.

→ Right or left or biventricular heart failure
* Left heart failure:-
causes:-
→ Aortic regurgitation
→ Mitral regurgitation
→ Aortic stenosis.

leads to pulmonary congestion.
- Dyspnea, orthopnea.

* Right heart failure:-
features > tender hepatomegaly.
> Raised JVP.
> Pedal Edema.

* Right ventricular failure can be secondary to pulmonary circulation.
* Cor pulmonale also causes right ventricular failure.

SRI VENKATESWARA DENTAL COLLEGE & HOSPITAL
DEPARTMENT OF ORAL MEDICINE, DIAGNOSIS & MAXILLOFACIAL RADIOLOGY
HALAMBUR, CHENNAI

⇒ Forward or backward heart failure:-
→ Cardiac output – Inadequate in forward failure.
→ backward failure:- Salt & water retention

⇒ Systolic or diastolic heart failure:-
* Systolic heart failure:- Due to impaired myocardial contraction
* Diastolic heart failure:- Due to failure of ventricle to relax.

⇒ High output or low output heart failure:-
→ High out put:- > hyperthyroidism
> Anemia
> Pregnancy
→ Low cardiac output:- hypertension
valvular disease

Investigation:-
* Blood tests:- > Hb test.
> thyroid function tests
* ECG:- Arrythmia, chamber enlargement
* Echocardiography
* BNP levels.

Treatment:-

→ Correction of underlying cause

→ Removal of precipitating factors

→ Control of congestive heart failure.

① ⇒ Correction:-

⇒ ↓ salt & fluid intake

~~⇒ Ans~~

② Drugs:-

* Diuretics:-

→ Thiazide diuretics:-

→ Loop diuretics

* Vasodilators:-

> Oral:-

ACE inhibitors,

→ Ionotropic agents

→ β blockers

2) Anemia:-

1. Classification:-

→ Hypoproliferative:-

* Normocytic normochromic

* Bone marrow failure

* Bone marrow invasion

→ Maturation defect RBC

* Nuclear defect: B12 def, folic acid def

* Cytoplasm defect :- Thalassemia, Sideroblastoblastic anemia

SRI VENKATESWARA DENTAL COLLEGE & HOSPITAL
DEPARTMENT OF ORAL MEDICINE, DIAGNOSIS AND MAXILLOFACIAL RADIOLOGY
THALAMBUR, CHENNAI

→ Hemolytic anemia:-

* Intrinsic defect:- Hereditary spherocytosis
G6PD deficiency & sickle cell anemia

* Extrinsic defects: Malaria

⇒ Hemolytic anemia;

* Due to premature destruction of RBC & failure of the bone to replacement it.

* Extravascular or Intravascular

* Hemoglobin released from RBC breakdown
  - → Bounds to plasma protein haptoglobin
  - → Bounds to Albumin:- Methalbumin
  - → free hemoglobin → passes through renal glomerule → passed in urine (hemosiderinuria) or (haemoglobinuria)

* Unconjugated Bilirubin → raised.

⇒ Hemoglobinopathy:-

→ HbA → $\alpha_2\beta_2$ (major) or $\alpha_2\delta_2$ (light)

⇒ HbF → $\alpha_2\gamma_2$

* β thalassemia major → Cooley's anemia.
→ transfusion dependent
→ fatal.
* β thalassemia minor.

* severe thalassemia :- Expansion of bone marrow (extramedullary haematopoiesis)
* Sickle cell anemia :- mutation in β globin chain that replaces 6th aminoacid from glutamic acid to valine.

⇒ clinical features :-
* Anemia, mild jaundice, splenomegaly
* Hemoglobinuria
* DVTs.

⇒ Investigations :-
→ Peripheral blood smear — hemolytic features :- Anisocytosis, poikilocytosis
→ Reticulocyte count ↑ increased.
→ Serum haptoglobin is decreased
→ Urine examination
→ Haemoglobin electrophoresis

⇒ Treatment :-
* Bone marrow transplantation
* Splenectomy
* Steroids.

SRI VENKATESWARA DENTAL COLLEGE & HOSPITAL
DEPARTMENT OF ORAL MEDICINE, DIAGNOSIS & MAXILLOFACIAL RADIOLOGY
HALAMBUR, CHENNAI-103

1) Status Asthmaticus

⇒ Acute severe Asthma:

→ * life threatening condition

* It is inflammation & increased responsiveness to a wide variety of stimuli.

→ Examination:-

* tachycardia

* Pulsus paradoxus

* Cyanosis

* Use of active accessory respiratory muscles

→ Air entry is reduced (silent chest)

→ Investigations:-

* PEV, $\frac{FEV_1}{VC}$ ratio is reduced

* chest X-ray → Appears hyperinflated

* Arterial blood gas analysis:- PCO_2 is low.

* Peripheral blood smear → Eosinophilia.

Treatment of status Asthmaticus:-

1- Hospitalization of oxygen therapy:-

2- Repeated dosage of short acting adrenergic drugs (Salbutamol 2.5-5mg)

3- Systemic steroids

4- Mechanical ventilation

5- IV fluid.

2) Jaundice

→ 3 types of Jaundice:-

⇒ Prehepatic (hemolytic)

⇒ Hepatic (Hepatocellular)

⇒ Posthepatic (obstructive)

Prehepatic:- Due to hemolytic disorder such as hereditary spherocytosis, sickle cell anemia, G6PD deficiency, paroxysmal nocturnal hemoglobinuria.

* Rubin Johnson syndrome

→ Hepatocellular disease

→ cholestatic jaundice

3) Complication of Diabetics

Acute complication:-

* Diabetic Ketoacidosis (DKA)

* Hyperglycemic hyperosmolar state

→ Macrovascular:-

→ Coronary artery disease

→ Cerebrovascular disease

→ Peripheral vascular disease

SRM DENTAL COLLEGE & HOSPITAL
DEPARTMENT OF ORAL MEDICINE, DIAGNOSIS & MAXILLOFACIAL RADIOLOGY
SRM, HALAMBUR, CHENNAI-103

→ Non vascular

* Dermatologic.

* Gastrointestinal

→ Infections:-

* Cataract & glaucoma.

4) myxoedema:

* Primary disorders of thyroid gland

* Clinic features are altered sensorium, hypothermia, hypoglycemia, hyperventilation, hypoxia, hyponatremia & hypotension.

→ Coma is induced by infections, cold exposure & systemic illness.

Treatment:-

* IV administration of levothyroxine

* Parenteral T4 - 10-25 µg

* Antibiotics

* 50-100mg Hydrocortisone - IV / IM

5) Shock:-

Clinical syndrome when the O_2 deliv
fails to meet the metabolic requirements
of tissues, due to reduced tissues perfus

→ ↓ delivery of O_2 & Metabolic.

Classification:-

* Hypovolemic
* Cardiogenic.
* Septic.
* Anaphylactic
* Traumatic
* Hypoadrenal.

→ It may be caused by-

* a. Hemorrhage.
* b. loss of fluid from GI tract.
* c. Urinary loss.
* d. sequestration of fluid

6) Herpes Zoster.

* Herpes Zoster is due to reactivation of latent Varicella-Zoster varies from dorsal root ganglion. Its incidence is highest in 6th decade.

clinical features

* Initially erythematous, maculopapular evolves into 6 pustules

* Thoracic & lumbar roots ✓ involved.

* Rashes subsides in 1 - 2 weeks

* Immunocompromised patients are more prone.

* Along V3 nerve

* Associated with Ramsay - Hunt-Syndrome

Complications:-

* Post-herpetic neuralgia.
* Meningitis
* Encephalitis

Treatment:-

* Acyclovir - 800 mg
* Valacyclovir
→ famicyclovir.

SRI VENKATESWARA DENTAL COLLEGE & HOSPITAL
DEPARTMENT OF ORAL MEDICINE, DIAGNOSIS & MAXILLOFACIAL RADIOLOGY
THALAMBUR, CHENNAI-103

7) Scurvy:-

* Deficiency of Vitamin C occurs in poor, elderly & chronic alcolic.

Vitamin C deficiency — impaired functions of connective tissues

* Clinical features include :-

* Petechiae.
* Ecchymosis
* swollen.
* Bleeding gums.
* Hernia
* Poor wound healing.

8) HIV transmission :-

→ most common mode of transmission of HIV is heterosexual contact. (85-90%)

→ mostly through unsafe sex.

→ other modes of transmission are through contaminated blood or blood products, contaminated syringes

→ IV drug abusers & from infected mother to foetus.

→ Transmission of HIV from mother to child occurs through breastfeed

→ study saliva, tear shown to spread infection

18/22 General Medicine

Vijayapriyadharshini
IIIrd yr BDS

SRI VENKA... DENTAL COLLEGE & HOSPITAL
DEPARTMENT OF ORAL MEDICINE, DIAGNOSIS & MAXILLOFACIAL RADIOLOGY
HALAMBUR, CHENNAI-103

36/70

I. Elaborate on :

1. Discuss the Etiology, classification, clinical features, investigations & treatment of cardiac failure.

Heart Failure is defined as

"A complex clinical syndrome results from any structural/functional impairment of ventricular filling (or) ejection of blood.

Heart failure — Systolic
— Diastolic.

- Systolic Heart failure : characterized by reduced ejection fraction and enlarged ventricle size. (present with left ventricular failure & marked cardiomegaly).
- Diastolic Heart failure : characterized by increased resistance to filling due to increased filling pressures. (present with pulmonary congestion with normally enlarged ventricles).

Heart Failure :
- Right side
- Left side
- Forward
- Backward

Right Side Heart Failure : characterised by presence of
- Peripheral Edema
- Raised JVP
- Hypotension
- Congestive hepatomegaly.
-

Lt sided Heart failure : Pulmonary Edema is main feature + other signs are tachypnea, tachycardia, 3rd heart sound, pulsus alternans

Congestive cardiac failure : combination of both (Left & Right sided heart failure).

Forward Heart failure :

Inadequate discharge of blood into arterial system leading to poor tissue perfusion + excess Na+ reabsorption.

Backward Heart failure :

This results from failure of one or both ventricles to fill normally and discharge, causing back pressure on atria & venous system.

Risk Factors :

- Coronary Artery Disease (Infarction / Ischemia)
- Chronic pressure overload (Hypertension / valvular Heart Disease).

Clinical Features :

* Fatigue
* Exertional Breathlessness.

Cause of Breathlessness :

1. Pulmonary congestion due to LVF
2. Reed pulmonary Compliance
3. Increased Airway Resistance
4. Respiratory fatigue & Anemia.
5.

Orthopnea :

- Dyspnea in recumbent position
- Increase in pulmonary capillary pressure
- No nocturnal cough present
- Relieved by sitting upright
- This symptom is more common in patients with obesity.

SRI VENKATESWARA DENTAL COLLEGE & HOSPITAL
DEPARTMENT OF ORAL MEDICINE, DIAGNOSIS & MAXILLOFACIAL RADIOLOGY
HALAMBUR, CHENNAI-103

* Paroxysmal Nocturnal Dyspnea :

⇒ Episode of shortness of breath + coughing at night for 1-3 hrs
⇒ Associated with coughing or wheeze.
⇒ Orthopnea symptoms resolve after upright posture.

* Cheyne stokes respiration :

→ Also called periodic / cyclic respiration.

Other symptoms like :

* Anorexia, Nausea, Early satiety, Abdominal pain.

Physical Examination :

* Jugular venous pressure → Normal < 8 cm of H_2O.
* Expiratory wheeze (Cardiac Asthma)
* pleural effusion may / may not be present.

→ Atrial fibrillation
→ Anemia.

Other Symptoms :

- Diabetes
- Arthritis
- CKD
- COPD :

2) Define and classify Anemias. Discuss about clinical features, investigations & treatment of Hemolytic Anemias.

HEMOLYTIC ANEMIA:

Increased red cell destruction (life span of RBC < 15 days).

Red cell destruction occurs by 2 mechanisms :-

* Extravascular Hemolysis:

The site of destruction is spleen. Red cells are taken up by the cells of RE-system.

* Intravascular Hemolysis:

This is the minor pathway of red cell destruction & red cells reduced in circulation releasing hemoglobin.

Extravascular Hemolysis :

Senescent red cells

↓

Phagocytosed by RE cells of spleen.

↓

Hemoglobin released in RE cells → Heme + Globin

↓

Heme breaks down into iron + protoporphyrin.

Iron in plasma carried as transferrin → carried to iron storage sites like bone marrow → Iron stores.

↓

Bilirubin

↓

Urobilinogen / stercobilinogen.

Intravascular Hemolysis

Red cells in Destruction

↓

Red cells lyse in circulation

↓

Hemoglobin in plasma → Haptoglobin

↓

Hb in Urine

Hemoglobinemia

↓

Hemosiderinuria

↓

Detected in urinary Deposit by perls stain

SRI VENKATESWARA DENTAL COLLEGE & HOSPITAL
DEPARTMENT OF ORAL MEDICINE, DIAGNOSIS & MAXILLOFACIAL RADIOLOGY
HALAMBUR, CHENNAI

Hemolytic Anemia → Hereditary

→ Acquired

Hereditary :

1. Defects in red cell Membranes
   - Hereditary Spherocytosis
2. Defects in globin synthesis
   - Sickling syndromes
   - HbE disease
3. Enzyme deficiency of glycolytic pathway
   - pyruvate kinase deficiency
   - Hexokinase deficiency
4. Enzyme deficiency of pentose phosphate pathway
   - G-6-P-D deficiency

Acquired Hemolytic Anemia :

1. Immunohemolytic Anemia
   - Autoimmune → Due to warm antibodies
     → Due to Cold Antibodies.
2. Fragmentation syndromes
   - Hemolytic Uremic Syndrome

3. Paroxysmal nocturnal hemoglobinuria

4. Drugs & chemicals

* Oxidant drugs, Primaquine, Dapsone.

5. Thermal injury

6. Infections

* Cholera

7. Others.

DEPARTMENT OF ORAL MEDICINE, DIAGNOSIS & MAXILLOFACIAL RADIOLOGY

Findings in Hemolytic Anemia:

* pallor, Jaundice, splenomegaly
* polychromatosis, Hemoclysis.
* Erythroid hyperplasia in bone marrow.

Clinical Features:

* Anemia
* Splenomegaly
* Gall stone
* chronic leg ulcers.

Investigations:

→ Incubated Fragility test

→ Glycerol lysis test.

Enzymatic Deficiency:

* G6PD deficiency
* Pyruvate kinase deficiency

Hemoglobinopathies:

Thalassemia

* classification:

→ T. Major

→ T. Intermedia (α-β-Thalassemia).

Clinical presentation of Thalassemia :

* Anemia
* Mild Jaundice
* Leg ulcer

SRM DENTAL COLLEGE & HOSPITAL
DEPARTMENT OF ORAL MEDICINE, DIAGNOSIS & MAXILLOFACIAL RADIOLOGY
HALAMBUR, CHENNAI-603

Lab tests → Tear drop cell & nRBC
→ Target cells

* Bone marrow.

Sickling Syndrome :

* Sickle cell Anemia - HbS-HbS
* Sickle cell trait - HbA-HbS

Clinical features : * Recurrent leg ulcers.
* Jaundice.

Short notes :

1) Status Asthmaticus :

Pathophysiology

* Irritable & Damaged Airway.

→ Hypersecretion
→ Epithelial Damage with exposed nerve endings
→ Hypertrophy of goblet cells & mucosal glands.

Smooth Muscle spasm

Airway Edema

Mucous plugging

Risk factors :

→ Medical : Rapid / severe deterioration.
→ Denial, non-compliance
→ Family fear of inhalers.

* Lung Mechanics:

+ Hyperinflation
+ Hypoxemia

Severe air flow obstruction → Incomplete exhalation → Increased lung volume

Expanded Airway → Used expiration

Fixed plasticity → Fixed expiratory flow.

Used expiration + Fixed expiratory flow → Hyperinflation.

Types of Exacerbation:

→ Mild Asthma
→ Dyspnea usually limits activity
→ severe exacerbation
→ life threatening exacerbation.

Chest x-ray:

→ Patient is intubated / ventilated.
→ Suspected pneumonia.

Management:

→ O2 - 100% warm.
→ Systemic Corticosteroid.
→ 2 intravenous Line.
→ Adrenergic Agonists.
→ Ketamine
→ Heliox.

Complications of Diabetes Mellitus:

SRI VENKATESWARA DENTAL COLLEGE & HOSPITAL
DEPARTMENT OF ORAL MEDICINE, DIAGNOSIS & MAXILLOFACIAL RADIOLOGY
HALAMBUR, CHENNAI-103

* Acute (Metabolic)
* chronic (Angiopathy)
  - Macro vascular
  - Micro vascular

Risk Factors:

- Microvascular Diseases (Eyes, kidneys, Nerves)
- Macrovascular diseases
  - Peripheral vascular Disease
  - Ischaemic heart disease
  - stroke
- Dyslipidemia
- Smoking
- Coagulopathy

→ 1. Hyperglycemia
→ 2. Hypertension

Acute Complications:

* Diabetic ketoacidosis
* Hypoglycemia

Hyperglycemia
- Eye (Retinopathy)
  - Cataract
  - Glaucoma
  → Blindness
- kidney (Nephropathy)
  - Microalbuminuria
  - Gross albuminuria
  → kidney Failure
- Nerves (Neuropathy)
  - peripheral
  - Autonomic → Amputation

→ DEATH AND/OR DISABILITY

Mechanism of complications :



Chronic Complications :

* Hyperglycemia.

---

4) Myxoedema :

→ It refers to a severe form of hypothyroidism - ~~Heat~~

Clinical features :

* Central Nervous system

→ Confusion
→ Apathy
→ Psychosis
→ Deterioration in mental state is the cardinal symptom.

* Metabolic

→ Reduced metabolic rate causes weight gain, growth reduction, lower energy production.
→ Hypothermia (core temperature <35.5°C is common)
→ Respiratory acidosis, hypoxia & hypercapnia are common.

* Skin

→ Dry, cool & doughy skin, non-pitting edema of hands and feet.
→ Hair loss (Alopecia).

Cardiovascular:

- Bradycardia & reduced Cardiac Output
- Pericardial effusion
- Reduced Heart sounds and reduced apical impulse

SRI RAMACHANDRA DENTAL COLLEGE & HOSPITAL
DEPARTMENT OF ORAL MEDICINE, DIAGNOSIS & MAXILLOFACIAL RADIOLOGY
PORUR, CHENNAI-116

5) Shock:

Shock is a physiologic event with many different causes --
Mortality Rate - 20%.

Definition: It is a life threatening situation due to poor tissue perfusion with impaired cellular metabolism.

Stages of shock:

1. Non-Progressive (Reversible shock)
2. Progressive Decompensated shock
3. Decompensated (Irreversible) shock

Pathophysiology:

* Hypovolaemic Shock

- Effective Circulating Blood Volume.
  - * Hemorrhage
  - * Trauma
  - * Surgery
  - * Burns
  - * Dehydration

* Septic shock

- * Gram -ve Septicemia
- * Gram +ve Septicemia

* Cardiogenic shock

* Deficiency of Emptying, filling, outflow obstruction.

Hypovolemic Septic Cardiogenic

- ↓ Effective circulating blood volume
- ↓ venous return to Heart
- ↓ cardiac output
- ↓ Blood flow
- ↓ supply of O_2
- ↓ Anoxia
- Shock

Clinical features :

- Hypotension (Systolic BP < 100mm Hg)
- Tachycardia (>100/min)
- Cold, clammy skin
- Rapid, shallow Respiration
- Drowsiness, Confusion, Irritability
- Multi-Organ failure

Effect of Shock : Respiratory : Metabolic Acidosis.

Renal + Endocrine : Decreased Urine output

Ischemic Reperfusion Syndrome :

- It is the injury that occurs once the normal circulation is restored to the tissues.

Reasons : * Acid & potassium load → MI depression, hypotension.

Results :

* Acute lung injury
- Multiple Organ failure
- Death.

Herpes Zoster :

- Also known as Shingles
- caused by Varicella Zoster virus that causes chicken pox

Shingles → As band of blisters on one side of chest / back but it can occur anywhere including face

SRI VENKATESWARA DENTAL COLLEGE & HOSPITAL
DEPARTMENT OF ORAL MEDICINE, DIAGNOSIS & MAXILLOFACIAL RADIOLOGY
THALAMBUR, CHENNAI-103

Varicella Zoster virus :

- Varicella (chicken pox)
- Herpes Zoster (shingles)

Causes & Risk factors :

Age : common in >50 yrs

Diseases : weaken immune system, (HIV / AIDS & Cancer)

Cancer Treatments : Undergoing Radiation / chemotherapy

Immunosuppressant Drugs : Steroids (prednisone)

Clinical Symptoms :

* Headache
* Feeling unwell
* Myalgia
* Fever

Acute stage : - Itching / tingling sensation
- Fluid filled blisters & painful rash

Complications :

1- Post herpetic Neuralgia
2- Ophthalmic Shingles
3- Ramsay Hunt Syndrome
4- Encephalitis
5- Hearing problems

Management : * Acyclovir
* Valacyclovir
* Famciclovir

7) Scurvy:

Vit-C - known as Ascorbic Acid - is a water-soluble vitamin.

Functions: * Synthesis of collagen, neurotransmitters
* Regenerate other antioxidants such as vit-E
* Vit-C required for synthesis of carnitine

Scurvy: → Cardiovascular disease
→ Stroke
→ Cataracts
→ Lead toxicity

People at risk of scurvy:

* Alcoholics
* Elderly
* Children
* Malabsorption disorders
* Severe dyspepsia
* Dialysis patients

Diagnosis: (Signs + Symptoms)

→ Weakness / fatigue
→ Hair + teeth loss & gingivitis
→ Bleeding + breaking blood vessel.

Complications:

* Skin problems (Ecchymoses)
* Oral problems (Gum problem) (soft + spongy)
* Musculoskeletal (Bleeding in joints)
* Heart + lung (shortness of breath)

Treatment & Prevention:

→ Adult dose (800-1000 mg/day) at least 1 week of vit-C.

HIV Transmission:

→ A unique type of retrovirus.
→ Threatening a global epidemic

SRM VENKATESWARA DENTAL COLLEGE & HOSPITAL
DEPARTMENT OF ORAL MEDICINE, DIAGNOSIS & MAXILLOFACIAL RADIOLOGY
HALAMBUR, CHENNAI-103

Modes of Transmission:

- Blood products
- semen
- vaginal fluids.

Intravenous Drug Abuse:

- sharing needles
- Unsterilized blades.

Mother to baby
- Before birth
- During birth.

Transmission of HIV occurs by various methods, also.

---

9) ### Anaphylaxis:

• Allergic reactions.

→ Sensitivities to substances called allergens that come in contact with skin, nose, eye, RT + GI tract.

Types of hypersensitivity:

~~Type-I~~ 2 : Immediate hypersensitivity
Type-II : Cytotoxic "
Type-III : Immune Complex "
Type-IV : Delayed "

Type-I : IgE mediated
→ classic Allergy

Type-II : IgG / IgM mediated
→ RBC lysis

Type-III : IgG mediated
→ Immune Complex Disease

Type-IV : → cell
Delayed type hypersensitivity.

→ It is a sudden, severe allergic, life-threatening → emergency case.
(Type-I)

Etiology :

* Our immune system produce antibodies that defend against foreign substances.

Causes of Anaphylactic Shock :

→ Medications, penicillin
→ Foods (fish, walnuts)
→ Insects (bees, wasps).

Pathophysiology :

- Primary exposure
- Re-exposure

Anaphylactic rxn :

Antigen → B-cell → IgE bind to surface mast cell → Antigen bridges the cap
↓
Histamine ↑ses permeability.

Investigation :

- Allergy test (patch test)

Treatment :

* Epinephrine
* O_2
* IV (Anti histamine + Cortisone)
* Albuterol.

Antihypertensive Drugs:

* Diuretics

→ Thiazides
→ Spironolactone

* ACE inhibitors

→ Captopril, Enalapril

* Angiotensin blockers

→ Losartan, Candesartan, Telmisartan

* Direct renin inhibitors

* β Adrenergic blockers

→ Propanolol, Atenolol etc.

* Ca-Channel Blockers

→ Nifedipine, Nifeendipine.

* Vasodilators

→ Minoxidil.

*

Complications of Hypertension:

* Brain stroke
* Vision loss
* Heart Attack
* Bone loss
* Kidney failure
* Blood vessel Damage.

Balaganesh
III rd year BDS

SRI VENKATESWARA DENTAL COLLEGE & HOSPITAL
DEPARTMENT OF ORAL MEDICINE, DIAGNOSIS & MAXILLOFACIAL RADIOLOGY
AMBUR, CHENNAI-105

20/10

Etiology:

Cardiac failure is a coronary artery disease is the most common form of heart disease. It results from the build up of fatty deposits in the arteries which reduces blood flow and can lead to heart attack. cardiac failure can be due to

- unhealthy diet
- physical inactivity
- tobacco use
- harmful use of alcohol.

Classification:

It is classified in to

- class I
- class II
- class III
- class IV

SRI VENKATESWARA DENTAL COLLEGE & HOSPITAL
DEPARTMENT OF ORAL MEDICINE, DIAGNOSIS & MAXILLOFACIAL RADIOLOGY
HALAMBUR, CHENNAI-103

Class I

cardiac disease but no symptoms and no limitation in ordinary physical activity

Class II: Mild symptoms and slight limitation during ordinary activity

Class III:

Significant limitation in activity due to symptoms comfortable only at rest

Class IV:- Severe limitations symptoms even while at rest.

Clinical features:

- Dyspnea
- PND
- Orthopnea
- Fatigue
- Palpitations
- Dependent edema
- cachexia
- Elevated Jugular venous pressure
- Third heart sone
- Basal crepitations
- Tender hepatomegaly

SRI VENKATESWARA DENTAL COLLEGE & HOSPITAL
DEPARTMENT OF ORAL MEDICINE, DIAGNOSIS & MAXILLOFACIAL RADIOLOGY
HALAMBUR, CHENNAI-103

Investigation:

- ECG
- chest xray
- Blood investigations
- transthoracic echocardiography
- Blood BNP.

Treatment:

pharmaceutical treatments:

- β-blockers
- cardiac resynchronization therapy

Surgical treatment:

- coronary bypass surgery.
- Mitral valvuloplasty
- Left ventriculoplasty
- Regenerative therapy
- Heart transplantation
- ventricular assist devices.

DEPARTMENT OF MEDICINE, DIAGNOSIS & MAXILLOFACIAL RADIOLOGY

Anemia is a condition in which you lack enough healthy red blood cells to carry adequate oxygen to your body's tissues it also refers to as low hemoglobin can make you feel tired and weak.

Classification

It is classified in to

- Microcytic
- Normocytic
- Macrocytic anemia

Microcytic anemia:

- Iron deficiency Anemia
- Thalassemia
- Sideroblastic anemia

SRI VENKATESWARA DENTAL COLLEGE & HOSPITAL
ORAL MEDICINE & DIAGNOSIS
MAXILLOFACIAL RADIOLOGY
HALAMBUR, CHITTOOR

Normocytic anemia:
Reticulocyte count.

low:
- Marrow failure
- Aplastic anemia
- leukemia
- Myelofibrosis

High:
- Sickle cell anemia
- Hemolytic anemia

Micro cytic anemia:
- Megaloblastic anemia
  - B12 deficiency
  - Folate deficiency

Hemolytic anemia:
Clinical features:
- weakness
- Pallor
- Jaundice
- dark-colored urine
- fever

- Inability to do physical activity
- Heart murmur

Investigation:

- CBC
- Bone marrow aspiration
- Biopsy
- urine test

Treatment

- Blood transfusion
- Medications
  - Glucocorticoids
    - prednisone
- Blood and marrow stem cell transplants
- Lifestyle changes.
- For patients with mild hemolytic anemia, may not need treatment as long as the condition doesn't worsen.

SRI VENKATESWARA DENTAL COLLEGE
DEPARTMENT OF ORAL MEDICINE, DIAGNOSIS & MAXILLOFACIAL RADIOLOGY
HALAMBUR, CHENNAI

(17.

Status asthmaticus:

It is a medical emergency an extreme form of asthma exacerbation characterized by hypoxemia, hypercarbia and secondary respiratory failure

Status asthmaticus indicates acute severe asthma or a severe asthma exacerbation

Symptoms:

- Short, shallow breaths
- wheezing
- coughing
- heavy sweating
- difficulty breathing
- loss of consciousness

causes :

- Stress
- Respiratory infections
- cold weather
- air pollution
- Smoking
- Severe allergic reactions

Treatment :

- Glucocorticosteroids are the most import treatment
  - improve oxygenation
  - decrease mucus production
  - reduce
- betagonist :
  - Albuterol :

- complication of diabetic mellitus :
  - cardio vascular disease
    - Diabetes increase the risk of many heart problems.

SRI VENKATESWARA DENTAL COLLEGE & HOSPITAL
DEPARTMENT OF ORAL MEDICINE, DIAGNOSIS & MAXILLOFACIAL RADIOLOGY
HALAMBUR, CHENNAI-103

- neuropathy
- nephropathy
- Retinopathy
- foot Damage
  Nerve damage or poor blood flow to feet. increases the risk.
- Hearing impairment

2 1/2. Prone to skin problems including Bacterial and fungal infections

- Alzheimer's disease
  Type 2 diabetes may increase the risk of dementia
- Depression

4. Myxoedema.

It is a rare and extreme complication of hypothyroidism with multiple organ abnormalities associated with altered sensorium.

DEPARTMENT OF ORAL MEDICINE, DIAGNOSIS & MAXILLOFACIAL RADIOLOGY
VENKATESWARA DENTAL COLLEGE & HOSPITAL, CHENNAI-103

It can be fatal. Hypothyroid patient exhibit multiple physiologic alterations to compensate for the deficiency of thyroid hormone.

causes:

- undiagnosed or untreated severe hypothyroidism
- can develop when someone stops taking their thyroid medication
- most common is elderly and women.
- deposits of chains of sugar molecules in skin cause skin condition myxedema.

Signs and Symptoms:

- Fatigue
- constipation
- Weight gain
- Cold intolerance

SRI VENKATESWARA DENTAL COLLEGE & HOSPITAL
DEPARTMENT OF ORAL MEDICINE, DIAGNOSIS & MAXILLOFACIAL RADIOLOGY
HALAMBUR, CHENNAI-103

- a deep voice
- coarse hair
- Dry, pale, cool skin

Investigation:

- Total serum thyroxine and free thyroxine Index tests will confirm the diagnosis

treatment:

- Pt should be admitted to intensive care unit and hypovolemia and electrolyte abnormalities corrected.
- Mechanical Ventilation
- Cardio Vascular status should be monitored after intravenous thyroid hormone replacement.

VENKATESWARA DENTAL COLLEGE & HOSPITAL
DEPARTMENT OF ORAL MEDICINE, DIAGNOSIS & MAXILLOFACIAL RADIOLOGY
HALAMBUR, CHENNAI-103

8.

HIV transmission:

It is transmitted via

- The exchange of a variety of body fluids from infected people such as blood, breast milk. ~~[illegible]~~
- It can be transmitted from mother to her child during pregnancy and delivery
- ~~mosquitoes, ticks or other insects~~
- ~~sharing dishes~~
- ~~tears, sweat~~
- use of unsterile needles and syringes.
- Blood transfusion by HIV patients
- organ transplant by HIV patients.

SRI VENKATESWARA DENTAL COLLEGE & HOSPITAL
DEPARTMENT OF ORAL MEDICINE, DIAGNOSIS & MAXILLOFACIAL RADIOLOGY
HALAMBUR, CHENNAI-103

9. Anaphylaxis

It is a severe, potentially life threatening allergic reaction. It can occur within seconds or minutes of exposure to something you are allergic such as peanuts or Bee stings

It is result of the immune system. The body natural defence system overreacting to a trigger.

The reaction is marked by constriction of airways leading to difficult breathing Swelling of the throat. may block airway

JAYAKAMATESWARA DENTAL COLLEGE & HOSPITAL
DEPARTMENT OF ORAL MEDICINE, DIAGNOSIS & MAXILLOFACIAL RADIOLOGY
HALAMBUR, CHENNAI-100

Signs and symptoms

- itching, redness of skin
- swollen eyes, lips, tongue
- coughing
- abdominal pain, nausea, vomitting, diarrhea
- difficulty breathing, throat constriction
- stuffy and runny nose, watery eyes.

Trement

- Epinephrine to reduce body's allergic reaction
- oxygen to help you breathe
- IV antihistamines and cortisone
- Beta agonist

SRI VENKATESWARA DENTAL COLLEGE & HOSPITAL
DEPARTMENT OF ORAL MEDICINE, DIAGNOSIS & MAXILLOFACIAL RADIOLOGY
HALAMBUR, CHENNAI-103

10 Antihypertensive drug II

- Diuretics
- Beta - blockers
- ACE inhibitors
- Angiotensin II receptor blockers
- Calcium channel blockers
- Alpha blockers.
- Alpha - II Receptor agonists
- Combined Alpha and beta blockers.

6. Herpes zoster:

Herpes zoster infection known as shingles which causes outbreak of a painful rash or blisters on the skin. Caused by Varicella zoster virus. which is the same virus that causes chicken pox.

SAVEETHA DENTAL COLLEGE & HOSPITALS
DEPARTMENT OF ORAL MEDICINE, DIAGNOSIS & MAXILLOFACIAL RADIOLOGY
SAVEETHA, CHENNAI-105

It mostly appears as a band or rashes or blisters in one area of your body.

Herpes zoster lesions are infectious, through direct contact with vesicular fluid until they dry and crust over.

Herpes zoster is caused by the reactivation of the chickenpox virus

Signs :

painful rash that develops on one side of the face or body. The rash consist of blisters that typically scab over in 7 to 10 days.

SRI VENKATESWARA DENTAL COLLEGE & HOSPITAL
DEPARTMENT OF ORAL MEDICINE, DIAGNOSIS & MAXILLOFACIAL RADIOLOGY
HALAMBUR, CHENNAI-103

Treatment:

- Several antiviral medicines
- acyclovir, valacyclovir, famciclovir

7. Scurvy:

It occurs when you have severe lack of vitamin-c in your diet.

Symptoms:

- weakness
- anemia.
- gum disease
- skin haemorrhages
- Older adults who are not getting proper nutrition is mostly affected
- Develops red or blue spots on the skin

SAVEETHA DENTAL COLLEGE & HOSPITAL
DEPARTMENT OF ORAL MEDICINE, DIAGNOSIS & MAXILLOFACIAL RADIOLOGY
CHENNAI-600 077

Treatment:

It can be treated with:

Oral or Intravenous

Vitamin C supplements

GENERAL MEDICINE

REMEDIAL TEST

Sapnasupriya

14 yr BDS

SRI VENKATESWARA DENTAL COLLEGE & HOSPITAL
DEPARTMENT OF ORAL MEDICINE, DIAGNOSIS & MAXILLOFACIAL RADIOLOGY
HALAMBUR, CHENNAI-103

28/70

1. Heart Failure

Heart failure is a clinical syndrome where heart is unable to pump enough blood.

Causes

-> Ischaemic heart disease
-> cardiomyopathy
-> Myocarditis
-> Valvular heart disease
-> Hypertensive heart disease

Precipitating factors

-> Infection
-> Arrhythmia
-> MI
-> Anemia
-> Stress

Pathophysiology

Heart failure ⟶ ↓ cardiac output
↓
Activates ① RAAS
② ↑ sympathetic stimulation

Signs & symptoms.

Symptoms:-

* Dyspnea
* Orthopnea
* Paroxysmal nocturnal dyspnea
* Right upper quadrant pain

Signs:-

→ Tachycardia
→ pulsus alternans
→ elevated jugular venous pressure
→ Bilateral pitting edema
→ Abdomen
  → Ascites
  → Tender hepatomegaly

Types of heart failure.

→ Acute or chronic heart failure
→ Acute heart failure
  Massive MI
  Acute infective endocarditis

chronic heart failure
  → Valvular heart disease
  → Cardiomyopathy

ight, or left or biventricular heart

failure

* Left heart failure causes

→ Aortic regurgitation

→ Mitral regurgitation

→ Aortic stenosis

leads to pulmonary congestion → Dyspnea, orthopnea

* Right heart failure

→ Tender hepatomegaly

→ ↑ JVP

→ pedal edema

Forward or backward heart failure

Systolic or diastolic heart failure

High output or low output failure

Investigations

- Blood cell

ECG

Echocardiography

Brain natriuretic peptide

SRI VENKATESWARA DENTAL COLLEGE & HOSPITAL
DEPARTMENT OF ORAL MEDICINE, DIAGNOSIS & MAXILLOFACIAL RADIOLOGY
HALAMBIYAR, CHENNAI-103

Treatment

SAVEETHA DENTAL COLLEGE & HOSPITAL
DEPARTMENT OF ORAL MEDICINE, DIAGNOSIS & MAXILLOFACIAL RADIOLOGY

- Correction of the underlying cause of the precipitating factors
- Control of congestive heart failure

(1) Correction

→ ↓ salt & fluid intake

→ ↓ activity

- Arrhythmia
- Infection
- Drugs

(2) Control Drugs

Diuretics

Vasodilators

Inotropic agents

β blockers

SRI VENKATESWARA DENTAL COLLEGE & HOSPITAL
DEPARTMENT OF ORAL MEDICINE, DIAGNOSIS & MAXILLOFACIAL RADIOLOGY
HALAMBUR, CHENNAI-103

Anemia

Classification

a) Hypoproliferative

Normocytic normochromic ↓ RBC

→ Bone marrow failure

→ Bone marrow invasion

b) Maturation defect of RBC:

→ Nuclear defect - B_{12} def, folic acid def.
(Macrocytic)

→ Cytoplasm defect :- Thallasemia, sideroblastic anemia
(microcytic)

c) Hemolytic anemia

1. Intrinsic defect :- Hereditary spherocytosis, G6PD deficiency & sickle cell anemia

2. Extrinsic defect :- Malaria

d) Hemorrhagic anemia

Hemolytic anemia

due to premature destruction of RBCs and failure of the bone to replenish it

Hemolysis may be intravascular and extravascular

Hemoglobinuria

Classification

Congenital (intrinsic)

① Membrane defect - Hereditary spherocytosis & elliptocytosis

② Hemoglobinopathies - Thalassemia, Sickle cell anemia

③ enzyme defect - G6PD deficiency

Acquired

① Immune.

② Non immune.

ⓐ Mechanical - DIC

ⓑ Malarial

ⓒ PNH (immune)

Clinical features

- Anemia
- Knee clicks
  gall stones
  Hemoglobinuria

Investigation

Peripheral blood smear

b) Reticulocyte count

c) Bone marrow examination

d) Serum unconjugated bilirubin

e) Urine

f) Serum creatinine, urea

Treatment 6

a) Bone marrow transplantation is curative in thalassemia

b) Sickle cell anemia

b) Splenectomy → hereditary spherocytosis

c) Steroids → other autoimmune ailments

d) Factors precipitating hemolysis should be avoided.

Short notes

1) Status Asthmaticus

It is a life threatening condition of Asthma which requires immediate treatment

SRI VENKATESWARA DENTAL COLLEGE & HOSPITAL
DEPARTMENT OF ORAL MEDICINE, D'AGNOSIS & MAXILLOFACIAL RADIOLOGY
HALAMBUR, CHENNAI-103

Treatment

JAYAPRAKASHWARA DENTAL COLLEGE & HOSPITAL
DEPARTMENT OF ORAL MEDICINE D'AGNOSIS & MAXILLOFACIAL RADIOLOGY
HALANBUR, CHENNAI-103

(1) Hospitalization and O_2 therapy

Admitted in ICU & ABG, chest xray

ECG done,

↑ conc. O_2 given $PaO_2 > 60$ mmHg

(2) Repeated dosage of short acting adrenergic drugs

Salbutamol, 2.5 - 5 mg or Terbutaline 5 - 10 mg

through nebulizer - 20 - 30 min

(3) Systemic steroids

prednisolone (30-60 mg daily) orally.

or Methylprednisolone given IV

Mechanical ventilation

IV fluid administration

Antibiotics

Operation, dedentures or tracheotomy

2) Jaundice

A yellowish discoloration of the skin and mucous membrane due to deposition of bilirubin is known as jaundice

Types :-

Types of ~~bot~~ Jaundice as seen

SRI VENKATESWARA DENTAL COLLEGE & HOSPITAL
DEPARTMENT OF ORAL MEDICINE, DIAGNOSIS & MAXILLOFACIAL RADIOLOGY
HALAMBUR, CHENNAI-103

(1) Prehepatic (Hemolytic).

(2) Hepatic (Hepatocellular)

(3) posthepatic (obstructive)

~~prep~~ prehepatic : due to hemolytic disorders, such as hereditary spherocytosis, sickle cell anemia, G6PD deficiency, paroxysmal nocturnal hemoglobinuria

Impaired hepatic metabolism.

Gilbert syndrome

Crigler - Najjar syndrome

conjugated hyperbilirubinemia

a. Dubin - Johnson & Rotor syndrome

b. Hepatocellular disease.

c. cholestatic jaundice.

3) Complications of Diabetes

DEPARTMENT OF ORAL MEDICINE, DIAGNOSIS & MAXILLOFACIAL RADIOLOGY

Acute complications

- Diabetic ketoacidosis (DKA)
- Hyperglycemic hyperosmolar state (HHS)

chronic complications

- Microvascular
  - Retinopathy
  - Neuropathy
  - Nephropathy
- Macrovascular
  - Coronary artery disease
  - Cerebrovascular disease
  - peripheral vascular disease
- Nonvascular
  - Gastrointestinal (gastroparesis, diarrhea)
  - Genitourinary
  - Dermatologic
- Infections
  - cataract & glaucoma.

SRI VENKATESWARA DENTAL COLLEGE & HOSPITAL
DEPARTMENT OF ORAL MEDICINE, DIAGNOSIS & MAXILLOFACIAL RADIOLOGY
HALAMBUR, CHENNAI-103

Miscellaneous

- Diabetic food
- erectile dysfunction

4) Myoxedema

- Also called as adult hypothyroidism
- The clinical features are altered sensorium, hypothermia, hypoglycemia, hypoventilation, hypoxia, hypercapnia, hyponatremia and hypotension. Coma is induced by infection cold exposure & systemic attrition

Treatment

→ IV administration of levothyroxine, 400µg.
50–100µg daily
→ Parenteral T_4 no, T_3 IV in dosage 10-25µg
8 hourly T_4.
→ external warming use of broad spectrum antibiotics
→ 50 mg – 100 mg hydrocortisone.

5) Shock

VENKATESWARA DENTAL COLLEGE & HOSPITAL
DEPARTMENT OF ORAL MEDICINE, DIAGNOSIS & MAXILLOFACIAL RADIOLOGY
HALAMBUR, CHENNAI-105

Clinical syndrome when the O_2 delivery fails to meet the metabolic requirements of the tissues → due to reduced tissues perfusion → ↓ delivery of O_2 and metabolic substances to the tissues

Classification

- Hypovolemic
- Cardiogenic
- Obstructive
- Neurogenic
- Septic
- Anaphylactic
- Traumatic
- Hypoadrenal

It may be caused by

a. Hemorrhage

b. Loss of fluid from GI tract

c. Urinary loss or insensible loss

d. Sequestration of fluid

ock as usually accompanied by
ies, no BP & circulatory failure

SRI VENKATESWARA DENTAL COLLEGE & HOSPITAL
DEPARTMENT OF ORAL MEDICINE, DIAGNOSIS & MAXILLOFACIAL RADIOLOGY
HALAMBUR, CHENNAI-103

6) Herpes Zoster

Herpes Zoster is due to reactivation of latent varicella - zoster virus from the dorsal root ganglion. Its incidence is highest in the 6th decade.

Clinical features

- The rashes are initially erythematous, maculopapular which evolve into vesicles & pustules
- Thoracic & lumbar roots are more commonly involved.
- Rashes usually subsides in 1-2 weeks.
- Immunocompetent patients are compromised
- Lesions along V_3 nerve
- Ramsay hunt syndrome

Complications

- post herpetic neuralgia
- meningitis, encephalitis

Treatment

Antiviral therapy — Acyclovir, valacyclovir, famcyclovir

Acyclovir — 800mg

Valacyclovir — 1000mg

Famciclovir — 500mg

7) Scurvy.

Deficiency of vitamin C occurs in poor elderly and chronic alcoholics. Vitamin C deficiency causes scurvy in which there is impaired formation of matrix connective tissues. The patients may have petechiae, ecchymosis, swollen and bleeding gums, hemarthrosis, anemia & poor wound healing. In children have growth.

Pdl signs not seen in adulterous leukocytes

4

8) HIV transmission

Most common mode of transmission of HIV in India as well as worldwide is heterosexual contact 85–90%. Through unsafe sex with CSW.

Other modes of transmission are through contaminated blood or, blood products, contaminated syringes of IV drug abusers, and from infected mother to fetus

- Transmission of HIV from mother to child occurs during labour, breastfeeding
- Blood, saliva, sweat, urine have not shown to transmit infection

SRI VENKATESWARA DENTAL COLLEGE & HOSPITAL
DEPARTMENT OF ORAL MEDICINE, DIAGNOSIS & MAXILLOFACIAL RADIOLOGY
HALAMBUR, CHENNAI-103

General Surgery

Answer Papers

General Surgery — Ahammed Basheer

SRI VENKATESWARA DENTAL COLLEGE & HOSPITAL
DEPARTMENT OF ORAL & MAXILLOFACIAL SURGERY
THALAMBUR, CHENNAI - 103

level of cervical lymph node:

level I:

In Submental lymph node
Submandibular lymph node

level II

* lymph node in upper deep cervical region Below and in front of the line of the spinal accessary nerve the upper part.
* Above and posterior to Spinal accessory nerve

Level III

lymph node is middle cervical region

Level IV: lymph node lower cervical region

Level V: lymph node in posterior triangle including Supraclavicular region.

→ Above the line spinal Accessory nerve
→ Below the level of spinal accessory nerve

level VI: lymph node in the midline neck

level VII: lymph node in mediastinum

Drainage area of lymph node:

level Ia lymph node:

floor of mouth anterior oral tongue, anterior Mandibular Alveolar ridge, lower lip.

level Ib lymph node:

anterior nasal cavity, soft tissue of midface Sub mandibular gland.

Certified
PRINCIPAL
SRI VENKATESWARA DENTAL COLLEGE & HOSPITAL
OFF. OMR NEAR - NAVALUR
THALAMBUR, CHENNAI-600 130

level II a & II b lymph node:-

oral cavity, nasal cavity, nasopharynx, larynx, parotid gland.

level III lymph node

oral cavity, oropharynx, nasopharynx, larynx.

level IV lymph node

Scalp, parotid gland, nasopharynx, thyroid gland

level V lymph node

Scalp, parotid gland, nasopharynx, thyroid gland

level VI lymph node:-

thyroid gland, subglottis larynx, of pyriform Sinus, cervical esophagus.

---

2) Shock:-

Shock defined as acute clinical syndrome characterised by hypoperfusion and severe dysfunction of vital organ.

Pathophysiology:-

Decreased effective circulatory blood.

↓

Decrease Cardiac output

↓

Decreased Blood flow

↓

Decreased supply of oxygen

↓

Anoxia

↓

neurogenic shock

- It is occur due to spinal cord injury which leads to dilatation of vessels.

→ There will be bradycardia hypotension Arrhythmias and decreased cardiac output

⇒ Clinical features:-

* Brady cardia
* Tachypnea
* Fainting

Classification:-

1) Hypovolaemic shock
2) Cardiogenic shock
3) Distributive shock
4) Obstructive shock

Hypovolaemic shock:-

- loss of blood - hemorrhagic shock
- loss of plasma - as burns shock
- loss of fluid - dehydration

SRI VENKATE... COL...
DEPARTMENT OF ORAL & M... SURGERY
THALAMBUR, CHENNAI - 103

⇒ Neurogenic:-

life threatening condition caused irregular blood circulation of the body

Trauma injury spine distribution damage of Central nervous System

Cause:-

High spinal cord injury

Vagolytic shock

Features:-

Hypotension without tachycardia, produce Shock and Cardiac arrest.

⇒ Treatment:-

- Control blood pressure using vasoconstriction
- Oxygen Administration
- Hemodynamics should be maintained
- Airway are closed
- Fluid therapy should given
- Dopamine and Phenylphrine used
- Intravenous methyl prednisole therapy done.

SRM KATTESWARA DENTAL COLLEGE & HOSPITAL
DEPARTMENT OF ORAL SURGERY
THALAMBUR, CHENNAI - 603

Short Note :-

1. Trimus :-

It refer to sustain, tonic spasm of the maxillary Muscle, particularly the Masseter & temporalis

To restriction of mouth opening occur due to infection, trauma, surgery (or) radiation

Normal opening of Mouth - may from patient to patient
range 40 - 60mm

Classification of trimus :

Based on range of Mouth opening

Mild trimus	30 - 40 mm
Moderate	15 - 30 mm
Severe	< 15 mm

Based on Duration :

Acute trimus

Subacute trimus

Chronic trimus

Clinical features :-

Pain duration forced mouth opening

Duration of Mandible.

Sensation Muscle tightness, clamping (or) Stiffness.

Speech impairment reffered to lust "potato voice"

Impaired Oral intake

Loss of weight

Poor oral hygine

Aspiration

Difficult in breathing

Mangement :-

Conservative Medical Mangement

Heat → placement of moist hot towel on Affected area for 10 - 20 min / sher. Analgic therapy - Asprin is the most common. when discomfort is extensive narcotic Analgeic may be indicated

Soft diet

Muscle relaxant - In extensive Masticatory Muscle Spasm, benzodiazpines 2.5 - 5.mg 3 times a day may be indicated.

Antibiotic such that antidepresion diazepam (2.5 - 5mg) three time daily

Antibiotic prophylaxis for Infective endocarditis.

SAVEETHA DENTAL COLLEGE & HOSPITAL
DEPARTMENT OF ORAL & MAXILLOFACIAL SURGERY
THALAMBUR, CHENNAI - 103

Oral medication:- Amoxicillin

Adult - 2g Children 50 mg/kg

Unable to take to orally:-

- Ampicillin
- cyfazolin - 1g (IM/IV) 50 mg/kg
  Cytriaxzone - 500mg 50 mg/kg

⇒ Allergy to penicillin & Ampicillin but not able to take orally:-

Cephalexin		
Clindamycin	2g	30 mg/kg
Azithromycin /	600mg	20 mg/kg
Erythromycin	500 mg	15 mg/kg

SURGERY

Allergy to penicilin or
Ampicillin and unable to
take oral Medication

Cefazolin or
ceftriaxone 1g (IV, IM) 500mg

Clindamycin 600mg (IM (or) IV) 200mg

SAVEETHA DENTAL COLLEGE & HOSPITAL
DEPARTMENT OF ORAL & MAXILLOFACIAL SURGERY
THALAMBUR, CHENNAI - 103

Biopsy:-

Define:

Biopsy is the removal of tissue from living organism for the purpose of microscopic examination & diagnosis

TYPES:

Excision biopsy:-

Single small swelling such lymph node It can be done general Anasthesia incision made over swelling around histological evaluation called excision

Fine needle Aspiration cytology:-

tumor swelling removing the needle out skin over the lump different procedure negative pressure cell Are needle syringe

Advantage - safe, simple cost effective pain free, cost effective.

lymph nodal swelling, thyroid swelling, tumors etc.

Avoid large amount blood clot and cells.

True - cut biopsy:-

Immunohisto chemistry play major role Mangement FNAC cannot maligancies lymphoma Carcinoma breast tissue small dressing Applied thyroid swelling vascular recurrent laryngeal Sacroma, lymphnode metastasis neck etc.

Punch biopsy:-

long instrument forceps, punch of the tissue removed by closing the blade instrument. Cauliflower like lesion exophytic lesion.

Wedge Biopsy:-

TYpically done suspect maligant ulcer epithetoma chronic ulcer / scar edge rapidly cancerous time present wedge of normal skin also removed depth which important maligant melanoma.

Incision Biopsy:-

3) Suspect lymphoma matted node inision over swelling after giving local Anasthetic agent lymph node dissected all around lymph node removed metastais neck because result spillage cell subcutaneous plane Sarcoma maligances lesion biopsy

Full thickness excision biopsy:-

Strongly recommended and done Maligant melanoma depth of Invasion decides staging treatment

4) **Tetanus:-**

Serious disorder with very high mortality with treatment disease caused by clostridium tetani anaerobic spore forming bacillus terminal spores drumstick like appearance.

⇒ development of tetanus

- No Immunisation
- foreign body
- Injury
- Improper Sterilisation
- Anaerobic condition.

SAVEETHA DENTAL COLLEGE & HOSPITAL
DEPARTMENT OF ORAL & MAXILLOFACIAL SURGERY
THALAMBUR, CHENNAI - 103

TYPES:-

* Tetanus neonatorum:-
due children born to non-Immunied mother around 6-8 days eight day disease

* Local tetanus:
Contraction of muscle neighbourhood of the wound

* Cephalic tetanus:
Usually after wound head and face Cranial nerves facial nerve oculomotor nerve can paralysed poor prognosis.

* Bulbar tetanus:-
Condition muscle deglutition respiration are involved fatal.

* Latent tetanus:-
develop after few months to year following wound which might forgotten

* Puerperal tetanus:-
Occurs complication absorption pruerperal sepsis

Clinical Features:-
* Anatonomic dysfunction
Increased basal and bladder, bowel dysfunction, labile hypertension, pyrexia, pallor, swelling, cyanosis

* Episodes of brady caudia low central venous pressure Cardiac Arrest parasympathetic dysfunction develop complication Pneumonia, urinary trait, Infection.

DEPARTMENT OF ORAL & MAXILLOFACIAL SURGERY

Mangement:-

General Mangement

* Admission and isolation
quid room avoid minor stimuli spasm.

* wound Care:
drainage of pus, excision removal of foregin body
Proper dressing.

* Injection tetanus toxoid
0.5 ml to given IM

A- Mild cases:-

* there is only tonic rigidity spasm. heavy sedation Combination drug avoid convulsion.

* Benzodiazepin and morphine centrally effect tetano spasmin.

* chlorpromazine receptor blocker, decrease sympathic activty Phenotolamine

B- Seriously ill cases:-

* they have dysphagia reflex spasm
* nasogastric tube
* Tracheostomy breatting difficulty arises
* patient a dose 250 units human Anti tetanus globulin adequate protection

ystic lymphoma:-

SAVEETHA DENTAL COLLEGE & HOSPITAL
DEPARTMENT OF ORAL & MAXILLOFACIAL SURGERY
THALAMBUR, CHENNAI - 103

Defination:-

It is a cystic swelling lined by endothelial cell

* failure of one of lymphatics join major lymph sac body result in lymphangioma

* Common site - Posterior triangle of neck of axilla, mediastinum, groin etc.

* lymphatics by time swelling lymph replaced thin watery fluid secreted by endothelium

* Subcutaneous plane called cystic lymphoma.

Cause - Neonates, Infants, children

Clinical features:-

* Cystic lymphoma present early childhood present rarely before birth small vesicles.

* Strains, swelling increase in size become prominant Intrathoric transmitted through root of the neck

* topical locations - lateral aspect of neck.

* Soft, cystic fluctuat partially compressing swelling lymphangioma multilocular swelling aggregation multiple cyst. complete reducibity not a features.

* Swelling brillitaly transilluminant

Differential Diagnosis:-

- Haemangioma
- Lipoma
- Cold Abscess.

⇒ Treatment:-

- Surgical excision treatment All the loculi or cyst should be extension of lymphangioma through planes.
- Sclerotherapy lymphgioma sclerosants.

6) Ludwing's Angina:-

Submental and Submandibular region combined by Inflammatory oedema of mouth virulent streptococci organism Infection Submandibular region Anaerobes also major role.

⇒ Clinical features:-

- elderly patient Present diffuse swelling submandibular and submental region.
- oedema the floor of mouth - tongue pushed upward result difficult swallowing.
- High grade fever with toxicity
- putrid thalitosis is characteristic this condition

treatment:-

- Rest & hospitalisation
- Appropirate Antibiotic
- Intravenous fluid correct dehydration Ryle's tube feeding
- conservative treatment surgical interation recommended.

Surgery:

General Anaesthesia 5-6cm curved incision below the mandible the Submandibular region Swelling mobilised Mylohyoid muscle Pus drained oedematous ~~fluid~~ loose suture irrigating Cavity Antiseptic agent drainage tube is place.

SARA DENTAL COLLEGE & HOSPITAL
DEPARTMENT OF ORAL & MAXILLOFACIAL SURGERY
VADAMBUR, CHENNAI - 103

Complication:-

* Mediastinitis & septicaemia
* Oedema of glottis due spread cellulitis tunnel occupied Stylohyoid submucosa of the glottis

---

7) Warthin's tumor:-

* Adenolymphoma is not a lymphoma
* benign parotid tumor and next pleomorphic Adenoma
* During development some Parotid time included lymphnode which are present within Parotid sheath

Histology:-

It is composed double layered eosinophilic epithelium inner cell are columnar.

Presence of lymphatic time stroma lymph follicle Adenolymphoma.

Clinical feature:-

* Middle Aged elderly male are Commonly affected they are Smokers.
* Can be bilateral some cases 10%.
* It Smooth surface, round border with soft cystic consistency
* lower pole of Parotid elevating ear lobe
* May be Multicentric
* this tumor Affect only Parotid gland.

Treatment:-

* It has got a well defined capsule.
* Surgical excision can be done.

---

8) Tracheostomy:-

Making an opening in Anterior wall of trachea Converting into stoma on skin surface.

Function:-

* Respiration through pathway case obstruction stoma
* Alveolar ventilation improved due reduction dead space 30-50%. resistance Airflow.
* Protection of Airway Pharyngeal secretion blood due to injuries Pharynx larynx,
* Tracheobranchial toilet
* Intermittent positive pressure respiration > 72 hours
* Administer Anasthesia

Indication:-

MAHESWARA DENTAL COLLEGE & HOSPITAL
DEPARTMENT OF ORAL & MAXILLOFACIAL SURGERY
THALAMBUR, CHENNAI - 103

* Respiratory Obstruction:-

Trauma - larynx, trachea, mandible fracture,

Tumor

foreign body

Laryngeal edema due to Allergy

Congenital Anomalies.

* Retained Secretion:-

- Painful cough trauma Chest
- Aspiration Pharyngeal secretions

* Respiratory Insufficiency:-

lung conditions emphysema, Chronic, bronchitis,

TYPES:-

1) Method Initial Insertion:-

* Surgical
* percutaneous.

2) Intended duration

temporary tracheostomy

permanent tracheostomy.

Technique:-

* Intubated prior to surgery (children)
* position - supine.

Procedure:-

* Incision can be Vertical (or) transverse

* veins surface retracted, Muscle separated midline and thyroid upward

* Trachea exposed

* 4% Xylocaine infiltrated

* Transverse Incision made between 2nd and tracheal ring 2 end joined transverse incision tracheostomy tube placed and cuff in flated

Complication:-

1) Early:-
- Bleeding
- Injury to osteophagus
- recurrent laryngeal nerve

2) Intermediate
- Secondary Infection wound
- Blockage of tube

3) Late
- Tracheal Stenosis
- Scar and keloid.

9) lymphoma:-

Progressive neoplastic condition lympho Proliferative Disorder arises from stem cell.

Etiology:-

Genetic, Sjogren syndrome, HIV Infection, Ionising radiation.

SRI VENKATESWARA DENTAL COLLEGE & HOSPITAL
DEPARTMENT OF ORAL & MAXILLOFACIAL SURGERY
THALAMBUR, CHENNAI - 103

Pathology:-

- Disease usually one of lymph node painless swelling
- left supraclavicular region enlarged without matting spread lymph node smooth
- the axial lymphatic system is almost affected Hodgkin's Disease

Classification:-

1) lymphocyte predominance nodular:-
lymphoma low grade B cell lymphomas

II) Hodgkin's lymphoma:-
- Nodular Sclerosis
- Lymphocyte rich
- lymphocyte depletion
- Mixed cellularity

Clinical features:-

* Age - Biodal distribution Children Middle Age.
* Sex - Increased incidence found males
* generalised lymphadenopathy more than lymphadenopathy
  - lymph node > 2cm in size
  - Node is hard consistency
  - palpable left supra Clavicular node

* lymph node firm rubber consistency
* Abdominal Pain due to hepatic splenomegaly smooth surface smooth round border.
* neck axilla para aorstic & Inguinal lymph node enlarged.
* dysphagia, dyspnea,

Para aortic nodes
Umbilical region mass so on the left side
* Nodular
* Firm to hard mass
* Fixed mass

* Intermittent fever:-
Skin rashes rare hodgkin lymphoma

* Multiple bony Pains :-
Secondary deposit, lumber veretebrae deposit
ivory vertebrae.

* Superior vena cava obstruction:-
Mediastinal nodes hand above head touches the ears veins Indicates obstruction and test positive

Investigation:-
* Complete Blood picture
* Elevated creatinine and blood urea nitrogen.
* Chest x ray
* Abdominal USG
* Lymph node biopsy
* CECT Scan.

Treatment:-
Stage I - Radio therapy
Dose of radio-therapy 3500 - 4500 centrigray units

Stage II, III A, III B, IV - Chemotherapy regime

MOPP regime:-
M - Mechlorethamine 6 mg/m² body
O - Oncovin 1.4 mg/m²

P - Procarbazine 100 mg orally 1 to 10 day

P - Prednisolone 15 mg.

SRI VENKATESWARA DENTAL COLLEGE & HOSPITAL
DEPARTMENT OF ORAL & MAXILLOFACIAL SURGERY
THALAMBUR, CHENNAI - 103

10) Carbuncle:-

Infective gangrene of subcutaneous tissue caused Staphylococcus aureus. Commonly occur diabetic Patient.

Site - Nape of the neck commonest back shoulder region skin site poor vascularity.

Pathology:-

boil
↓
hair follicle
↓
diabetics
↓
necrosis is subcutaneous fat
↓
Cribriform appearance

Clinical features:-

* diabetic * Severe pain and swelling in nape of the neck.
* fever with chills + rigors are severe
* surface red, angry looking red hot coal
* Surrounding area indurated
* peripheral satellite vesicle appear rupture discharging Pus Cribriform appearance
* development of large ulcer central slough

Complication:-

1) worsening diabetic status result diabetic ketoacidosis
2) Extensive necrosis skin overlying carbuncle acute infective gangrene
3) septicaemia, toxaemia

Treatment:-

* Diabetes control Injectable insulin
* parenteral Antibiotic are Staphylococcus aureus cloxallin flucloxacillin, erythromycin
* drug vancomycin which given intravenously
* Improve general health
* healing not incised evidence healing It is not external Saline dressing applied reduce complete resolution may take place within 10 - 15 days.

* Surgery which pus cruciate incision multiple Abscess extensive subcutaneous necrosis edge skin flap are excised pus drained Local broken down slough antiseptic agent wound heals granulation tissue depth amount excision Carbuncle.

Infant Nithin Dhal

General Surgery

II Write short notes.

1. Trismus

Trismus or lock jaw, occurs due to Severe Contraction of the masseter muscle, resulting in inability to open the mouth. It is the most common Symptom of tetanus

Inflammation involving muscle of mastication or direct trauma to TMJ

2-5 after mandibular block.

Risk of misdiagnosing.

oral submucous fibrosis - precancerous condition

Trismus is due to involvement of pterygoid muscle and masseter. This occur when carcinoma cheek extends into the retromolar trigone.

(2) Antibiotic prophylaxis for Infective Endocarditis

Situation	Agent	Adults	Children
Able to take oral medication	Amoxicillin	2g	50mg/kg
unable to take oral medication	Ampicillin	2g	50 mg/kg
	Cefazolin	1g	50mg/kg
Allergic to penicillins or ampicillin and able to take oral medication	cephalexin	2g	50mg
	Clindamycin	600mg	15mg
Allergic to penicillins or ampicillin and unable to take oral medication	Clindamycin	600mg	20mg
	Cefazolin	1g	50mg.

Biopsy

VENKATESWARA DENTAL COLLEGE & HOSPITAL
DEPARTMENT OF ORAL & MAXILLOFACIAL SURGERY
THALAMBUR, CHENNAI - 103

Biopsy is a surgical procedure to obtain tissue from a living organism for a microscopical examination, usually to perform a diagnosis

Types of biopsy:-

There are four major types.

i) Cytology
ii) aspiration biopsy
iii) Incisional biopsy
iv) excisional biopsy
v) punch biopsy

Indications for biopsy:-

* Any lesion that persists for more than 2 weeks with no apparent etiologic basis

* Any persistent tumor, suspected being neoplastic.

* Inflammatory changes of unknown cause that persist for long periods.

Contraindications:-

poor general condition

vascular origin

Blood dyscrasia.

Surgical procedure:

Anesthesia

Incision

Haemostasis.

4. Tetanus

Tetanus is a serious disorder with very high mortality even with treatment.

The disease is caused by clostridium tetani.

favourable conditions for development of tetanus.

No immunisation

Foreign body

Injury

Improper sterilisation

Anaerobic conditions.

SRI VENKATESWARA DENTAL COLLEGE & HOSPITAL
DEPARTMENT OF ORAL & MAX SURG
THALAMBUR, CHENNAI

Spacial types of tetanus:-

Tetanus neonatorum
Local tetanus
cephalic tetanus
Bulbar tetanus

clinical features:-

Autonomic dysfunction: Increased basal sympathetic tone manifesting as tachycardia and bladder.

Treatment of established tetanus

General management
Specific management.

5) Cystic hygroma

Failure of one of the lymphatics to join the major lymph sac of the body results in a lymphangioma

Common sites: posterior triangle of the neck, axilla, mediastinum, groin, etc..

In the neck, it is called cystic hygroma of the neck. As the sac has

no communication with lymphatics by the ti. Swelling appears, the lymph is absorbed and is replaced by thin watery fluid secreted by Endothelium.

When it is largely confined to subcutaneous plane, it is called cystic hygroma.

Clinical features :-

usually, cystic hygroma presents during infancy or early childhood. occasionally present since birth and rarely before birth. They can also present has small vesicle.

When the child cries or strains, the swelling increases in size and become prominent due to increased intrathoracic pressure which is transmitted through root of the neck.

Typical locations - lateral aspect of neck, groin, buttocks.

soft, cystic, fluctuant, partially compressible swelling. These cysts may intercommunicate and sometimes may insinuate between muscle planes.

The swelling is brilliantly transilluminant because it contains clear fluid.

SRI VENKATESWARA DENTAL COLLEGE & HOSPITAL
DEPARTMENT OF ORAL & MAXILLOFACIAL SURGERY
THALAMBUR, CHENNAI - 103

Treatment:

Surgical excision.

Differential Diagnosis:

Haemangioma

Lipoma

Cold Abscess.

complications:

In neonates and infants, lymphangioma can cause difficulty in breathing due to the large size.

6. Ludwig's angina

It refers to cellulitis of Submental and Submandibular regions combined with inflammatory oedema of the mouth.

clinical features:

Elderly patient who presents with diffuse swelling in the submandibular and submental region.

Oedema of the floor of the mouth as a result of which tongue is pushed upwards resulting in difficulty in swallowing.

High grade fever with toxicity.

Treatment:

Rest and hospitalisation

Appropriate antibiotics.

Surgery:

under general anaesthesia, 5-6cm curved incision is made below the mandible in the submandibular region over the most prominent part of the swelling.

Complications:-

Mediastinitis and Septicaemia

Oedema of the glottis.

7. Warthin's tumor.

Adenolymphoma is not a lymphoma.

It is a misnomer.

It is a benign parotid tumour.

and next common to pleomorphic adenoma.

SRI VENKATESWARA DENTAL COLLEGE & HOSPITAL
DEPARTMENT OF ORAL
...IAL
...ERY
THALAMBUR, CHENNAI - 103

Histology:

It is composed of double layered eosinophilic epithelium, inner cells are column

presence of lymphatic tissue in the stroma and lymph follicles is characteristic of adenolymphoma.

clinical features:

Middle aged or elderly males are commonly affected.

can be bilateral, in some cases.

may be multicentric.

Treatment:

It has got a well-defined capsule, Hence, enucleation can be done.

8. Tracheostomy

Making an opening in anterior wall of trachea and converting it into a stoma on skin surface.

function:

Respiration through alternative pathway in case of obstruction above the stoma.

Tracheobronchial toilet

protection of airway by way of cuffed tracheostomy tube

Administer anesthesia.

Indications:-

Respiratory obstruction

Retained secretions.

Respiratory insufficiency.

Types:

Emergency, elective or permanent.

complications of Tracheostomy.

(i) Early

-> Bleeding

-> Injury to oesophagus.

ii) Intermediate

-> Secondary infection of wound

-> Blockage of the tube.

iii) Late

-> Tracheal stenosis

-> Scar and keloid.

Lymphoma :

Lymphomas are malignant neoplasms originating in the bone marrow lymphatic structures resulting in the proliferation of lymphocytes.

SRI VENKATESWARA DENTAL COLLEGE & HOSPITAL
DEPARTMENT OF ORAL & MAXILLOFACIAL SURGERY
THIRUMUDIVAKKAM, CHENNAI - 600 044

Classification :-

i) Hodgkin's lymphoma

ii) Non-Hodgkin's lymphoma

Hodgkin's lymphoma :-

It is a type of lymphoma in which cancer originates from a specific type of white blood cells.

Non-Hodgkin's lymphoma :-

It is a differentiated group of blood cancer that include any kind of lymphomas except Hodgkin's lymphoma

Etiology :-

Infection with Epstein Barr virus, HIV

Genetic predisposition

occupational toxins such as pesticides or benzene.

clinical manifestations

fever
fever night sweats
weight loss
fatigue
weakness
chills

Diagnostic studies:

History collection and physical examination
Blood and urine study
Bone marrow examination

management:

chemotherapy
Radiation therapy
Biological therapy.

10. carbuncle

This is an infective gangrene of the subcutaneous tissue caused by staphylococcus aureus

It commonly occurs in diabetic patient, poor immunity, radiotherapy patients can also develop carbuncle

Sites: Nape of the neck is the commonest site followed by back and shoulder region.

SRI VENKATESWARA DENTAL COLLEGE & HOSPITAL
DEPARTMENT OF ORAL MAXILLOFACIAL SURGERY
THALAMBUR, CHENNAI - 103

pathology:

The initial lesion is similar to a boil in the form of hair follicle infection with perifolliculitis.

These abscesses are intercommunicating and they open to the exterior by multiple openings which are called Sieve-like openings.

3 Clinical features:

Typically, the patient is a diabetic.

Severe pain and the swelling in the nape of the neck.

complications:

Septicaemia, toxaemia.

Extensive necrosis of skin overlying carbuncle.

Treatment:

Diabetes control preferably with insulin

Improve general health of the patient

Elaborate on:

1. Levels of cervical lymph node. Describe lymphatic drainage of Head and neck.

Level I:

Ia => Submental lymph nodes

Ib => Submandibular lymph nodes.

Level II: Lymph nodes in upper deep cervical region.

IIa => Below and in front of the line of the spinal accessory nerve in the upper part.

IIb => Above and posterior to line of spinal accessory nerve.

Level III: lymph nodes in middle cervical region

Level IV: Lymph nodes in lower cervical region.

Level V: lymph nodes in the posterior triangle including supra clavicular region.

Va => Above the line of spinal accessory nerve.

Vb => Below the level of spinal accessory nerve.

Level VI : lymph node is the midline neck.

Level VII : lymph nodes in mediastinum.

SAVEETHA DENTAL COLLEGE & ... DEPARTMENT OF ORAL ... SURGERY ... CHENNAI - 103

Drainage area of lymph node

Level Ia lymph node :-

floor of mouth, anterior oral tongue, anterior mandibular alveolar ridge, lower lip.

Level Ib lymph node:

oral cavity, anterior nasal cavity, soft tissue of midface, submandibular gland.

Level IIa and IIb lymph nodes:

oral cavity, nasal cavity, oropharynx, nasopharynx, hypopharynx, larynx, parotid gland.

Level III lymph node :-

oral cavity, oropharynx, nasopharynx, hypopharynx, larynx.

Level IV lymph node :-

Scalp, parotid gland, nasopharynx, thyroid gland.

Level VI lymph node:

Thyroid gland, glottis and subglottis larynx, apex of pyriform sinus, Cervical esophagus

2 Shock:

Shock is defined as an acute clinical syndrome characterised by hypoperfusion and severe dysfunction of vital organs.

pathophysiology of neurogenic shock:-

Decreased effective circulatory blood volume.

↓

Decreased cardiac output

↓

Decreased blood flow

↓

Decreased supply of oxygen

↓

Anoxia

↓

Neurogenic shock.

It occurs due to spinal cord injury which leads to dilatation of splanchnic vessels.

There will be: bradycardia, hypotension, arrhythmia and decreased cardiac output.

SRI VENKATESWARA DENTAL COLLEGE & HOSPITAL
DEPARTMENT OF ORAL & MAXILLOFACIAL SURGERY
THALAMBUR, CHENNAI - 130

Clinical features :-

* History of emotional stress
* Bradycardia
* Tachypnea
* Fainting.

Treatment :

* Control blood pressure using vasoconstrictions
* oxygen administration.
* Hemodynamics should be maintained
* Airway as cleared
* fluid therapy should be given.
* Intravenous methylprednisolone therapy is done.

Mohammed Noohu Riyas. S.M

General Surgery
Remedial test

DEPARTMENT OF ORAL & MAXILLOFACIAL SURGERY
SDS • THALAMBUR, CHENNAI - 103 •

37/40

Short notes:

1. Trismus:

- Trismus is the inability to open the mouth.
- Normal opening of mouth about 40-60mm
- It varies from patient to patient
- lower limit at 35mm.
- Following extraction of teeth,
- Inflammation involving muscles of mastication or direct trauma to TMJ.
- 2-5 after mandibular block.
- Tumors or oral malignancies of trismus.
- Risk of misdiagnosing.
- Thorough clinical or radiographic examination to rule out neoplastic disease primary or metastatic, in epipharyngeal region, parotid gland, jaws or TMJ.
- Oral submucous fibrosis - precancerous condition.

Drug therapy :-

- Some drugs cause trismus as second effect,
  - Succinyl choline
  - Phenothiazines
  - Tricyclic anti depressants.

- Trismus can seen as extrapyramidal side effect of :- metaclopramide,
  - Phenothiaxines

Causes :-

Most common.

- Impacted third molar
- Removal of wisdom teeth
- Removal of tonsil
- Radiation
- Trauma

Treatment.

- Massage (gently rub) your jaw muscles
- Exercise jaw muscles
- Maintain oral hygiene
- Muscle relaxers & NSAID taken to relieve pain.

2, Antibiotic prophylaxis for infective endocarditis.

SRI VENKATESWARA DENTAL COLLEGE & HOSPITAL
DEPARTMENT OF ORAL & MA SURGERY
THALAMBUR, CHENNAI - 103

Situation	Agent	adult	children
Able to take oral medication	amoxicillin	2g	50mg/kg
Unable to take oral medication	Ampicillin	2g	50mg/kg
	cefazolin	1g	50mg/kg
3 Allergic to penicillin or ampicillin & able to take oral medication	cephalexin	2g	50mg
	clindamycin	600mg	15mg
Allergic to penicillin or ampicillin & unable to take oral medication	clindamycin	600mg	20mg
	cefazolin	1g	50mg

3) Biopsy:

It is surgical procedure to obtain tissue from living organism for its microscopic examination, usually to perform a diagnosis.

Types:

Four types are,

Cytology
Aspiration biopsy
Incisional biopsy
Excisional biopsy
Punch biopsy

Indications:

Any lesion persist for more than 2 weeks with no apparent etiologic basis

Any inflammatory lesion doesn't respond to local treatment after 10 to 14 days

Persistent hyperkeratotic changes in surface tissue

SRI VENKATESWARA DENTAL COLLEGE & HOSPITAL
DEPARTMENT OF ORAL & MAXILLOFACIAL SURGERY
THALAMBUR, CHENNAI - 103

Contra indications:

acute pyogenic infection present.

vascular origin.

2) surgical procedure.

Surgical closure

Handling of tissue

---

4. Tetanus:

Tetanus is a neurologic disorder characterised by increased muscle tone and spasms, that is caused by tetanospasmin, a powerful protein toxin elaborated by clostridium tetani

It is acute, fatal disease

Characterised by generalised rigidity & convulsive spasms of skeletal muscle

Favourable condition for development of tetanus:

No immunisation

Foreign body

Injury

Improper st.

Clinical features:

Autonomic sterilisation. dysfunction

Incubation period. about 4 to 8 days

Increased muscle tone & generalised spasm.

Onset after injury - 4 days

Dysphagia

Four clinical forms:

Localised

Cephalic

Generalized

Neonatal.

Treatment:

Diazepam - 0.1 - 0.2 mg/kg

Antibiotics

Supportive care

Isolation

Oxygen inhalation

Cystic hygroma:

SRI VENKATESWARA DENTAL COLLEGE & HOSPITAL
DEPARTMENT OF ORAL & MAXILLOFACIAL SURGERY
THALAMBUR, CHENNAI - 103

Failure of one of lymphatics to join major lymphsac of body results in lymphangioma.

Hence it occurs in places where lymphatics are abundant.

Common sites: Posterior triangle of neck, axilla, mediastinum, groin etc.

In neck called cystic hygroma of neck.

As saches no communication with lymphatics by time swelling appears, lymph is absorbed & replaced by thin watery fluid secreted by endothelium.

Hence it is called hydrocele of neck.

When it is largely confined to subcutaneous plane, it called as cystic Hygroma.

Clinical features:

Presents during infancy, or early childhood.

They present as small vesicles.

It increase in size, prominent transmitted through root of neck

Typical locations - Lateral aspect of neck, groin, buttocks.

Soft, cystic, fluctuant, compressible swelling.

Multilocular swelling consisting of aggregation multiple cysts.

Swelling contains clear fluid & transilluminant

Treatment:

Surgical excision is treatment of choice.

Injection type of treatment is not favoured at present.

Differential diagnosis:

Haemangioma
Lipoma
Cold abscess

---

6. Ludwig's angina

It refers to cellulitis of submental & submandibular regions, combined with inflammatory oedema of mouth.

virulent streptococcal organisms responsible for infection surrounding submandibular regions.

Anaerobes plays major role.

Clinical features:

Oedema of floor of mouth, result of which tongue pushed upwards results in difficulty in swallowing.

High grade fever with toxicity

Putrid halitosis is characteristic of this condition

Treatment.

Rest & hospitalisation

Antibiotics

Intravenous fluids to correct dehydration &

Ryle's tube feeding.

Surgery:

Under general anesthesia, 5-6 cm curved incision made below mandible in submandibular region over part of swelling.

Submandibular gland is mobilised, myelohyoid muscle is divided &

Pus is drained.

complications.

Mediastinitis

Septicaemia

Oedema of glottis due to spread of cellulitis via tunnel occupied by stylohyoid to submucosa of glottis.

SRI VENKATESWARA DENTAL COLLEGE & HOSPITAL
DEPARTMENT OF ORAL & ... IAL
THALAMBUR ... 103

Warthin's tumor.

Also called as Adenolymphoma.

It is not a lymphoma. It is a misnomer.

It is a benign parotid tumour and common to pleomorphic adenoma.

It constitutes about 10%. of parotid tumour

Origin of adenolymphoma.

During development some parotid tissue gets included within lymph nodes which present within parotid sheath.

Clinical features.

Middle aged or elderly males affected - usually they are smokers.

Bilateral.

Smooth surface, round border with soft, cystic consistency.

May be multicentre

Tumors affects only parotid gland.

Histology.

SRI VENKATESWARA DENTAL COLLEGE & HOSPITAL
DEPARTMENT OF ORAL & MAXILLOFACIAL SURGERY
THALAMBUR CHENNAI - 103

It composed of double layered cuboidal epithelium, inner cells are columnar.

Presence of lymphatic tissue in stroma, lymph follicles is characteristic of adenolymphoma.

22

Treatment.

It has well defined capsule. Hence enucleation can be done.

---

8. Tracheostomy:

Making an opening in anterior wall of trachea and converting it into stroma on skin surface.

Functions:

Respiration through alternative pathway in case of obstruction above stoma.

Alveolar ventilation improved due to reduction in dead space by 30-50% & reducing resistance to airflow.

Warthin's tumor.

Also called as Adenolymphoma.

It is not a lymphoma.. It is a misnome

It is a benign parotid tumour and common to pleomorphic adenoma.

It constitutes about 10%. of parotid tumours

Origin of adenolymphoma.

During development some parotid tissue gets included within lymph nodes which present within parotid sheath.

Clinical features.

Middle aged or elderly males affected.

usually they are smokers.

Bilateral.

Smooth surface, round border with soft, cystic consistency.

May be multicentre

Tumors affects only parotid gland.

Protection of airway by way of cuffed tracheostomy tube.

Tracheobronchial toilet

Intermittent positive pressure respiration if required 72 hours then tracheostomy preferred over endotracheal intubation.

Administer anesthesia.

Indications.

Respiratory obstruction:

Infections - Ludwigs angina, acute epiglottis, peritonsillar.

Trauma to larynx, trachea, mandible fractures.

Tumor.

Laryngeal oedema.

Bilateral abductor vocal cord palsy.

Retained Secretions.

Comatose patient

Painful cough trauma to chest

Aspiration of pharyngeal secretion

Respiratory insufficiency

Types:

Emergency

Elective or permanent.

SRI VENKATESWARA DENTAL COLLEGE & HOSPITAL
DEPARTMENT OF ORAL & MAXILLOFACIAL SURGERY
THALAMBUR, CHENNAI - 103

Technique

If possible patient intubated prior to surgery.

position - supine with neck extended under local

Complications:

Bleeding

Injury to recurrent laryngeal nerve

Blockage of tube

Tracheal stenosis

Scar & keloid.

---

9) Lymphoma.

Lymphomas are malignant neoplasms originating in bone marrow & lymphatic structure resulting in proliferation of lymphocytes

Classification.

Hodgkin's lymphoma

Non Hodgkin's lymphoma

Etiology:

Infection with Epstein Barr virus, HIV

Genetic predisposition

Clinical manifestation:

fever

cervical axillary, inguinal lymph node enlargement

Fever night sweats

weight loss

Itching

Tachycardia

Anemia

Diagnosis:

Blood & urine test

Biopsy

Lumbar puncture

Blood Analysis

CT scan

Management:

Chemotherapy

Bleomycin, Prednisolone

Vinblastine

Dacarbazine

SRI VENKATESWARA DENTAL COLLEGE & HOSPITAL
DEPARTMENT OF ORAL & MAXIMUM ... IAL ... UNIVERSITY
THALAMBUR ... - 102

10. Carbuncle :

This is an infective gangrene of subcutaneous tissue caused by staphylococcus aureus.

Common in diabetic patients

Poor immunity, radiotherapy patients also affected.

Site: Nape of neck is commonest site followed by back & shoulder region.

Skin of these sites is coarse & poor vascularity.

Pathology:

Initial Lesion similar to boil in form of chair follicles infection with perifolliculitis

Necrosis of subcutaneous fat which gives rise to multiple abscesses.

These abscesses are inter communicating & they open exterior by multiple opening which called sieve like openings

This appearance is cribriform appearance which pathognomic of carbuncle.

clinical features.

Patient is diabetic

Pain at swelling in neck

Surface is red, angry looking like red hot coal.

Surrounding area is indurated

The end result is development of large crateriform ulcer with centre slough.

Complications:

Septicaemia

Diabetic ketoacidosis.

Treatment:

Cruciate incision

Antibiotics.

SRI VENKATESWARA DENTAL COLLEGE & HOSPITAL
DEPARTMENT OF ORAL SURGERY
THALAMBUR, CHENNAI - 103

Essay:

1. Levels of cervical lymph node.

Level I - Lymph nodes in submandibular triangle, submental nodes.

Level II - Upper Jugular nodes - From posterior belly of digastric superiorly to hyoid bone inferiorly

Level III - Middle jugular nodes - From hyoid superiorly to cricothyroid membrane inferiorly

Level IV - Lower jugular nodes - From cricothyroid membrane superiorly to clavicle inferiorly

Level V - Posterior cervical region. From anterior border of trapezius posteriorly to posterior border of sternocleidomastoid anteriorly, clavicle inferiorly

Level VI - Anterior compartment nodes - From hyoid bone superiorly to suprasternal notch inferiorly & laterally by medial border of carotid sheath

Level VII - Upper mediastinal nodes - Inferior to suprasternal notch.

Lymphatic drainage of Head & Neck

Location & drainage area:-

Submental:

Central part of lower lip, floor of mouth, tip of tongue

Submandibular

Cheek, tongue, upper lip, outer part of lower lip, gums, angle of mouth, side of nose, inner angle of eye

Parotid

Nasopharynx, back of nose, eyelids, front of scalp, enamel, auditory meatus, tympanic cavity.

Preauricular

Outer surface of pinna, side of scalp

Post. auricular

Temporal region of scalp, back of pinna

Occipital

Back of scalp.

shock.

DEPARTMENT OF ORAL & ... ACIAL ... CHENNAI - 103

Shock is a life threatening situation due to poor tissue perfusion with impaired cellular metabolism, manifested in turn by serious pathophysiological abnormalities.

It may defined as inadequate delivery of oxygen & nutrients to maintain normal tissue & cellular functions.

Characterized by

An acute reduction in effective circulating blood volume.

An inadequate perfusion of cells & tissues.

Classification :

Primary

Secondary

Anaphylactic

True shock

- circulatory shock.

⑨ ~~Shock~~.

According to etiology

Hypovolemic shock
Cardiogenic shock
Septic shock
Other types,
Traumatic
Neurogenic
Hypoadrenal.

Neurogenic shock.

Primarily due to blockade of sympathetic nervous system,

→ loss of arterial & venous tone in pooling of blood in dilated peripheral venous system.

caused by,

Paraplegia
Quadriplegia
Traumato spinal cord
Spinal anasthesia

Clinical features

warm skin, pink.

Rapid Heart rate

Blood pressure is low

SRI VENKATESWARA DENTAL COLLEGE & HOSPITAL
DEPARTMENT OF ORAL & MAXILLOFACIAL SURGERY
THALAMBUR, CHENNAI - 103

Pathophysiology

Dilatation of systemic vasculature

↓

Decreased systemic arterial pressure

↓

Pooling of blood in systemic venous & veins

↓

Right heart filling & stroke volume decrease

↓

Decrease pulmonary blood volume & left heart filling.

↓

Discharge of angiotensin & vasopressin

Management

Trendelenburg position

Administration of fluids

Vasoconstrictor drugs

phenylephrine

Metaraminol.

Mohan. R

SRI VENKATESWARA DENTAL COLLEGE & HOSPITAL
DEPARTMENT OF ORAL & MAXILLOFACIAL SURGERY

General Surgery.

I. Elaborate on:

1. Levels of cervical lymphnodes. Describe lymphatic drainage of Head and Neck.

Levels of Cervical lymphnodes:

Level I: I(A): Submental lymphnode
I(B): Submandibular lymphnode.

Level 2: Lymphnodes in the upper deep cervical region. Extends from the base of the skull to the hyoid bone and form the lateral margin of sternohyoid to posterior border of sternomastoid muscle.

Level 2 (a): It is below and in front of the line of spinal accessory nerve in the upper part and

Level 2(b): It is above and posterior to the line of spinal accessory nerve.

Level III: Lymphnodes in middle cervical region (Middle jugular nodes) i.e from omohyoid muscle / cricothyroid membrane.

Level IV: Lymphnode in lower cervical region (i.e) from omohyoid muscle / cricothyroid membrane to the clavicle.

Level V: Lymphnodes in the posterior triangle including supraclavicular region from posterior border of sternocleidomastoid muscle to anterior border of trapezius muscle.

Level Va: Above the line of spinal accessory nerve in lower part.

Level V b: Below the level of spinal accessory

Level VI: Lymphnodes in the midline neck - pretracheal and prelaryngeal from hyoid bone above to suprasternal notch below medial border of carotid sheath on either side.

Level VII: Lymphnode in the mediastenum inferior to suprasternal notch to innominated artery below.



Lymphatic drainage of the lymphnodes:

Level Ia lymphnodes: Floor of the mouth, anterior oral tongue, anterior mandibular alveolar ridge, lower lip.

Level Ib lymphnodes: Oral cavity, anterior nasal cavity, soft tissue of mid-face, submandibular gland.

Level II a and II b lymphnodes: Oral cavity, nasal cavity, oropharynx, nasopharynx, hypopharynx, larynx, parotid gland.

Level III lymphnodes: Oral cavity, oropharynx, nasopharynx, hypopharynx, larynx.

Level IV lymphnodes: Hypopharynx, thyroid, cervical, esophagus, larynx.

Level V lymphnodes: scalp, parotid gland, nasopharynx, thyroid gland.

Level VI lymphnodes: Thyroid gland, glottis, subglottic larynx, apex of pyriform sinus, cervical esophagus.

---

2. Define shock. Describe in detail about the pathophysiology, management of neurogenic shock.

Shock:

Shock is defined as an acute clinical syndrome characterized by hypoperfusion and severe dysfunction of vital organs. There is a failure of the circulatory system to supply blood in sufficient quantities (or) under sufficient pressure necessary for the optimal function of organs vital to survival.

Classification:

- Hypovolaemic shock.
- Cardiogenic shock.
- Distributive shock.
- Obstructive shock.

Neurogenic shock:

It is a life-threatening condition caused by irregular blood circulation in the body.

Causes:

High spinal cord injury.
Vagolytic shock.

Features:

Hypotension without tachycardia, may deteriorate to produce shock and cardiac arrest.

Pathophysiology:

Structural compression.
↓
Decreased venous return
↓
Decreased stroke volume.
↓
Decreased cardiac output.
↓
Cellular oxygen supply decreased.
↓
Decreased Tissue perfusion.
↓
Impaired cellular metabolism.

Management:

Acute stage:

⇒ Maintaining the ability to breathe.
⇒ Preventing shock.
⇒ Immobilizing neck to prevent further spinal cord damage.
⇒ Avoiding possible complications, such as stool or urine retention, respiratory (or) cardiovascular difficulty and formation of deep vein blood clot in extremities.

Medications:

Intravenous - methylprednisolone has been used as an treatment option for spinal cord injury

DEPARTMENT OF ORAL & MAXILLOFACIAL SURGERY SAVEETHA DENTAL COLLEGE THALAMBUR, CHENNAI - 103

Immobilization:

To need traction - to stabilize the spine, to bring the spine into proper alignment (or) both.

Surgery:

Surgery is necessary to remove the bony fragment, foreign objects, herniated disks (or) fractured vertebrae that appear to be compressing the spine.

II. Short Notes:

1. TRISMUS:

- Trismus (or) 'lock jaw' is caused due to spasm of muscles of mastication
- Patients affected by trismus have an inability to open their mouth.
- Normal opening is 40mm (or) three finger gap.
- Trismus can be classified as.

  Mild >30mm.
  Moderate - 15-30mm.
  Severe <15mm.

Causes:

⇒ Spasm of muscles of mastication due to any trauma (or) injury to the trigeminal nerve.

⇒ Infection : This can be due to many reasons such as pulpal, periodontal origin around the third molar.

⇒ Trauma : Fracture of bones of jaw

⇒ TMJ disorders : Tumors
Congenital

⇒ Treatment :
- Heat therapy
- Analgesics drugs
- Anti-Inflammatory drugs
- Physiotherapy.

---

2. Antibiotic prophylaxis of Infective endocarditis :

Standard regimen Amoxicillin.	2g	oral	1 hour before procedure.
Penicillin allergy.			
Azithromycin.	500mg	oral.	1 hour before procedure.
Cephalexin	2g	oral	
Clindamycin.	600mg	oral	
Ampicillin	2g	IV	1 hour before procedure

⇒ Patients with valvular and congenital heart disease who are at high rise of endocarditis should receive prophylactic antibiotics before undergoing any procedures.

⇒ Cardiac lesions for which antibiotic prophylaxis is recommended before dental procedure as :
- Previous episode of endocarditis.
- Patients with prosthetic heart valves.

- Cyanotic congenital heart diseases.

DEPAR... & ...CIAL ...RY THALAMBUR, CHENNAI - 103

3. Biopsy:

⇒ The process of obtaining tissue for the diagnosis is called biopsy.

⇒ There are various types of biopsies.

1) Fine needle aspiration cytology / Fine needle aspiration biopsy (FNAC / FNAB):

- Cells are identified here, hence the name.
- A fine needle of 23 (or) 24 gauge is used to introduce into tumor (or) swelling, without removing, it is passed 3-4 times within lesion in different direction.
- Cells are stuck into the needle (or) syringe.
- 3-4 smears are made and are dipped in 95% ethyl alcohol solution.

Eg: Thyroid swellings, breast, parotid swellings, lymphnodal swelling.

2) True cut biopsy / Core needle biopsy:

- Yields sufficient tissue to achieve diagnosis.
- After giving LA, 1-2 ml of small skin nick is made.
- Should not be done in thyroid swellings because thyroid swellings are vascular.

3) Punch biopsy:

- Long instrument called punch biopsy forceps are used.
- Done in cauliflower like lesions (or) exophytic lesions.

4) Wedge biopsy:

- Done in malignant ulcer suspect.
- Edge is selected as it rapidly grows thus hence maximum cancerous tissue is present.

5) Incision biopsy:

When lymphoma (or) tuberculosis with matted nodes is suspected.

6) Full thickness excision biopsy:

Suspected recommended and done for malignant melanoma.

---

4) Tetanus:

It is an infective condition caused by clostridium tetani leading to reflex muscle spasm.

Pathogenesis:

Spore enters the wound.

↓

Germinates in anaerobic media releasing bacteria, which multiply.

↓

Release of Exotoxins.

↙ Tetanosporin → circulation → Peripheral

↘ Tetanolysin → ↓ Haemolysis.

SRI VENKATESWARA DENTAL COLLEGE & HOSPITAL
DEPARTMENT OF ORAL & MAXILLOFACIAL SURGERY
THALAMBUR, CHENNAI - 130

Clinical features :

Symptoms :

- Jaw stiffness.
- Anxiousness
- Headache.
- Dysphagia.
- Dyspnea.

Signs :

- Trismus.
- Risus sarcodicus.
- Neck rigidity.
- Tonic clonic convulsions.
- Hyper reflexia.
- Fever & Tachycardia.

3

Types :

- Early tetanus
- Latent tetanus.
- Ascending tetanus.
- Descending tetanus.
- Cephalic tetanus.

Complications :

- Fractured bone
- Haematoma
- Carditis
- Toxaemia.

Treatment :

⇒ Antitetanus globulin - 3000 units IM / single dose.

⇒ Antiserum - Antitetanus - 1000 units

⇒ IV - diazepam (20mg)
IV - phenobarbitone (30mg).
IV - chloropromazine (25mg).

⇒ Ventillator support.

5. Cystic Hygroma:

- Failure of one of the lymphatics to join the major sac of the body results in lymphangioma.
- In the neck, it is called as cystic hygroma of the neck.

Clinical features:

* Usually cystic hygroma present during infancy (or) early childhood.

* When the child cries (or) strains, the swelling increases in size and becomes prominent due to increased intra-thoracic pressure which is transmitted through root of the neck.

* Typical locations - lateral aspect of neck (posterior triangle), groin, buttocks.

* soft, cystic, fluctuant, partially compressible swelling.

* The swelling is brilliantly transilluminant because it contains clear fluid.

Treatment:

* Surgical excision.
* All the loculi (or) cyst should be removed.

Differential diagnosis:

⇒ Haemangioma.
⇒ Lipoma.
⇒ Cold abscess

6. Ludwig's Angina :

It refers to cellulitis of submental and submandibular regions combined with inflammatory edema of the mouth.
Virulent streptococcal organisms are responsible for infections surrounding the submandibular region

MALAMBUR, CHENNAI - 107

Clinical features :

⇒ Elderly patients who are present with diffuse swelling in the submandibular and submental region (Brawny oedema)

⇒ Oedema of the floor of the mouth.
⇒ High grade fever with toxicity.
⇒ Putrid halitosis is an characteristic condition

Treatment :

- Rest and hospitalization
- Appropriate antibiotics.
- IV fluids to correct dehydration.
- If not rectified, surgery is indicated

Complications :

1. Mediastinitis and Septicemia
2. Oedema of the glottis due to spread of the cellulitis via a tunnel occupied by

7. Warthin's Tumor:

* It is also called as adenolymphoma.
* It is an benign salivary gland tumor.
* Origin of lymphadenoma:

During development some parotid tissues gets included with lymphnodes; which are present within the parotid sheath.

Histology:

- It is composed of double layered eosinophilic epithelium, inner cells are columnar.
- Presence of lymphatic tissue in the stroma, and lymph follicles.

Clinical features:

- Midle aged (or) elderly males are commonly affected - usually they are smokers.
- Can be bilateral in some cases.
- It has smooth surface, round border with soft, cystic consistency.
- May be multicentric.
- This tumor affects only parotid gland.

Treatment:

It has got a well-defined capsule, Hence enucleation can be done.

8. Tracheostomy:

"Making an opening in anterior wall of trachea and converting it into a stoma on skin surface

DEPART... ORAL & AL ...OLHY ... IHALAMBUR, CHENNAI - 103

Functions of Tracheostomy:

⇒ Respiration through alternative pathway in case of obstruction above the stoma.

⇒ Alveolar ventilation is improved due to reduction in dead space by 30-50% and reducing resistance to airflow.

⇒ Protection of airway by way of cuffed tracheostomy tube, i.e protection from aspiration of pharyngeal secretions in comatose patients and blood due to injuries in pharynx, larynx, maxillofacial region.

⇒ Trachealbronchial toilet.

⇒ Administer anesthesia.

Indications:

- Respiratory obstruction:

  Infections: Ludwig's angina, acute epiglottitis, peritonsillar, retro-pharapharyngeal abscess.

  Tumor.

  Foreign body.

  Laryngeal oedema.

  Bilateral abductor vocal cord palsy.

- Retained secretions (inability to cough):

  Comatose patient.

  Respiratory muscle paralysis.

  Painful cough - trauma to chest.

  Aspiration of pharyngeal secretions

- Respiratory insufficiency:

Due to chronic lung conditions like emphysema, chronic bronchitis, bronchiectasis

Types:

- Emergency.
- Elective (or) permanent

Technique:

If possible patient is intubated prior to surgery.

Position: Supine with neck extended under local or general anesthesia.

Complication:

- Early:
  - Bleeding.
  - Injury to esophagus
  - Injury to recurrent laryngeal nerve.
  - Wrong placement of tracheostomy tube.
- Intermediate:
  - Secondary infection of wound.
  - Blockage of the tube
- Late:
  - Tracheal stenosis.
  - Scar and Keloid.

DEPARTMENT OF ORAL & ... ACIAL ... ERY
SRI VENKATESWA... HOSPITAL
THALAMBUR, CHENNAI - 103

9. Lymphoma:

This is an malignant neoplasm of lymphoreticular system.

Pathology:

- Disease starts usually in one of the lymphnodes as a painless swelling.
- Involves the left supraclavicular region. The nodes are enlarged without matting.
- The axial lymphatic system is almost always affected in Hodgkins disease.
- Microscopy: "cellular pleomorphism", lymphocytes, histiocytes, eosinophils and fibrous tissue with REED STENBERG CELLS.

Classification:

REAL: (Revised European american lymphoma)

- Lymphocyte Predominance, nodular.
- Classic Hodgkin's lymphoma.
  - ⇒ Nodular sclerosis
  - ⇒ Lymphocyte rich
  - ⇒ Lymphocyte depletion
  - ⇒ Mixed cellularity.

Clinical features:

- Age: Bimodal distribution.
- Sex: Increased incidence found in males.
- Present as generalized lymphadenopathy.

- The nodes are firm & Rubbery.
- Abdominal pain can occur due to hepatosplenomegaly.
- Para-aortic nodes are felt in the umbilical region.
- There may be ascites.
- Intermittent fever.
- Multiple bony pains.
- Superior vena caval obstruction.

Treatment:

⇒ Radiotherapy (Stage I)

Dose: 3500 - 4500 (Centigray).

Causes of death in lymphoma:

- Recurrent respiratory tract infection
- Disseminated disease.
- Bo Multiple bony metastasis, pathological fracture, paraplegia.

DEPARTMENT OF ORAL & MAXILLOFACIAL SURGERY
SRM DENTAL COLLEGE
THALAMBUR, CHENNAI

10. Carbuncle:

⇒ This is an infective gangrene of subcutaneous tissue caused by staphylococcus aureus.

⇒ commonly occurs in diabetic patients

⇒ Site: Nape of the neck.

⇒ Pathology:

- The lesion is similar to a boil in the form of hair follicle infection with perifolliculitis.
- Infection proceeds and causes necrosis of subcutaneous fat which gives rise to multiple abscess.
- These abscesses are inter communicating and they open to the exterior by multiple openings which are called sieve-like openings.
- This appearance is described as cribriform appearance which pathognomic of carbuncle.

⇒ Clinical features:

- Typically, patient is diabetic.
- Severe pain and swelling in the nape of the neck.
- Fever with chills and rigors are severe.
- surface is red, angry looking like a red hot coal.
- The end result is development of large crateriform ulcer with central slough.

⇒ Complications :

- Worsening of the diabetic status
- Extensive necrosis of the overlying carbuncle → acute infective gangrene.
- Speticemia
- Toxaemia

⇒ Treatment :

- Diabetes control.
- Parenteral antibiotics.
- Surgery : Cruciate incision

Raghavendran S

SRI VENKATESWARA DENTAL COLLEGE & HOSPITAL
DEPARTMENT OF ORAL & MAXILLOFACIAL SURGERY
THALAMBUR, CHENNAI - 103

Remedial test:

General Surgery.

1. Level of lymphnodes and lymphatic drainage of head and neck.

33/70

Level I: Lymphnodes in Submandibular & Submental nodes.

Level II: Upper jugular nodes: Superiorly from posterior belly of digastric to hyoid bone inferiorly.

Level III: Middle jugular nodes: From hyoid superiorly to cricothyroid membrane inferiorly

Level IV: Lower jugular nodes. From cricothyroid membrane superiorly to clavicle inferiorly.

Level V: Posterior cervical region. From lymphnodes in posterior body.

Level VI: Anterior compartment nodes. From hyoid bone superiorly to suprasternal notch inferiorly and laterally by medial border of carotid sheath.

Level VII: Upper mediastinal nodes. Inferior to suprasternal notch

Lymphatic drainage of head and neck.

Lymphatic drainage of face.

Submental group

Submandibular group

Preauricular or parotid group of lymphnodes.

Areas drained by submental group

- Tip of tongue
- central part of lower lip.
- Four incisors of mandible
- central part of floor of mouth
- chin

Areas drained by submandibular group.

- Medial half of frontal region.
- Medial half of eye region.
- Nose
- upperlip
- Lateral part of lower lip.
- Medial part of cheek or buccal region.

Areas drained by preauricular group

- Lateral half of frontal region.
- Lateral half of eye region.
- Lateral part of cheek region.

SRI VENKATESWARA DENTAL COLLEGE & HOS.
DEPARTMENT OF ORAL & MAXILLOFACIAL SURGERY
THALAMBUR, CHENNAI - 103

Superficial group of lymphnodes

↓

Upper deep cervical group of jugulodigastric.

↓

Deep cervical group or jugulo-omohyoid

↓

Right side

↓

Right lymphatic duct

↓

Right brachiocephalic vein

↓

Superior vena cava

Left side

↓

Thoracic duct

↓

Left brachiocephalic vein

↓

Superior vena cava

2) Shock

Shock is defined as acute clinical syndrome characterized by hypoperfusion and severe dysfunction of vital signs

Pathophysiology of neurogenic Shock

Decreased effective circulatory blood volume

↓

Decreased cardiac output

↓

Decreased blood flow

↓

Decreased supply of O_2

↓

Anoxia

↓

Neurogenic shock.

Etiology

→ Spinal cord injury.

→ Bradycardia, hypotension, arrhythmias.

ISWARA DENTAL COLLEGE & HOSPITAL
DEPARTMENT OF ORAL & MAXILLOFACIAL SURGERY
ALAMBUR, CHENNAI - 133

...nical features

History of emotional stress

Bradycardia

Tachypnea.

Fainting

Treatment

→ Vasocontrictors for blood pressure control.

→ Oxygen administration

→ Hemodynamics maintained.

→ Airway should be cleared.

→ Fluid therapy - given.

→ Intravenous methyl prednisolone therapy done.

→ Dopamine, phenylephrine can be used.

II) Trismus

Difficulty in opening mouth is called trismus.

Normal mouth opening - 35 - 45mm

Grades.

Grade I : mouth opening between 2.5 cm - 4 cm.

Grade II : Between 1 and 2.5 cm

Grade III : Less than 1 cm.

Common causes of Trismus.

- oral Submucous Fibrosis.
- TMJ involvement - ankylosis, dislocation, Synovitis
- Mandible fractures.
- Pterygoid muscle infiltration by growth in retromolar region
- Acute inflammatory lesions in oral cavity
- Tetanus.
- Tetany.
- Postradiation fibrosis

Antibiotic prophylaxis for Infective endocarditis.

Situation	Agent	Adults	Children
Able to take oral medication	Amoxicillin.	2 g	50 mg / kg.
Unable to take oral medication	Ampicillin	2 g IM or IV	50 mg / kg IM or IV
	Cefazolin or ceftriaxone.	1 g IM or IV	50 mg / kg IM or IV
Allergic to penicillin or ampicillin. and able to take oral medication	cephalexin.	2g.	50 mg / kg.
	Clindamycin	600 mg	20 mg / kg.
	Azithromycin or clarithromycin	500 mg	15 mg / kg.
Allergic to penicillin or ampicillin. and unable to take oral medication	cefazolin or ceftriaxone.	1g IM or IV.	50 mg/kg IM or IV
	Clindamycin	600 mg IM or IV	20 mg/ kg IM or IV

SAVEETHA DENTAL COLLEGE & HOSPITALS
DEPARTMENT OF ORAL & MAXILLOFACIAL SURGERY
SAVEETHA NAGAR, THANDALAM, CHENNAI - 103

3) Biopsy

- Fine Needle Aspiration Cytology / Biopsy (FNAC/ FNAB):

  - Needle of 23 or 24 guage, is introduced into tumor or swelling
  - Without removing the needle out of skin over lump, 3 or 4 times it is passed within lesion in different directions. During aspiration cells are sucked into needle or syringe. once the needle is removed disconnect the needle, fill the syringe with air and contents are pushed and 3-4 smears made. Slides dipped in 95% ethanol and send for histopathological examination.

  Eg: FNAC for thyroid, breast and parotid swellings.

- Tru cut / core needle biopsy.

  FNAC cannot differentiate subtype of malignancies as in lymphoma or in carcinoma breast.

Used in Investigation of choice in soft tissue Sarcoma, carcinoma breast, lymphnode metastasis in neck

ESWARA DENTAL COLLEGE & HOSPITAL
DEPARTMENT OF ORAL & MAXILLOFACIAL SURGERY
THALAMBUR, CHENNAI - 603

Punch biopsy.

- Using punch biopsy forceps, punch of tissues is removed by closing the blades of this instrument.

In proliferative or cauliflower like lesions or exophytic lesion.

No LA given during procedure.

Wedge biopsy from the edge of ulcer/ growth.

Selection of edge because

- Wedge of normal skin is removed to know the depth of invasion which is important in malignant melanomas.

- Edge is rapidly growing area hence maximum cancerous tissue is present.

Eg: Epithelioma (squamous cell carcinoma), Malignancy developed in chronic ulcer. (Marjolin's ulcer)

Incision biopsy.

Incision biopsy is better avoided when suspecting metastasis in neck. because incision may break the barrier of spread and result in spillage of cells in subcutaneous plane.

Eg : Lymphoma,
Tuberculosis with matted nodes.

Full thickness excision biopsy.

For cases of suspected malignant melanoma
Full thickness to access depth of invasion
which decides the staging and treatment.

4. Cystic hygroma.

Lymphangeoma due to failure of one of the lymphatics to join the lymphnodes. result in lymphangeoma.

When confined to subcutaneous plane, it is called cystic hygroma.

Clinical features

- Presents during infancy or childhood
- When the child cries or strains, swelling increases in size and becomes prominent due to increased intrathoracic pressure.
- Location : lateral aspect of neck, groin, buttocks.

swelling - brilliantly transilluminant.

SRM DENTAL COLLEGE & HOSPITAL
DEPARTMENT OF ORAL & MAXILLOFACIAL SURGERY
THALAMBUR, CHENNAI - 103

Treatment:

Surgical excision.

Differential Diagnosis:

- Hemangioma.
- Lipoma
- Cold abscess

Complications

- In infants & neonates, lymphangioma can cause difficulty in breathing due to large size.
- secondary infection.
- lymphangioma in mediastinum cause dyspnoea, dysphagia due to compression on trachea/ oesophagus

5) Tetanus.

- Caused by Clostridium tetani.
- Serious disorder with very high mortality even with treatment.

Types

- Tetanus neonatarum.
- Local tetanus
- Cephalic tetanus

- Bulbar tetanus
- Latent tetanus.
- puerperal tetanus
- post operative tetanus
- otitis tetanus

Clinical features

Trismus or lock jaw

Dysphagia.

Neck rigidity

Rigidity of back muscles.

Risus sardonicus.

Generalised convulsions

Mild fever.

Tachycardia.

Management

Admission and isolation.

Wound care.

Injection tetanus toxoid. - 0.5ml IM

Antitetanus globulin

...WARA DENTAL COLLEGE & ...PITAL
DE... ...MENT OF ORAL & ...CIAL SURGERY
...HALAMBUR, CHENNAI - 103

...'s Angina:

...ulitis of submental and submandibular regions combined with inflammatory edema of mouth.

Clinical features.

- Diffuse swelling (Brawny edema).
- Oedema of floor of mouth; as result of tongue is pushed upwards resulting in difficulty in ~~swelling~~ swallowing
- High fever.
- putrid halitosis.

Treatment:

Rest and hospitalization.

Appropriate antibiotics.

IV fluids to correct dehydration

Ryle's tube feeding.

Surgery:

Under GA, 5-6 cm curved incision made below mandible in submandibular region.

Submandibular gland mobilised, mylohyoid muscle divided and pus drained

Even pus not found.

fluid comes out greatly

improving condition of patient.

- Wound is sutured after irrigation.
- Drainage tube is kept in place.

complications.

- Mediastinitis
- Septicaemia.

7) Warthin's Tumor.

→ Adenolymphoma. (Also)

→ Exclusive benign tumour of parotid gland.

→ About 10% of parotid tumors.

Histology

→ Double layered eosinophilic epithelium.

inner cells are columnar.

→ presence of lymphatic tissue in stroma and lymphatic follicles is characteristic of adenolymphoma.

features.

SAISWARA DENTAL COLLEGE & HOSPITAL
DEPARTMENT OF ORAL & MAXILLOFACIAL SURGERY
THALAMBUR, CHENNAI - 103

Age: Middle or elderly aged

Sex : Male.

Site : Bilateral.

Appearance : Smooth, soft cystic.

~~Histology~~ : ~~Honeycomb~~.

Treatment:

→ Has well defined capsule.

→ Enucleation done.

8). Tracheostomy

Making an opening in anterior wall of trachea and converting it into a stoma

Functions of tracheostomy

. Respiration through alternative pathway incase of obstruction above stoma.

. Alveolar ventilation is improved due to reduction in dead space by 30-50%.

. protection of aspiration of pharyngeal secretions in comatose patients and blood. due to injuries in pharynx, larynx, maxillofacial regions.

. Tracheobronchial toilet

. Intermittent positive pressure respiration (IPPR) if required > 72 hours.

GOVERNMENT DENTAL COLLEGE & HOSPITAL
DEPARTMENT OF ORAL SURGERY
CHENNAI

• Administer Anaesthe

Types

Emergency

Elective

Permanent

Technique.

Position : Supine with extended neck under LA or GA

~~Procedure~~ Complications

Early

Bleeding

Injury to oesophagus.

Intermediate

Secondary infection

Tube Blockage.

Late

Tracheal stenosis.

Scar and keloid

Postoperative care.

→ Suctioning : Every 1/2 hourly.

→ Deflate cuff every hour for 5 minutes

→ Supervision for bleeding, breathing difficulty due to difficulty due to displacement of tube, Subcutaneous

...WARA DENTAL COLLEGE & HOSPITAL
DEPARTMENT OF ORAL & MAXILLOFACIAL SURGERY
...THALAMBUR, CHENNAI - 103

...uncle.

Infective gangrene of Subcutaneous tissue of staphylococcus aureus.

→ common in diabetic patients.

Sites : Nape of neck.
Back
Shoulder region.

Clinical features.

- Severe pain
- Swelling.
- Fever with chills and rigors are severe.
- Surface - red hot coal.
- Surrounding area - indurated
- Development of larger crateriform ulcer with central slough.

Complications:

→ Worsening of diabetic status resulting in diabetic ketoacidosis.

→ Acute infective gangrene.

→ Septicemia

→ Toxaemia.

Treatment.

→ control of diabetes with injectable insulin

→ Parenteral antibiotics.

→ Surgery with cruciate incision

10) Lymphoma.

Malignant neoplasms originating in bone marrow & lymphatic structures.

Classification

Hodgkin's lymphoma.

Non-Hodgkin's lymphoma

Hodgkin's lymphoma.

→ Malignancy in specific white blood cells.

Non-Hodgkin's lymphoma.

→ Blood cancer that includes any kind of lymphomas except Hodgkin's lymphoma.

Symptoms

Fatigue

Fever

~~Recurrent~~ Weight loss



SRI VENKATESWARA DENTAL COLLEGE & HOSPITAL
DEPARTMENT OF ORAL & MAXILLOFACIAL SURGERY
THACHUR, CHENNAI - 103

→ Palpable lymphnodes.

→ Severe itching.

→ Fever with night sweats.

Management

A-B VD regiment (Adriamycin, bleomycin, Vinblastine, Dexarbazine)

Radiation therapy

Stem cell transplantation

GENERAL SURGERY.

Rakshaya. S.N
THALAMBUR, CHENNAI - 103

Short note:

1. TRISMUS:

It is refer to a sustain, tonic spasm of the maxillary muscles, particularly the masseter and temporalis.

The restriction of mouth opening occur due to infection, trauma, Surgery (or) radiation.

Normal opening of Mouth: may vary from patient to patient.

range of 40-60mm.

Classification of Trismus:

Based on rage of Mouth opening.

Mild trismus = 30-40mm.

Moderate trismus = 15-30mm.

Severe trismus = < 15 mm.

Based on Duration.

Acute trismus.

Sub acute trismus.

chronic trismus.

Based on Aetiology:

Intra-articular.

Extra-articular.

Clinical features:

. Pain during forced mouth opening.
. Duration of mandible.
. Sensation of Muscle tightness, cramping (or) stiffness.
. Speech impairement referred to "hot potato voice"
. Impaired oral intake.
. Loss of weight.
. Poor oral hygiene.
. Aspiration.
. Difficult in breathing.

Management:

Conservative Medical Management:

Heat ⇒ placement of moist hot Towel on affected area for 10 - 20 min / hr.

Analgesic therapy - Aspirin is the most common. when discomfort is extensive, narcotic analgesic may be indicated.

Soft diet.

Muscle relaxants - In extensive masticatory muscle spasm, benzodiazepines 2.5 - 5 mg 3 times a day may be inf. indicated.

SRI VENKATESWARA DENTAL COLLEGE & HOSPITAL
DEPARTMENT OF ORAL & MAXILLOFACIAL SURGERY
THALAMBUR CHENNAI - 103

. Antibiotic such that antidepressant diazepam (2.5 - 5mg) three time daily.

2) Antibiotic prophylaxis for Infective Endocarditis.

Patient not allergic to penicill, oral intake.

. cephalixin.
cephradin
Amoxicillin.

Patient not allergic to penicill unable to orally.

cefazolin - 1g IM/IV.
Ampicillin - 2g IM/IV.

Patient Allergin to penicillin:

clindamycin.

Patient allergic to penicillin and unable to take orally.

clindamycin.
cefazolin.

3. Biopsy:

Biopsy is the removal of tissue from living organism for the purpose of microscopic examination & diagnosis.

Types.

Excision Biopsy:

Single small swelling such lymph node It can be done general anesthesia incision made over swelling allowed histological evaluation called excision.

Fine needle Aspiration cytology:

Tumor swelling removing the needle out skin over the lump different procedure negative pressure cell.

True-cut Biopsy:

Immuno histo chemistry play major role management FNAC cannot malignancies lymphoma carcinoma breast tissue small ~~cannot~~ dressing applied.

Punch Biopsy.

Long instrument forceps, punch of the tissue removed by closing the blade instrument

Wedge Biopsy:

Typically done suspect malignant ulcer epithelioma chronic ulcer / scar edge rapidly cancerous tissue present wedge of normal

SRI VENKATESWARA DENTAL COLLEGE & HOSPITAL
DEPARTMENT OF ORAL & MAXILLOFACIAL SURGERY
THALAMBUR, CHENNAI - 103

Incision Biopsy:

Suspect lymphoma malted node incision over swelling after giving anesthesia agent lymph node dissected all around lymph node removed meta stasis neck.

Full Thickness Excision Biopsy:

Strongly recommended and done malignant melanoma depth of Invasion decides staging treatment.

Tetanus:

Serious disorder with very high mortality with treatment disease caused by clostridium Tetani anaerobic spore forming bacillus terminal spores drumstick appearance.

Development of Tetanus:-

No Immunisation
Foreign body.
Injury.
Improper sterilization.
Anaerobic condition.

Types :-

. Tetanus neonatorum
. Local Tetanus
Cephalic Tetanus
Bulbar Tetanus
Latent Tetanus
Puerperal Tetanus

Clinical features :-

. Anatomic dysfunction
Increased basal and bladder, bowel dysfunction, labile BP hypertension, pyrexia, pallor, Swelling, cyanosis.
Episodes of bradycardia
Urinary Tract Infection.
Pneumonia.

Management :

General management :

Admission and isolation of child room avoid minor Stimuli & Spasm.

wound care :

drainage of pus, excision removal of foreign body.

Injection Tetanus Toxoid :

0.5ml IM.

SRI VENKATESWARA DENTAL HOSPITAL
ORAL
AL
THALAMBUR CHENNAI - 103

Mild cases:

. Benzodiazepam and morphine

. Chlorpromazine receptor blocker

Serious cases:

- They have dysphagia reflex spasm.

. nasogastric tube.

. Tracheostomy

5. Cystic hygroma:

It is a cystic swelling lined by endothelial cell.

Failure of one of lymphatics join majo lymph sac result in lymphangioma.

Common site - posterior triangle of neck of axilla, mediastinum, groin etc.

Lymphatics by time swelling lymph replaced thin watery fluid secreted by endotheliem.

Subcutaneous plane called cystic hygroma.

cause - Neonates, Infants, children.

Clinical features:

Straining, swelling increase in size become prominent intrathoracic transmitted through root of the neck.

Topical location - Lateral Aspect of Treatme
neck.
Soft, cystic fluctuant, Multilocular
Swelling aggregation multiple cyst.
complete reducibility not a feature
swelling bilaterally Transluminated

Differential Diagnosis:
Hemangioma
Lipoma.
cold Abcess.

Treatment:
Surgical Excision.
Sclerotherapy lymphangioma Sclerosant.

6. Ludwig Angina:

Submental and Submandibular region combined by Inflammatory edema of mouth virulent streptococci organism infection Submandibillar region anaerobes also maja role.

Clinical features:
Elderly patient - Swelling submandibular and Submental region.
edema over floor of the mouth - Tongue pushed upward result difficulty Swallowing.
High grade fever with toxicity
Putrid halitosis.

SRI VENKATESWARA DENTAL COLLEGE & HOSPITAL
DEPT. OF ORAL & MAXILLOFACIAL SURGERY
THALAMBUR CHENNAI - 103

Treatment :-

Rest & hospitalisation
Appropriate Antibiotic.
Intravenous fluid correct dehydration Ryle's tube feeding.
conservative Treatment Surgical intervation recommended.

Surgery:

General Anesthesia 5-6cm curved incision below the mandible the submandibular region. Swelling mobilized mylohyoid muscle Pus drained edematous fluid loose suture irrigating cavity antiseptic agent drainage tube is placed.

complication:

Mediastinitis & sepsicemia
Edema & glossitis.

7. Warthin's Tumor:

Adenolymphoma is not a lymphoma.
Second most Benign salivary gland tuma
Major salivary gland : Parotid gland.

Histology:

It is composed of double layered eosinophillic epithelium. inner cell are columnar.
Presence of lymphatic tissue lymph follicle adenolymphoma.

Clinical features:

Middle Aged elderly male are common affected they are Smokers.

can be bilateral some cases 10%.

Smooth Surface, Round border with soft cystic consistency.

Parotid lower pole elevating over ear lobe.

Multicentric

Treatment:

Surgical Excision.

8. Tracheostomy:

Making an opening in Anterior wall of trachea converting on stroma on skin surface

Function:

Respiration through pathway case obstruction stone.

Alveolar ventilation improved due to reduction dead space 30-50%. resistance airflow.

Tracheobranchial Toilet.

Administer Anesthesia.

SRI VENKATESWARA DENTAL COLLEGE & HOSPITAL
DEPARTMENT OF ORAL
THALAMBUR, CHENNAI - 103

Indication:

- Respiratory obstruction:-
  Trauma - laryngx, trachea, mandible, Fracture.
- Tumor.
- Foreign body.
- Laryngeal edema due to allergy.
- Congenital Anamolies.

Types:-

Method Initial Insertion:

Surgical.
Percutaneous.

Intended Duration

. Temporary Tracheostomy.
. permanent Tracheostomy.

Technique:

Intubated pria surgery.
Position - supine.

Procedure:-

Incision can be vertical (or) transverse.
vein surface retracted & muscle separated midline and thyroid upward.
Trachea exposed.
4.1. xylocaine infiltrated.
Transverse incision made between 2nd and 3rd Tracheal ring.

complications:

Early:
- Bleeding.
- Injury to esophagus.
- recurrent laryngeal nerve.

Intermediate
- secondary infection wound.
- Blockage of tube.

Late:
- Tracheal stenosis.
- Scar and keloid.

9. Lymphoma.

Progressive neoplastic condition lymphoproliferative Disorder arises from stem cell.

Etiology:

Genetic, Sjogren Syndrome, HIV Infection, Ionizing radiation.

Level of cervical lymph node:

Level I:
- In Submental lymph node.
- Submandibular lymph node.

Level II:

Lymph node in upper deep cervical region, below and in front of the line of the spinal accessory nerve the upper part.

Above and posterior to spinal accessory nerve.

Level III:

lymph node in middle cervical region.

Level IV

lymph node lower cervical region.

Level V:

Lymph node in posterior triangle including Supraclavicular region.

→ Above the line Spinal Accessory nerve

→ Below the level of Spinal accessory nerve.

Level VI: lymph node in the midline neck.

Level VII: lymph node in mediastinum.

Treatment:-

Procarbazaine 100mg orally.

1 to 10 day.

Prednisolone 15 mg.

10) Carbuncle :

Infective gangrene of Subcutaneous tissue caused Staphylococcus aureus.

Commonly occur diabetic patient

Site - Nape of the neck Commonest back shoulder region skin site poor vascularity.

Pathalogy :

Boil
↓
Hair follicle.
↓
Diabetic.
↓
necrosis in subcutaneous fat.
↓
Cribriform appearance.

Clinical features:

* Diabetic
* Severe pain and Swelling in a nape of the neck.

Surface red, angry looking red hot coal.

Surrounding area indurated

peripheral satellite vesicle appear rupture discharging.

Complication:

Septicemia, Toxemia

Treatment:

Diabetes control injectable insulin.

Drug vancomycin which given IV.

Improve general health.

X Ray :-

1) Level of cervical lymph node.

Level I:

Ia = Submental lymph node.

Ib = Submandibular lymph node.

Level II: lymph node in upper deep cervical region.

IIa => Below and in front of the line of spinal accessory nerve in the upper cut.

IIb => Above and posterior to line of Spinal accessory nerve.

Level III: lymph node in middle cervical region

Level IV: Lymph node in lower cervical region.

Level V: lymph node in the posterior triangle involving supraclavicular region.

Level V a - Above the line of Spinal accessory nerve.

Level V b - Below the level of Spinal accessory nerve

Level VI : lymph node in midline neck.

Level VII : lymph node in mediastenum.

Drainage area of lymph node :-

Level I a lymph node : Floor of mouth, anterior oral tongue, anterior alveolar ridge, lower lip.

Level I b lymph node : Oral cavity anterior nasal cavity, soft tissue of midface, Submandibular gland.

Level II a and II b lymph node :

Oral cavity = nasal cavity, oropharynx, nasopharynx, larynx, parotid gland.

Level III lymph node :-

Oral cavity, oropharynx, nasopharynx, larynx.

Level IV lymph node :

Scalp, parotid gland, nasopharynx, thyroid gland.

level VI lymph node:

Thyroid gland, glossitis and Subglossitis larynx, apex of pyriform sinus, cervical esophagus.

21 Shock:

Shock is defined as acute clinical Syndrome characterized by hypoperfusion and severe dysfunction of vital organs.

Pathophysiology:

Decrease effective circulatory Blood volume.

↓

Decrease cardiac output

↓

Decrease Blood flow

↓

Decrease Supply of oxygen.

↓

Anoxia.

↓

Neurogenic Shock.

It occurs due to Spinal cord injuries which leads to dilation

Clinical feature:

History of emotional / stress

Bradycardia

Tachycardia

Fainting.

Treatment

Control blood pressure using vasoconstrictor.

oxygen administer.

Airway are closed.

Fluid Therapy.

Dopamine can be used.

SRI VENKATESWARA MEDICAL COLLEGE
DEPARTMENT OF SURGERY
THALAMBUR, CHENNAI - 603

General surgery

(I) Elaborate on

1. Levels of cervical lymph nodes. Describe lymphatic drainage of head and neck

The cervical group of lymph nodes extend from

-> mandible and skull base superiorly

-> clavicle inferiorly.

-> posterior triangle of neck laterally & posteriorly

-> Midline viscera anteriorly.

Levels of Neck Nodes :-

There are 7 levels of neck and most have sublevels containing specific group of nodes.

Level I :- Submental & Submandibular.

Level II :- upper jugular group of lymph nodes.

Level III :- Middle jugular group of lymph nodes.

Level IV :- Lower jugular group of lymph nodes.

Level V :- posterior triangle

Level VI :- Anterior / central compartment

Level VII :- superior mediastinal

Lymphatic drainage of head and neck.

Tissue fluid is produced in excess by the arterial ends of circulatory system.

- The excess fluid, protein, large particulate matters and foreign substances

- The position of the nodes denotes the general location of infection

→ Lymph nodes in the head and neck consist of a number of regional groups and terminal one.

→ They consist of outlying nodes (circular) which all drain into the deep cervical group (Vertical).

→ The outlying nodes are usually subcutaneous while others are deep and are named according to their position.

Regional lymph nodes :-

Submental nodes :-

- Three to four in number, lie beloco the chin.

- Some superficial other deep to the investing deep cervical fascia.

- drain into submandibular group (or) directly into the deep cervical group of lymph nodes

Submandibular Nodes :-

Half a dozen, lie on the surface of submandibular salivary gland (or) embedded within it.

- Drain the submental nodes, lateral part of the lower lip, upper lip and external nose, anterior 2/3rd. of the tongue
- Anterior half of the nasal walls, paranasal sinuses and all the teeth except lower anterior.

Buccal Node :-

- lies over buccinator muscle
- drains into submandibular group.

Periauricular nodes :-

- Lie within parotid gland
- Drain the temporal part, lateral surface of auricle anterior wall of external meatus, and lateral part of the eyelids.
- Drain into deep cervical group.

Posterior auricular nodes :-

→ present on the lateral of the mastoid process.

→ receive lymph from a scalp above the auricle and posterior border of the auditory meatus.

Occipital Nodes :-
- Situated at the apex of the posterior triangle of the neck.
- receive lymph from back of the scalp.

Anterior cervical nodes :-
- Situated in the anterior jugular vein.
- receive lymph from skin and superficial tissues of the front of the neck.

Superficial cervical nodes :-
- lie along course of external jugular vein.
- receive lymph from skin over the angle of mandible and over the apex of parotid gland and lobe of the ear.

Retropharyngeal nodes :-
- lie in retropharyngeal space, between the pharyngeal wall & prevertebral fascia.
- receive lymph from nasal part of pharynx.

Laryngeal nodes :-
- In front of larynx

Tracheal nodes :-
- lateral and in front of trachea
- receive from thyroid gland.

Deep Cervical Nodes :-

- Scatter in carotid sheath, in front and behind the internal jugular vein along its course

- Divided into upper and lower groups.

Upper group :-

→ Receive lymph from posterior part of tongue, tonsil, ear, nose, sinuses, upper part of pharynx and larynx.

Jugulo-digastric nodes :-

below the posterior belly of digastric muscle and is clinically palpable below the angle of the mandible

Drains - in back of the tongue.

Lower group :-

Recive lymph from anterior part of the face, Scalp, anterior 2/3rd of tongue, lower part of pharynx, larynx and thyroid gland.

Jugulo-omohyoid nodes :-

Intermediate tendon of omohyoid muscle.

Drains in anterior part of the tongue.

SRI VENKATESWARA DENTAL COLLEGE & HO... ORAL ...AL ...RY ... THALAMBUR, CHENNAI - 103 ...AL

(2) Define shock. Describe in detail about pathophysiology, management of neurogenic shock

Shock :- It is term used to describe the clinical syndrome that develops when there is a critical impairment of tissue perfusion due to some form of acute circulatory failure

- An acute reduction of effective circulating blood volume (hypotension) and inadequate perfusion of cells and tissues (hypoperfusion)

Classification :

- Hypovolemic shock
- Cardiogenic shock
- Septic shock
- other types :- 1) Traumatic
  2) Neurogenic
  3) Hypoadrenal.

Neurogenic shock :

→ primarily due to blockade of sympathetic nervous system.

→ loss of arterial & venous tone with pooling of blood in the dilated peripheral venous system.

caused by :- paraplegia
- Quadriplegia
- Trauma to spinal cord.
- Spinal anesthesia.

Clinical Features :-

SRI VENKATESWARA DENTAL COLLEGE & HOSPITAL
DEPARTMENT OF ORAL & MAXILLOFACIAL SURGERY
THALAMBUR, CHENNAI - 103

- Warm skin, pink and well perfused
- Heart rate is rapid
- Blood pressure is loco
- Urine output may be normal

Pathophysiology :-

Dilatation of systemic vasculature.

↓

Decreased systemic arterial pressure.

↓

pooling of blood in systemic venules & small vein

↓

right heart filling & stroke volume decreases.

↓

Decreased pulmonary blood volume & left heart filling.

↓

Discharge of angiotensin & vasopressin though. They fail to restore the cardiac output to normal

Management :-

* Assuming Trendelenburg position - displaces blood from systemic venules into right heart & increases cardiac output.

Administration of fluids.

Vasoconstrictor drugs.

Phenylephrine & metaraminol.

Vasovagal shock: part of neurogenic shock

Pathophysiology: pooling of blood due to dilation of peripheral vascular system particularly in the limb muscle & in splanchnic bed

Management: Trendelenburg position - increases cerebral flow & consciousness is restored.

Psychogenic shock:

part of neurogenic shock.

→ occurs following sudden fright from unexpected bad news or horrible accident

Write short Notes on:-

1) Trismus:

* Trismus refers to a sustained, tonic spasm of masticatory muscles. particularly masseter and temporalis which results in forced jaw closure.

* This is the inability to open the mouth can have serious health complications. Like reduced nutrition.

Normal mouth opening:-

→ Normal range of mouth opening varies from patient to patient.

→ Range is 40-60mm

Band on duration

- Acute trismus
- Subacute trismus
- Chronic trismus

(c) Band on Aetiology

- Intra-articular
- Extra-articular

(2) Antibiotic prophylaxis for infective endocarditis.

Oral medications :-

	Adult	Children
Amoxicillin	2g for adult	50 mg/kg for

Pt unable to take orally :-

- Ampicillin	1g (IM or IV)	50 mg/kg
- Cefazolin / ceftriaxzone	500mg (IM or IV)	50 mg/kg.

Allergy to penicillin & ampicillin. but able to take orally.

Cephalexin	2g	50 mg/kg
Clindamycin	600mg.	20 mg/kg
Azithromycin / Erythromycin.	500mg.	15 mg/kg.

Allergic to penicillin. (or) ampicilin and unable to take oral medication.

Cephalexolin Ceftriaxzon	1g (IM or) (IV)	50mg/kg

→ The width of the index finger at the nail bed is between 17 and 19mm. Thus two fingers breath (40mm) upto three fingers breath is the usual width of opening.

→ Gender may be a factor in vertical mandibular opening. Males display greater mouth opening.

Measurement of mouth opening:

- Screening :- Three finger test.
- Measurement tools :- * Boley gauge.
  * Manufacturer's scale
  Dynaplent
  Therabite.

- Influencing factors:
  * Dental alignment
  * Age
  * Gender
  * Ramus length
  * Gonial angle

Classification of trismus:

(A) Based on Range of mouth opening.

Mild trismus :- 30-40mm
Moderate to :- 15-30mm
Severe = ≤15

Biopsy.

It is a surgical procedure to obtain tissue from a living organism for its microscopical examination, usually to perform a diagnosis

SRI VENKATESWARA DENTAL COLLEGE
DEPARTMENT OF ORAL & FACIAL SURGERY
THALAMBUR, CHENNAI - 103

Indications :- Inflammatory changes of unknown cause that persist for long periods.

→ Lesion that interfere with local function.

- Bone lesions is not specifically identified by clinical and radiographic findings.

- Any lesion that has the characteristics of malignancy

3 lesions that raise suspicion of malignancy.

- Erythroplasia
- ulceration
- Duration
- Growth rate
- Bleeding
- Induration
- Fixation.

Types of Biopsy :-

* Four major types

(i) cytology
(ii) aspiration biopsy
(iii) Incisional.
(iv) excisional.

(4). Tetanus :

It is acute bacterial disease caused by the neurotoxin tetanospasmin.

Causative agent :- Clostridium tetani.

- prolonged contraction of skeletal muscle fibres
- It is also called Lockjaw.

→ usually incubation period ranges from 3-21 days but can range from the day of injury to several months

→ Average incubation period is 10 days.

Mode of transmission :-

- Contamination of wounds with clostridium tetani spores.
- Widely distributed in intestines and faeces of many non-human animals such as horses, sheep, cattle, dogs, cats and guinea pigs.
- Tetanus is not spread from person to person.

Features :-

- pain and tingling sensation
- Lock jaw.
- Dysphasia
- Acute asphyxia
- Spasm of pharyngeal muscles.
- fever
- headache.
- Refusal of feeding and excessive crying.

Treatment :
- passive immunization
- Local wound care
- Antibiotics

SRI VENKATESWARA ... HOSPITAL
DEPAR... ORAL
& ...CIAL
...RY
THALAMBUR, CHENNAI - 103

(5)

Cystic hygroma :-

- Lymphatic lesion that can affect any anatomic subsite in the human body
- Usually affects head and neck.
- Synonyms with cystic lymphangioma also known as macrocystic lymphatic malformation are
- Equal sex distribution.

Causes :-
* Karyotypic abnormalities.
* Turner syndrome.
* Down's syndrome.
* Klinefelter syndrome.
* Trisomy 18 and 13.

Pathology :- Arises from the failure of lymphatics to connect the venous system.
- Lack of venous outflow tract.
- failure of lymphatics to connect venous system

Treatment :-
- pure ethanol.
- Bleomycin
- Doxycycline
- Sodium tetradecyl sulfate.

(6) Ludwig's angina.

It is a serious, potentially life-threatening infection of the neck and the floor of the mouth

Pathophysiology :

- It is a rapidly progressing polymicrobial cellulitis of sublingual and submandibular space.
- Results in life threatening air way compromise.
- Causative agent Streptococcus viridans and Staphylococcus aureus.

Etiology :-

- Sialadenitis
- peritonsillar abscess
- Oral lacerations
- Tongue piercing.
- Trauma to the floor of oral cavity
- Upper respiratory infections.
- Epiglottitis.
- Infected thyroglossal duct.

→ Ludwig's is a cellulitis of submandibular space that spreads to structures anterior neck.

→ rather than abscess formation, is the most common early presenting finding.

SRI VENKATESWARA DENTAL COLLEGE & HO
DEPARTMENT OF ORAL & SURGERY
THALAMBUR, CHENNAI - 103

Predisposing factors:

- Dental caries
- Recent dental treatment
- Systemic illness such as Diabetes mellitus.
- Malnutrition
- Alcoholism.
- Organ transplantation & trauma

Clinical manifestations:

→ poor oral hygeine.
→ Tachypnea & Tachycardia
- Swelling & pain in floor of the mouth.
- patients exhibit dysphonia.
- Hoarsen, stridor.
→ Bull's neck

Treatment:

Tracheostomy and drainage

(7) Warthin's tumour.

* It is benign cystic tumour of salivary glands containing abundant lymphocytes & germinal Centers.

Signs and Symptoms:

- primarily affects older individuals.
- slight male predilection.
- Slow growing, painless and usually appears in tail of parotid gland.

Cause :- The main cause is cigarette smoke. They develop & Increase the risk of developing warthin's tumour.

Diagnosis :-

two uniform rows of oncocytes, epithelial cells with abundant, granular eosinophilic cytoplasm.

Treatment :-

Surgical removal of parotid gland (ie) parotidectomy

(8) Tracheostomy :-

- It is a hole that surgeons make through the front neck and into the windpipe.
- A tracheostomy tube is placed into the hole to keep it open for breathing.
- The term for surgical procedure to create this opening is tracheotomy.

Indications :

- Medical conditions that make it necessary to use a breathing machine.
- Conditions that block (or) narrow your airway.
- paralysis, neurological problems.
- Severe trauma of head and neck.

- Injection with Epstein Barr Virus, HIV g,
- Genetic predisposition.
- Occupational toxins such as pesticides (or) benzene.

Clinical features :-

- Fever
- Weight loss
- Cervical axillary, inguinal lymphnodes enlargement.
- Weight loss
- Severe Itching
- Fatigue
- Fever with night sweats.

Management :-

- ABVD regimen : (Adriamycin, Bleomycin Vinblastine, Dacarbazine).
- Radiation therapy
- Stem cell transplantation.

(16) Carbuncle :

* It is a skin infection resulting in the formation of lump that may contain pus.
* Carbuncle is also known as staph skin infection
* It is common among men than in women.

SRI VENKATESWARA DENTAL COLLEGE & HOSPITAL
DEPARTMENT OF ORAL & FACIAL SURGERY
THIRUPATHI, CHENNAI - 103

Symptoms :-

- red boil under your skin the prime Symptoms
- fatigue
- fever
- Irritation
- Swelling
- Itching
- pain around the affected area
- Spreading of lump to other skin areas.

Treatment :-

- Pain killers
- Antibiotic.
- Draining carbuncle with needle by a dermatologist

Prevention :-

- Regularly wash clothes, sheets and towel
- Avoid sharing towel, razor (or) trimmer.
- Always wash hands before eating any thing.

Complication :

- Bleeding
- Damage to trachea, thyroid gland (or) nerves in neck.
- Misplacement (or) displacement of tube
- Air trapped in tissue under the skin

* Tracheostomy is temporary, providing breathing route until other medical

(Q) Lymphoma.

Lymphomas are malignant neoplasms in the bone marrow of lymphatic structures, resulting in proliferation of lymphocytes.

Classification :

(i) Hodgkin's lymphoma
(ii) Non-Hodgkin's lymphoma.

Hodgkin's lymphoma :

- Type of lymphoma in which cancer originates from a specific type of white blood cells called lymphocytes.

Non-Hodgkin's lymphoma :

- It is a different groups of blood cancer that include any kind of lymphomas except Hodgkin's lymphoma

Ruban Jayachandrakumar

SRI VENKATESWARA DENTAL COLLEGE & HOSPITAL
DEPT. OF ORAL & MAXILLOFACIAL SURGERY
THALAMBUR, CHENNAI - 103

Q Elaborate on:

1) Levels of cervical lymph node. Describe lymphatic drainage of head and Neck.

47/70

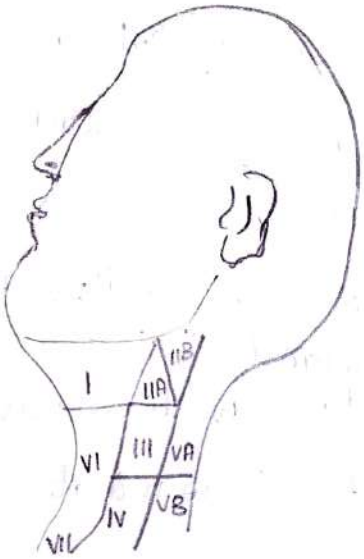

Level I: Submental (Ia) and Submandibular (Ib) Lymph nodes

Level II: Lymph nodes in upper deep cervical region It extends from base of skull to hyoid bone and from lateral margin of sternohyoid to posterior margin of sternomastoid muscle Level IIa is below and in front of line of Spinal accessory nerve.

Level IIb is above and posterior to line of Spinal accessory nerve.

Level III : Lymph nodes in middle cervical region

Level IV : Lymphnodes in lower cervical region

Level V : Lymph nodes in posterior triangle, including Supraclavicular region from posterior border of Sternocleidomastoid muscle to anterior border of trapezius muscle

Va above the line of Spinal accessory nerve in lower part Vb: is below the level of spinal accessory nerve.

Level VI : Lymph nodes in middle neck. pretracheal and pulayngeal

Level VII Lymph nodes in mediastinum. inferior to Suprasternal notch to innominate artery below.

Drainage area of lymph nodes:

Level Ia - lymph nodes : floor of mouth, anterior oral tongue, anterior mandibular alveolar ridge.

Lower lip.

Level Ib lymph nodes: Oral Cavity, anterior nasal cavity, Soft tissue of midface, .

Submandibular gland.

DEP ORAL & AL ... THE TABLE CHENNAI - 103

Level IIa and IIb lymph nodes:
Oral cavity, nasal cavity, oropharynx, nasopharynx, hypopharynx, larynx, parotid gland.

Level III lymph nodes: Oral cavity, oropharynx, nasopharynx, hypopharynx, larynx.

Level IV lymph nodes: Hypopharynx, thyroid, cervical esophagus, larynx.

Level V lymph nodes: Scalp, parotid gland, nasopharynx, thyroid gland.

Level VI lymph nodes: Thyroid gland, glottis, Subglottic larynx, apex of pyriform sinus, cervical esophagus.

classification of neck dissections

(1) classical radical neck dissection

(2) Modified radical neck dissection

Type I (XI preserved)

Type II (XI nerve and internal jugular vein preserved)

Type III (XI nerve, internal jugular vein and sternocleidomastoid muscle preserved)

(3) Selective neck dissection

Supra omohyoid type

Lateral type

posteriolateral type

Anterior compartment type

(4) Extended radical neck dissection

Rule of 80 in neck masses.

2) Define shock. Describe in detail about the pathophysiology, management of neurogenic shock

Shock is defined as an acute clinical syndrome characterised by hypoperfusion and severe dysfunction of vital organs. There is a failure of circulatory system to supply blood in sufficient quantities or under sufficient pressure necessary for the optimal function of organs vital to survival.

Shock

Classification

- Hypovolaemic shock
- Cardiogenic shock
- Distributive shock
- Obstructive shock

Distributive shock.

It occurs when the afterload is excessive reduced. Distributive shock can occur in

- Septic shock
- Anaphylactic shock
- Neurogenic shock
- Acute adrenal insufficiency

Neurogenic shock.

Etiopathogenesis of shock

Decreased effective circulatory blood volume

↓

Decreased cardiac output

↓

Decreased blood low

↓

Decreased Supply of Oxygen

↓

Anoxia

↓
Shock

Causes

High Spinal cord injury

Vagolytic shock

Neurogenic shock:

It occurs due to Spinal cord injury which leads to dilatation of Splanchnic vessels

there will be bradycardia, hypotension, arrhythmias and decreased cardiac output

Clinical features:

History of emotional stress or pain of a Sudden nature.

Bradycardia or pallor.

Tachypnea

Fainting

Reflexes are usually intact.

Treatment:

Blood pressure should be controlled by giving Vasoconstrictors.

Oxygen is administered.

Hemodynamics should be maintained

Air ways are cleared

Fluid therapy should be given

Intravenous methylprednisolone therapy is done

Dopamine & Phenylephrine used.

(1)

Trismus

SRI VENKATESWARA DENTAL COLLEGE & HOSP. DEPT. OF ORAL ... SURGERY THALAMBUR, CHENNAI - 133

Trismus means lock jaw

Trismus is due to involvement of pterygoid muscles and masseter.

This occurs when carcinoma buccal mucosa extends into the retromolar trigone

Trismus can also be due to soft tissue fibrosis caused by radiation.

Once perineural lymphatics are involved spread can occur in infratemporal fossa resulting in trismus.

Trismus means difficulty in opening the mouth is called trismus.

Normal mouth opening ranges from 35 to 45 mm

Grades

Grade I : Mouth opening in between 2.5 and 4 cm

Grade II : Between 1 and 2.5 cm

Grade III : less than 1 cm

common causes of trismus:

① Temporomandibular joint involvement - Such as ankyloses, dislocation, Synovitis etc

② Mandible fractures

③ pterygoid muscle infiltration by growth in the retromolar region

④ Acute inflammatory lesions in the oral cavity.

⑤ Tetanus and tetany.

⑥ Radiation fibrosis of soft tissues / muscles of mastication, Surgical extraction

2) Anti biotic prophylaxis for infectious Endocarditis

SRI VENKATESWARA DENTAL COLLEGE & HOSPITAL
DEPARTMENT OF ORAL SURGERY
THALAMBUR, CHENNAI - 103

Drug	Dose	Route	Timing
Standard Amoxicillin	2g	oral	1hr before procedure
penicillin allergy Azithromycin	500mg	oral	1 hr before procedure
Cephalexin	2g	oral	
Clindamycin	600mg	oral	
Ampicillin	2g	IV	1hr before procedure

patients with Valvular and congenital heart disease who are at high risk of endocarditis should receive prophylatic antibiotics before undergoing any procedures.

⇒ Cardiac lesions for which antibiotics prophylaxis is recommended before dental procedure are

- Previous episode of endocarditis
- patient with prosthetic heart values
- Cyanotic congenital heart disease

3) Biopsy

The process of obtaining tissue for the diagnosis is called biopsy.

=) There are various types of biopsies

① Fine needle aspiration cytology / FNAC / FNAB)

Biopsy.

• cells are identified here hence the name

A fine needle of 23 or 24 gauge is used.

to introduce into tumour or swelling.

without removing, it is passed 3-4 times without removing lessions in different direction

cells are stuck into the needle or syringe

3-4 smears are made and are dipped in 95% ethyl alcohol solution.

Ex: thyroid swellings, breast, parotid swelling lymph nodal swelling.

2) True cut biopsy / Core needle biopsy

Yields sufficient tissue to achieve diagnosis

After giving LA, 1-2 ml of a small skin nick is made.

Should not be done in thyroid swellings because thyroid is very vascular

3) Punch biopsy:

Long instrument called punch biopsy forceps are used

Done in cauliflower like lesions or exophytic lesions

4) Wedge biopsy.

Done in malignant ulcer suspect Edge is excised as it rapidly grows thus here maximum cancerous tissue is present.

5) Excision biopsy

When lymphoma or tuberculosis with matted nodes is suspected

6) Full thickness excision biopsy

Suspected recommended and flow for suspected malignant melanoma

4) Tetanus :

⇒ It is an infectious condition by clostridium tetani leading to reflex muscle spasm.

pathogenesis :

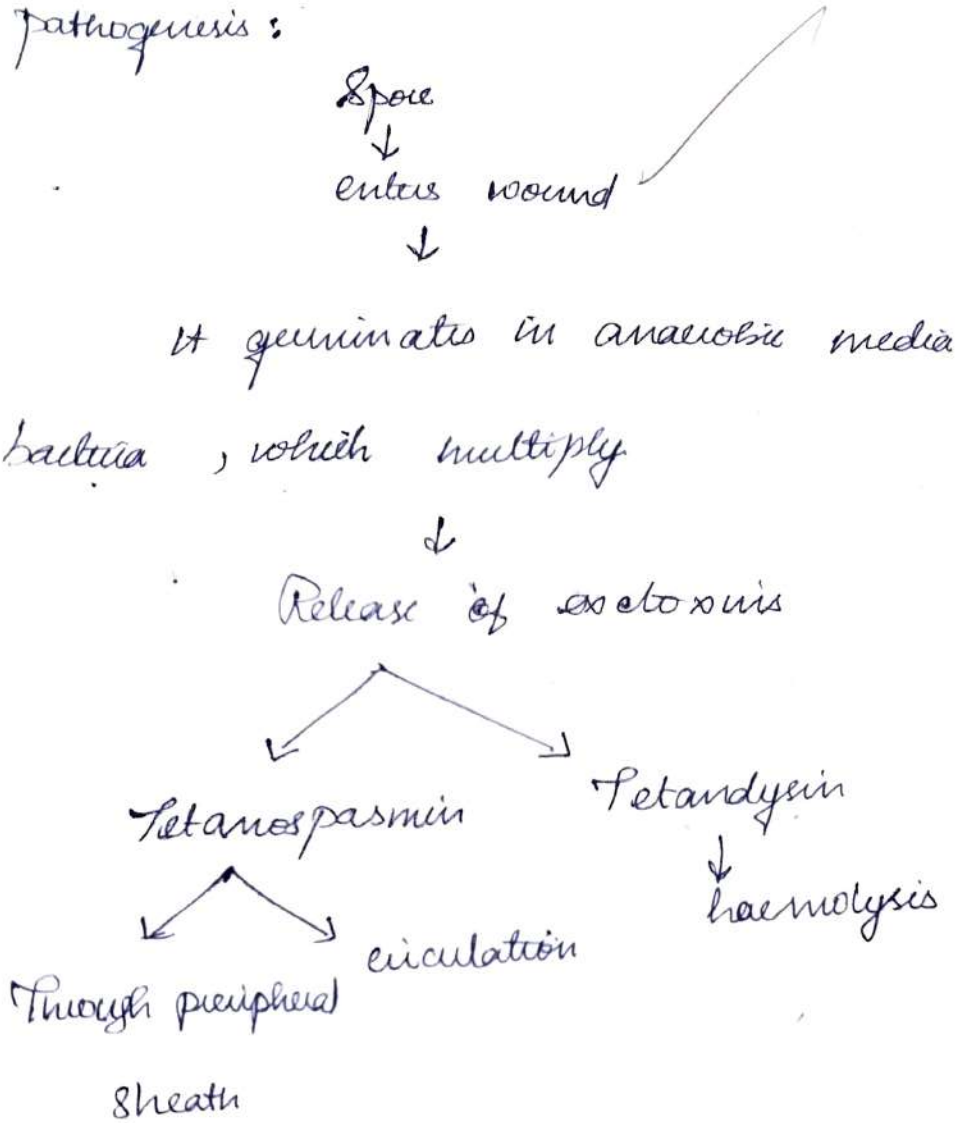

Clinical features :

Symptoms : Jaw stiffness
Anxiousness
Dysphagia
Dyspnoea

Tonicus

Risus sardonicus

Neck rigidity

Types

Early tetanus

Lacked tetanus

Ascending tetanus

Descending tetanus

Cephalic tetanus

Different posture in tetanus

Opisthotonus

Orthotonus

Emprosthotonus

pleurosthotonos

Complications

=> Fractured bone

=> haematoma

=> Carditis

=> Toxaemia

Treatment:

Antitetanus globulin - 3000 Units IM singledose

Anti tetanus serum - 1000 units

-1/2 IM) 1/2 IV

SRI VENKATESWARA DENTAL COLLEGE & HOSPITAL
DEPARTMENT OF ORAL & MAXILLOFACIAL SURGERY
THALAMBUR, CHENNAI - 103

ventilator support.

5) Cystic hygroma

Also known as Cavernous lymphangioma

It is a cystic swelling due to sequestration of portion of jugular lymph sac from lymphatic system during developmental period.

Present at birth as sternocleidomastoid muscle of neck

Site: posterior triangle of neck

cheek
Axilla
Tongue
Groin

Pathology: Aggregation of cysts like soap bubbles

Clinical features:

Swelling is smooth, fluctuant, soft

Swelling rapidly increases in size

Treatment:

⇒ Aspiration of contents

⇒ Respiratory obstruction - aspiration and tracheostomy.

SRI VENKATESWARA DENTAL COLLEGE & HOSPITAL
DEPARTMENT OF ORAL
...IAL
SURGERY
THALAMBUR, CHENNAI - 103

6) Ludwig's angina:

Ludwig's angina refers to cellulitis of Submental and Submandibular regions combined with inflammatory oedema of the mouth. Virulent streptococcal organisms are responsible for infection surrounding Submandibular region. Anaerobes also play a Major role.

Clinical features:

Elderly patient who presents with diffuse swelling in the submandibular and Sub-mental region

Oedema of the floor of the mouth as a result of which tongue is pushed upwards resulting in difficulty in swallowing

High grade fever with toxicity

Putrid halitosis is characteristic of this condit

Treatment:

Rest and hospitalisation

Appropriate antibiotics
Intravenous fluids to correct the dehydration and Ryle's tube feeding

It does not respond to conservative treatment Surgical intervention is recommended.

Surgery:

Under general anaesthesia 5-6 cm curved incision is made below mandible in submandibular region over the most prominent part of swelling.
Submandibular gland is mobilised, myelohyoid muscle is divided and pus is drained. Even if pus not found the oedematous fluid comes out greatly improving the cond. of patient. Wound is closed with loose sutures. antiseptic agent and drainage tube is placed.

Complications:

① Mediastinitis and Septicaemia

② Odema of the glottis due to spread of cellulitis via a tunnel occupied by stylohyoid to submucosa of glottis

7. Warthins tumour:

=> It is called as Adenolymphoma

=> It is a benign tumor that occurs only in parotid

=> It is composed of double layer of columnar epithelium, with papillary projections into cystic spaces.

Clinical features:

=> Slow growing

=> Smooth soft

=> Fluctuant swelling

=> Non tender

=> Common in males

=> 6th & 7th years

=> often Bilateral

Investigations

Produces a hot spot in technitium pertechnetate Scan

FNAC

Treatment

Superficial parotidectomy.

8) Tracheostomy:

Types: Emergency tracheostomy
Elective tracheostomy

Tracheostomy tube:

- Fullus bilateral tracheostomy tube
- Jacksons tracheostomy tube

Indications

In head, neck, facial injection

Tetanus

Tracheomalcia

Laryngeal oedema

Technique:

Neck of patient is hyperextended by placing sand bags under the shoulder

Vertical or horizontal incision is made

Deep fascia is opened

Strap muscle are retracted laterally

2nd and 3rd tracheal ring are opened and cruciform opening is made

Tube is placed. tied around neck

SRI VENKATESWARA DENTAL COLLEGE
DEPARTMENT OF ORAL
THALAMBUR CHENNAI - 103

Lymphoma

Definition:

This is a malignant neoplasm of lymph reticular system. Thus it can involve the lymph nodes, spleen, liver etc.

Pathology:

Disease starts usually in one of the lymph nodes as a painless swelling.

It involves supraclavicular region. The nodes are enlarged without matting.

The axial lymphatic system is almost always affected in hodgkin's disease

Classification:

① Lymphocyte predominance nodular

② Classic hodgkin's lymphoma

- Nodular Sclerosis
- Lymphocyte rich
- Lymphocyte depletion

clinical features

① Age: Bimodal distribution, In children and middle age

② Sex: Increased incidence is found in males.

Lymph node > 2 cm in size

Node is hard in consistency

palpable lft Supraclavicular

para-aortic nodes

Intermittent fever

Multiple bony pains

Superior vena caval obstruction

Investigation

① complete blood picture

② Elevated creatinine and blood urea nitrogen

③ chest X-ray

④ Abdominal USG

⑤ CECT Scan

⑥ lymph node biopsy

Treatment

Dose of radiotherapy : 3500 - 4500 Centigray.

Local regional radiotherapy :- when confined to one group of lymph nodes

Mantle field of therapy both side of neck nodes involved.

Carbuncle.

Carbuncle is an infective gangrene of Subcutaneous tissue caused by staphylococcus aureus It commonly occurs in diabetic patient also develop carbuncle

Site: Nape of neck commonest place followed by back and shoulder

Pathology:

Initial lesion is similar to a boil in form of hair follicle infection perifolliculitis.

Since majority of patient are diabetes infection takes a virulent course and results necrosis of Subcutaneous fat.

These abscesses are inter communicating and they open to exterior by multiple opening which are called sieve like openings

Clinical features.

Typically the patient is diabetes

Severe pain and the swelling in naps of neck.

Surface is red angry looking like a cod hot coal

complications :

Worsening of diabetic status resulting in diabetic ketoacidosis

Spectaemia , toxaemia

Treatment :

Deabetes ~~is~~ control insulin

parenteral antibiotics

curbate incision

poractically it amounts to excision of carbuncle

SRI VENKATESWARA DENTAL COLLEGE & HOSPITAL
DEPARTMENT OF ORAL & MAXILLOFACIAL SURGERY
THALAMBUR, CHENNAI - 130

36/10

I. Elaborate on :

1. Levels of cervical lymph nodes

Level I :

I_a ⇒ Submental lymph nodes

I_b ⇒ Submandibular lymph nodes

Level II : Lymph nodes in upper deep cervical region

II_a ⇒ Below and in front of the line of the spinal accessory nerve in the upper part

II_b ⇒ Above and posterior to line of spinal accessory nerve.

Level III : Lymph nodes in middle cervical region

Level IV : Lymph nodes in lower cervical region

Level V : Lymph nodes in the posterior triangle including supraclavicular region

V_a ⇒ Above the line of spinal accessory nerve

V_b ⇒ Below the level of spinal accessory nerve.

Level VI : Lymph nodes in the midline neck

Level VII : Lymph nodes in mediastenum

Drainage area of Lymph Node :

Level Ia lymph node :

Floor of mouth, anterior oral tongue, anterior mandibular alveolar ridge, lower lip

Level Ib Lymph Node :

Oral cavity anterior nasal cavity, soft tissue of midface, submandibular gland.

Level IIa and IIb Lymph Nodes

Oral cavity, nasal cavity, oropharynx, nasopharynx, hypopharynx, larynx, parotid gland

Level III lymph node

Oral cavity, oropharynx, nasopharynx, hypopharynx, larynx.

Level IV lymph node

Scalp, parotid gland, nasopharynx, thyroid gland etc

Level V lymph nodes

Scalp, parotid gland, nasopharynx, thyroid gland

Level VI lymph node

Thyroid gland, glottis and subglottis larynx, apex of pyriform sinus, cervical esophagus

2. Shock:

Shock is defined as an acute clinical syndrome characterized by hypoperfusion and severe dysfunction of vital organs.

Pathophysiology of neurogenic shock:

Decreased effective circulatory blood volume

↓

Decreased cardiac output

↓

Decreased blood flow

↓

Decreased supply of oxygen

↓

Anoxia

↓

Neurogenic shock

⇒ It occurs due to spinal cord injury which leads to dilatation of splanchnic vessels

⇒ There will be bradycardia, hypotension, arrhythmia and decreased cardiac output

Clinical features:

* History of emotional stress
* Bradycardia
* Tachypnea
* Fainting

Treatment:

* Control blood pressure using vasoconstrictors
* Oxygen administration
* Hemodynamics should be maintained
* Airway are cleared
* Fluid therapy should be given
* Intravenous methylprednisolone therapy is done
* Dopamine and phenylephrine can be used.

II. Short Note:

1. Trismus:

* It is generally known as lock jaw
* Generally caused due to spasm of muscles of mastication
* Patients have the inability to open the mouth

→ Normal mouth opening ⇒ 4cm or 40mm

⇒ Based on this measurement, trismus can be graded as

* Mild : >30 mm
* Moderate : 15 - 30 mm
* Severe : <15 mm

Causes:

* Spasm of muscles
* Infection
* Trauma
* TMJ disorder
* Tumors
* Congenital
* Hypocalcimia

Treatment:

* Heat therapy
* Analgesics
* Anti inflammatory drugs
* Physiotherapy.

2. Antibiotic prophylaxis for Infective Endocarditis:

* Patient with valvular and congenital heart disease who are at high risk of endocarditis should receive prophylatic antibiotic before undergoing any procedure.

* Cardiac lesions for which antibiotics prophylaxis is recommended before dental procedures are

→ Previous episodes of endocarditis
→ Patients with prosthetic heart valves
→ Cyanotic congenital heart diseases

Drug	Dose	Route	Timing
Standard regimen Amoxicillin	2gm	oral	1hr before procedure
Penicillin allergy Azithromycin	500mg	oral	1hr before procedure
Cephalexin	2g	oral	
Clindamycin	600mg	oral.	
Ampicillin	2g	IV	1hr before procedure

3. Biopsy:

The process of obtaining tissue for the diagnosis is called biopsy.

There are various types of biopsies

1. Fine needle aspiration cytology / biopsy (FNAC / FNA
   * Cells are identified here. hence the name
   * A fine needle of 23 or 24 gauge is used
   * Without removing, it is passed 3- 4 times within lesion in different direction

... alcohol made and are dipp...
Eg: Thyroid swelling, breast, parotid swelling solution

2) True cut biopsy / core needle biopsy
* Yeilds sufficient tissue to achieve diagnosis
* After giving LA, 1-2 ml of a small skin nick is made

3) Punch biopsy
* Long instrument called punch biopsy forcep are used
* Done is cauliflower like lesions or exophytic lesions

4) Wedge biopsy
* Done in malgenant ulcer suspect
* Edge is selected as it rapidly grows.

5) Incision biopsy
When lyphoma or tuberculosis with matted nodes is suspected.

6) Full thickness excision biopsy.
Suspected recommended and done for suspected malignant melanoma.

4. Tetanus:

It is an infective condition caused by clostridium tetani leading to reflex muscle spasm

Pathogenesis:

Spore
↓
Enter wound
↓
Releasing bacteria
↓
Release exotoxins

Clinical Features.

Symptoms.

* Jaw stiffness
* Anxiousness
* Headache
* Dysphagia
* Dysphonia

Signs:

* Trismus
* Risus sardonicus
* Neck rigidity

Types:

- Early tetanus
- Latent tetanus
- Ascending tetanus
- Descending tetanus
- Cephalic tetanus

Different posture in tetanus:

* Opisthotonus
* Orthotonus
* Emprosthotonus
* Pleurothotonus

Complication:

* Fractured bone
* Aneurysm
* Cardiac
* Toxaemia

Treatment:

* Anti tetanus globulin - 5000 units IM single dose
* Anti tetanus serum - 1000 units
  1/2 IM, 1/2 IM.
* Ventilator support.

SRI VENKATESWARA DENTAL COLLEGE & HOSPITAL
DEPARTMENT OF ORAL

5. Cystic hygroma :

* It is also called cavernous lymphangioma
* It is a cystic swelling due to sequestration of a portion of jugular lymph sac from lymphatic system during developmental period in utero.
* Present at birth and may cause obstructed labour.
* Also called as hydrocele of neck

Sites:

Posterior triangle of neck
Cheek
Tongue
Groin

Pathology:

Aggregation of cystic like soap bubbles

Clinical Features:

* Swelling is smooth, fluctuant, soft
* Swells rapidly

Treatment:

* It is done by aspiration of contents
* Respiratory obstruction — aspiration + tracheostomy.

6. Ludwig's angina:

* It is an inflammatory edema of submandibular region and floor of mouth, recommended commonly due to streptococcal infection
* Causes diffuse swelling + brawny edema of submandibular region
* It is common in poorly ill and in advanced malignancy causing trismus

SRI VENKATESWARA DENTAL COLLEGE & HOSPITAL
DEPARTMENT OF ORAL & MAXILLOFACIAL SURGERY
THALAMBUR, CHENNAI - 103

Precipitating factors:
* Caries dentis
* Oral malignancy
* Sub mandibular salivary infection
* Chemotherapy

Clinical features:
* Fever
* Toxicity
* Trismus
* Intraoral edema
* Putrid halitosis

Treatment: * Antibiotics
IV fluids

4. Warthin's tumor.
* It is called as adenolymphoma
* It is benign tumor that occurs only in parotid
* It is composed of double layer of columnal epithelium, with papillary projection into cystic spaces

Clinical features:
⇒ Slow growing
⇒ Smooth, soft
⇒ Fluctuant swelling
⇒ Non tender
⇒ Common in males
⇒ Age: 60 years
⇒ Often bilateral

Investigation:
* Produces a hot spot in technitium pertechnetate scan
* FNAC

Treatment:

Superficial parotidectomy

8. Tracheostomy:

It is a procedure that is done to aid the breathing.

Types:

* Emergency tracheostomy
* Elective tracheostomy

Tracheostomy tube.

* Fuller bivalved tracheostomy tube
* Jacksons tracheostomy tube

Indications:

* In head, neck, facial injuries
* Tetanus
* Tracheomalcia
* Laryngeal edema.

Techniques:

* Neck of patient is hyperextended by placing sand bags under the shoulder.
* Vertical or horizontal incision is made
* Deep fascia is opened
* Strap muscles are retracted laterally
* 2nd & 3rd tracheal ring are opened and circular opening is made
* Tube is placed, tied around neck.

Post operative care:

* Supervision for bleeding, breathing difficulty due to displacement of tube.
* Suctioning, deflate cuff every hour for 5min

Complication:

* Early - bleeding, injury to esophagus.
* Intermediate - secondary infection
* Late - tracheal stenosis

Lymphoma:

* Cancer of the lymphatic system
* It is lymphatic system body's disease - fighting network
* The main types of lymphoma are Hodkin's lymphoma and non-Hodkin's lymphoma.

Classification

Hodgkin's Lymphoma:

(i) lymphocyte predominance nodular both - Hodgkin's lymphoma and low grade B cell lymphoma

(ii) Classic Hodgkin's lymphoma (HL)

* Nodular sclerosis
* Lymphocyte depletion
* Lymphocyte rich
* Mixed cellularity

Non-Hodgkin's lymphoma (NHL)

(i) Low grade:

* Small lymphocytic
* Follicular - predominantly small cleaved cell

(ii) Intermediate grade:

* Follicular
* Diffuse small cleaved cell
* Diffuse mixed
* Diffuse large cell

(iii) High grade:

* Large cell immunoblastic
* Lymphoblastic
* Burkitt's or non-Burkitt's lymphoma

(iv) B cell NHL

(v) T cell NHL

10. Carbuncle:

* It is an infective gangrene.
* Commonly in diabetic patients, common organism staph

Pathology:

Initial lesion is similar to boil with hair follicle with perifolliculitis

↓

Necrosis of subcutaneous fat with multiple abscesses

↓

Later communicating abscess open to exterior by multiple opening

↓

Carbuncle

Clinical features:

Site: Nape of the neck, back & shoulder region

Signs & symptoms:

* Severe pain, swelling, fever with chills & rigors
* Surface red, angry looking like a red hot coal.
* Surrounded area indurated
* Later, soften & peripheral satellite vesicles appear, rupture discharging pus like cribriform appearance.
* Development of large cheesy form ulcer with central slough.

Complication:

* Diabetic ketoacidosis
* Acute infective gangrene

Treatment:

* Diabetic control
* Left open, saline dressing to reduce edema, complete resolution within 10-15 days
* Surgery required when there is pus
* Cruciate incision, skin flap.

Saran B

SRI VENKATESWARA DENTAL COLLEGE & HOSPITAL
DEPARTMENT OF ORAL & MAXILLOFACIAL SURGERY
IHALAMBUR, CHENNAI - 127

Essay:

1) Levels of Cervical lymph Nodes. Describe lymphatic drainage of Head and Neck.

48/10 Ly

a) Levels of cervical lymph Nodes.

Level I: Submental (Ia) and Submandibular (I b) lymph Nodes.

Level II: lymph nodes in upper deep cervical region. It extends from base of skull to hyoid bone and from lateral margin of Sternohyoid to posterior margin of Sternomastoid muscle. Level II a is below and it front of the line of the Spinal accesory nerve in the upper part and Level II b is above & posterior to line of Spinal accessory Nerve.

Level III: lymph nodes in middle cervical region.

Level IV:- lymph nodes in lower cervical region i.e. from omohyoid muscle / cricothyroid membrane to Clavicle.

Level V:- lymph nodes in posterior triangle including

Supraclavicular region from posterior border of sternocleidomastoid muscle to anterior border of trapezius muscle.

Level VI : Lymph Nodes in the midline neck - pretracheal and prelaryngeal from hyoid bone above to suprasternal notch below medial border of carotid sheath on either side.

Level VII : Lymph nodes in the mediastinum inferior to suprasternal notch to innominate artery below.

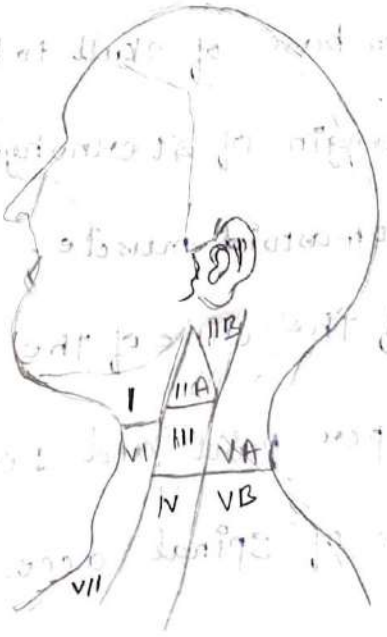

area

Drainage of Lymph Nodes.

→ Level Ia lymph nodes - floor of mouth, anterior oral tongue anterior mandibular alveolar ridge, lower lip

→ Level Ib lymph nodes - Oral cavity, anterior nasal

DEPARTMENT OF ORAL & MAXILLOFACIAL SURGERY
SRI RAMACHANDRA HOSPITAL
PORUR CHENNAI - 116

cavity, soft tissue of midface, submandibular gland.

→ Level II a & II b lymph Nodes - Oral cavity, nasal cavity oropharynx, nasopharynx, parotid gland.

→ Level III lymph nodes - oral cavity, oropharynx, larynx.

→ Level IV lymph nodes - Hypopharynx, thyroid, cervical esophagus.

→ Level V lymph nodes - Scalp, parotid gland, thyroid gland etc.

→ Level VI lymph nodes - Thyroid gland, glottis and subglottis, larynx, apex of pyriform sinus.

---

2) Define shock. Neurogenic shock.

Shock is defined as an acute clinical syndrome characterised by hypoperfusion and severe dysfunction of vital organs. There is a failure of the circulatory system to supply blood in sufficient quantities or under sufficient pressure necessary for the optimal function of organs vital to survival.

Pathophysiology of Neurogenic shock.

Disruption of Sympathetic Nervous System

↓

Loss of Sympathetic tone. → parasympathetic Nervous System response.

↓

Venous and arterial Vasodilation

↓

↓ BP.

↓

↓ Venous return.

↓

↓ Stroke volume.

↓

↓ Cardiac output. ← ↓ Heartrate

↓

↓ cellular oxygen supply

↓

↓ tissue perfusion

↓

Impaired cellular metabolism.

Causes:

* High spinal cord injury.
* Vagolytic shock.

Features of Neurogenic shock.

* Hypotension without tachycardia, may deteriorate to produce shock and cardiac arrest.

Management:

* Intravenous fluids.
* Inotropes
* Vagolytics

→ IV fluids-

IV fluids are the primary treatment for low blood pressure. They replenish fluid levels in the veins to help stabilize blood pressure.

→ Vasopressors:

If IV fluids prove ineffective. Vasopressors can help tighten blood vessels and increase blood pressure commonly used Vasopressors include norepinephrine, phenylephrine, dopamine, epinephrine.

→ Atropine: If your heart rate is low, doctor may prescribe atropine. It helps normalize heart rate by inhibiting parasympathetic activity.

Symptoms of Neurogenic shock.

* dizziness
* Nausea
* Vomiting
* Blank stares
* fainting
* Increased sweating
* anxiety
* pale skin
* difficulty in breathing
* Chest pain
* Faint pulse
* Cyanosis
* Hypothermia

SRI VENKATESH ... DEPARTMENT ... ACIAL ... GERY ... THAI ... NAI - 102

II. Short Notes.

1) Trismus.

* Difficulty in opening the mouth is called trismus.

Normal mouth opening ranges from 35 to 45 mm.

Grades.

i) Grade I: Mouth opening is between 2.5 and 4 cm.

ii) Grade II : Between 1 and 2.5 cm.

iii) Grade III : Less than 1 cm.

Common causes of trismus.

3

* Temporomandibular joint involvement such as ankylosis, dislocation, synovitis etc.

* Mandible fractures

* pterygoid muscle infiltration by growth in the retromolar region.

* Acute inflammatory lesions in the Oral cavity.

* Tetanus.

* Tetany

* Radiation fibrosis of soft tissues / muscles of mastication.

Dental procedure for which endocarditis prophylaxis is advised in patients at high or moderate risk for endocarditis

* Extractions.
* periodontal procedures, cleaning causing gingival bleeding.
* Implant placement, reimplantation of avulsed teeth.
* Endodontic instrumentation (or) surgery beyond the apex.
* Subgingival placement of antibiotic fibers or strips.
* placement of orthodontic bands but not brackets

3) Biopsy.

Every part of the body tissue which is removed should be subjected for histopathological diagnosis except nail and hair.

Types of Biopsies.

* Fine Needle aspiration cytology.
* Tru-cut biopsy.
* punch biopsy.

* Wedge biopsy from edge of the ulcer/growth.

* Incision biopsy.

* Full thickness excision biopsy.

i) Fine Needle aspiration cytology.

* In this biopsy cells are identified.

* Fine Needle of 23 (or) 24 gauze is introduced into the tumour or swelling.

* Without removing the needle out of skin Over the lump, 3 or 4 times it is passed within the lesion in different directions.

Advantages.

→ It is safe

→ simple

→ cost effective.

ii) Tru-cut biopsy.

* Immunohistochemistry plays a major role in the diagnosis and thus management of these patients

* After giving local anaesthetic such as lignocaine a small skin nick is made. The Needle is introduced into the lump and several passes can be done to Obtain sufficient tissue.

SRI VENKATESWARA DENTAL HOSPITAL
DEPARTMENT OF ORAL & FACIAL SURGERY
THALAMBUR, CHENNAI - 103

* It is useful investigation of choice in soft tissue sarcoma, carcinoma breast, lymph node metastasis

iii) Punch biopsy:

* By using a long instrument called punch biopsy forceps punch of tissue is removed by closing the blades of instrument
* This is done in proliferative like lesions.

iv) Wedge biopsy:

* Typically done when you suspect malignant ulcers such as epithelioma, malignancy developing in chronic ulcer/ scar tissues.

v) Incision biopsy:

* Typically done in lymphoma or tuberculosis with matted nodes, incision is made over the swelling after giving local anaesthetic agent and the lymph node is dissected all around and 1 lymph node is removed.

vi) Full thickness excision biopsy:

This is strongly recommended and done for suspected malignant melanoma.

4) Tetanus.

* Tetanus is a serious disorder with very high mortality even with treatment.

* The disease is caused by Clostridium tetani, an anaerobic spore - forming bacillus with terminal spore which has a drumstick like appearance.

Possible routes of infection are.

* Umbilical cord.

* Wound

* Minor injuries

* Septic abortion (or) surgical operations.

* Tetanospasmin has affinity towards nervous tissues.

* The toxin which is fixed to the nervous tissue cannot be Neutralised.

Special types of tetanus.

* Tetanus neonatorum:-

It occurs due to contamination of

SRI VENKATESWARA DENTAL COLLEGE & H
DEPARTMENT OF ORAL & MAXILLOFACIAL SURGERY
THALAMBUR, CHENNAI - 103

umbilical cord in children born to non-immunised mothers. It manifests usually around 6-8 days of birth and is called as Eighth day disease.

* Local Tetanus:

Contraction of muscles occurs in the neighbourhood of the wound.

* Cephalic tetanus:

usually occurs after wound of head and face. Oculomotor Nerve can get paralysed.

* Bulbar tetanus:

It is a condition wherein muscles of deglutition and respiration are involved.

* Latent tetanus:

It develops after few months to years following a wound which might have been forgotten.

* Puerperal tetanus:

It occurs as a complication of abortion (or) puerperal sepsis.

* postoperative tetanus.

Occurs due to improper sterilisation of instruments and carries 100% mortality.

* Otitis tetanus:

It is due to chronic suppurative otitis media.

CLINICAL FEATURES.

→ Autonomic dysfunction:-

Increased basal sympathetic tone manifesting as tachycardia and bladder, bowel dysfunction; labile hypertension, pyrexia, pallor, sweating and cyanosis of digits can occur.

Treatment

i) General management
ii) Specific management.

* General Management.

→ Admission and isolation
→ Wound care.
→ Injection - Tetanus toxid 0.5 ml to be given IM.
→ Antitetanus serum.
→ Instead ATS, human antitetanus globulin.

SRI VENKATESWARA DENTAL COLLEGE & HOSPITAL
DEPARTMENT OF ORAL & MAXILLOFACIAL SURGERY
THALAMBUR, CHENNAI - 103

→ Injection crystalline penicillin.

→ Metronidazole

Specific Management

a) Mild cases.

Drug	Dosage	Time
Chlorpromazine	50 - 100 mg	8 am - 2pm - 8 pm - 2am.
Phenobarbitone	30 - 60 mg	10 am - 4 pm - 10 pm - 4am.
Diazepam	10 - 20 mg	12 noon - 6 pm - 12 MN - 6 am.

B) Seriously III cases.

* They have dysphagia and reflex spasms.
* A nasogastric tube is introduced for feeding purposes and to administer the drugs.
* Tracheostomy if breathing difficulty arises.

c) Dangerously III cases.

* This group includes patients with major cyanotic convulsions.
* In addition to continuing sedatives these patients are paralysed with muscle relaxants and positive

pressure ventilation is given till they recover.

5) cystic hydroma

* Also called as cavernous lymphangioma.
* cystic swelling due to sequestration of a portion of jugular lymph sac from lymphatic system during developmental period in utero.
* present at birth & may cause obstructed labour.
* Also called as hydrocele of Neck.

Sites: → posterior triangle of Neck
→ Cheek
→ Axilla
→ tongue
→ Groin.

Pathology - Aggregation of cyst like soap bubbles.

clinical feature:-
→ Swelling is smooth, fluctuant, soft
→ Swelling rapidly increases in size.

Treatment
→ Aspiration of contents
→ Respiratory obstruction - aspiration & tracheostomy.

SRI VENKATESWARA DENTAL COLLEGE & HOSPITAL
DEPARTMENT OF ORAL & MAXILLOFACIAL SURGERY
THALAMBUR, CHENNAI - 103

b) Ludwig's Angina.

* It refers to cellulitis of submental and Submandibular regions combined with inflammatory oedema of the mouth. Virulent streptococcal Organisms are responsible for Ludwig's Angina.

Clinical features.

* Elderly patient who presents with diffuse swelling in the submandibular and submental region (Brawny oedema)

* Oedema of the floor of the mouth, as a result of which tongue is pushed upwards resulting in difficulty in swallowing.

* High grade fever with toxicity.

Treatment:

* Rest and hospitalisation.

* Appropriate antibiotics.

* Intravenous fluids to correct the dehydration and Ryle's tube feeding.

Surgery:

* Under general anaesthesia 5-6 cm curved incision is made below the mandible in the submandibular region over the most prominent part of the swelling.

7) Warthin's Tumour

* Warthin's Tumour is also called Adenolymphoma.

* Adenolymphoma is not a lymphoma. It is a misnomer

* It is a benign parotid tumour and Next common to pleomorphic adenoma. It constitudes about 10% of parotid tumours.

* Origin of adenolymphoma :- During development some parotid tissue gets included within lymph nodes which are present within parotid sheath.

Histology:

* composed of double layered eosinophillic epithelium Inner cells are columnar.

* presence of lymphatic tissue in stroma and lymph follicles is feature of adenolymphoma.

SRI VENKATESWARA DENTAL COLLEGE & HOSPITAL
DEPARTMENT OF ORAL & MAXILLOFACIAL SURGERY
THALAMBUR, CHENNAI - 103

Clinical feature.

* Middle aged (or) elderly males are commonly affected.
* Can be bilateral
* It has smooth surface, round border with soft, cystic consistency.
* Situated at the lower pole of parotid elevating the ear lobule.
* May be multicentric.

Treatment:

It has got a well-defined capsule. enucleation can be done.

---

8) Trachcostomy.

Making an opening in anterior wall of trachea and converting it into a stoma on skin surface.

Functions:

* Respiration through alternative pathway in case of obstruction above the stroma.
* Alveolar ventilation is improved due to reduction in dead space by 30-50% and reducing the

resistance to airflow.

* protection of airway by way of cuffed tracheostomy.

* Tracheobronchial toilet

* Intermittent positive pressure respiration if required >72 hours then a tracheostomy is preferred over endotracheal intubation.

Indications.

i) Respiratory obstruction.

* Infections - Ludwig's angina.

* Trauma to larynx.

* Tumour

* Foreign body

ii) Retained secretions.

* Comatose patient

* painful cough - trauma to chest.

* Aspiration of pharyngeal secretion.

iii) Respiratory insufficiency:

Due to chronic lung conditions like emphysema, chronic bronchitis

Types:-

Emergency, elective (or) permanent

Technique.

* If possible patient is intubated prior to surgery.
* Position - Supine with Neck extended under local anaesthesia.

Procedure:

* Incision can be Vertical (or) transverse.
* Veins on the surface retracted, thyroid gland is retracted upwards with blunt hook.
* Trachea exposed.
* 1% Xylocaine is infiltrated into trachea.
* In children a vertical 'H' incision is made without removing cartilage.

Complication of Tracheostomy.

(1) Early.

→ Bleeding
→ Injury to Oesophagus.
→ Injury to Recurrent laryngeal Nerve.

(2) Intermediate

→ Secondary infection of Wound.
→ Blockage of tube.

(3) Late

→ Tracheal stenosis.

9) Lymphoma

This is a malignant neoplasm of lymphoreticular system. Thus it can involve the lymph nodes, spleen, liver etc.

Pathology

* Disease starts usually in one of the lymph nodes as a painless swelling.
* Involves left supraclavicular region. The Nodes are enlarged without matting. It spreads to other nodes in a downstream lymphatic drainage.
* The axial lymphatic system is almost always affected in Hodgkin's disease.

CLINICAL FEATURES

* Age - Bimodal distribution.
* Sex - Increased incidence is found in males.
* It presents as generalised lymphadenopathy.
* Abdominal pain can occur due to hepatosplenomegaly.
* There may be Ascites.
* Intermittent fever.
* Multiple bony pains
* Superior vena caval obstruction.

Investigations

i) **Complete blood picture:** peripheral smear to rule out leukemia.

ii) **Elevated creatinine & blood urea nitrogen**

Indicates ureteral obstruction due to the direct involvement of kidneys.

iii) **Chest X-ray:**

is taken to rule out mediastinal lymph Nodes.

iv) **Abdominal USG**

→ to look for para-aortic nodes

→ to look for splenomegaly.

→ to rule out secondaries in liver.

v) **CECT Scan:-**

It is done for look enlarged para-aortic and iliac lymphnodes, mesenteric lymph nodes, hepatosplenomegaly

vi) **Mediastinoscopy.**

is done if peripheral nodes are not available.

Treatment

* Dose of radiotherapy: 3500-4500 centigray (cGy) units

* Local regional radiotherapy.

* Mantle field of therapy.

* Inverted Y field radiotherapy.

10) Carbuncle.

This is an infective gangrene of the subcutaneous tissue caused by staphylococcus aureus.

Sites:- Nape of the Neck is the commonest site.

Pathology:

→ The initial lesion is similar to a boil in the form of hair follicle infection with perifolliculitis.

→ For diabetics, infections takes a virulent course and results in necrosis of subcutaneous fat which gives rise to multiple abscess.

→ This appearance is described as cribriform appearance which is pathognomonic of carbuncle.

clinical features

* typically patient is diabetic.

* Severe pain, swelling in the Nape of Neck.

* Symptoms like fever with chills and rigors are severe.

* Surface is red, angry looking like a red hot coal.

Complications.

* Worsening of the diabetic status resulting in diabetic ketoacidosis.

* Extensive necrosis of skin overlying carbuncle. Hence it is included under acute infective gangrene.

* Septicaemia, toxaemia.

Treatment

* Diabetes control preferably with injectable insulin

Parenteral antibiotics are given.

Staphylococcus aureus are sensitive to cloxacillin, flucloxillin, erythromycin, cephalosporins.

Surgery is required when there is pus. cruciate incision is preferred because of multiple abscess and extensive subcutaneous necrosis.

General Surgery

Sakthivel

SRINIVASA DENTAL COLLEGE & HOSPITAL
DEPARTMENT OF ORAL & FACIAL SURGERY
KALLAMBUR, CHENNAI - 103

Remedial Test

I.

1. Levels of cervical lymph node:

Level I : Submental and Submandibular lymph nodes

Level II : Lymph nodes in upper deep cervical region

Level III : Lymph nodes in middle cervical region

Level IV : Lymph nodes in lower cervical region

Level V : Lymph nodes in posterior triangle

Level VI : Lymph nodes in midline neck

Level VII : Lymph nodes in mediastinum.

Lymphatic Drainage of head and neck

⇒ It collect and transport tissue fluids from intercellular spaces in all tissues of body, back to the veins in the blood system

Components :

→ Lymph
→ Lymphatic vessels
→ Lymphatic tissue
→ Lymphatic organs

Lymphatic vessels :

Can be classified as :
→ Superficial vessels
→ Deep vessels

~~Lymphatic~~ /

Lymph Nodes :

→ Superficial lymph nodes

1. Occipital : Located at back of ~~neck~~ head at the lateral border of trapezius muscle and collect lymph from occipital area.

2. Mastoid : → Also called as post auricular lymph nodes.
→ Located posterior to ear and on the insertion of sternocleido-mastoid muscle into the mastoid process.

SRI VENKATESWARA DENTAL COLLEGE & HOSPITAL
DEPARTMENT OF ORAL & MAXILLOFACIAL SURGERY
THALAMBUR CHENNAI - 103

→ They collect lymph from posterior neck, upper ear

3. Parotid : → Located superficially to parotid gland.
→ They collect from nose, nasal cavity, tympanic cavity.

4. Submental : → Located superficially to mylohyoid muscle.
→ The collect from central lower lip, floor of mouth

5. Submandibular : → Located below mandible in submandibular triangle
→ Collect from cheeks, upper lip, anterior tongue.

6- Facial : → maxillary / infraorbital, buccinator and Supra mandibular lymph nodes.
→ They collect from mucous membranes of nose, cheek eyelids.

Deep lymph Nodes :

→ Recieve all lymph from head and neck either directly or indirectly via the superficial lymph nodes.

→ The nodes can be divided into superior and inferior deep cervical lymph nodes.

SRI VENKATESWARA DENTAL COLLEGE & HOSPITAL
DEPARTMENT OF ORAL & MAXILLOFACIAL SURGERY
THALAMBUR, CHENNAI - 103

2. Define Shock

Shock is defined as an acute clinical syndrome characterised by hypoperfusion and sweu dysfunction of vital organs.

Neurogenic Shock :

→ It occurs due to spinal cord injury which leads to dilatation of splanchnic vessels.

Pathophysiology :

Low Cardiac Output

↓

Vasoconstriction occurs as a compensation to perfuse vital organs like brain, heart, muscle, kidneys, liver.

↓

Because of vasoconstriction and tachycardia

↓

Dynamic circulation increases.

↓

Tachypnoea occurs to increase the O_2 saturation

↓

Peripheral veins constrict

↓

Decreased renal blood flow

↓

decreased urine output

↓

Causes salt and H_2O retention

↓

ADH is released

↓

Further concentration of urine occurs

↓

When shock persists cardiac output falls further.

↓

Hypotension and tachycardia.

↓

Hypoxia

↓

Release of cardiac depressants

↓

Cardiac failure

~~Tre~~

Management:

→ Antibiotics of high generation

eg: Ceftazidime

Amikacin

Cefoperazone

→ Dopamine
→ Ventilator support.

II.

1. Trismus

→ Trismus or 'lock jaw' is caused due to spasm of muscles of mastication.

→ Patients affected by trismus have an inability to open their mouth.

→ Normal mouth opening is about 4cm or 40mm.

→ Based on this measurement, trismus can be graded as:

* Mild : > 30mm
* Moderate : 15-30mm
* Severe : <15mm

Causes :

→ Spasm of muscles of mastication due to abnormality or disturbance in the trigeminal nerve.

→ Infection : This can be due to many reasons such as pulpal, periodontal origin ~~and due to~~ around the third molar.

→ Trauma : Fracture of bone of jaws

SRI VENKATESWARA DENTAL COLLEGE & HOSPITAL
DEPARTMENT OF ORAL & MAXILLOFACIAL SURGERY
THALAMBUR, CHENNAI - 103

→ TMJ disorders :

→ Tumours

→ Congenital

Treatment :

→ Heat therapy

→ Analgesics / Anti inflammatory drugs

→ Physiotherapy

2. Antibiotic prophylaxis for Infective Endocarditis

Drug	Dose	Route	Timing
Standard regimen Amoxicillin	2.0g	oral	1 hr before procedure
Penicillin allergy			
Azithromycin	500mg	oral	1 hr before procedure
Cephalexin	2g	oral	
Clindamycin	600mg	oral	
Ampicillin	2g	IV	1 hr before procedure

VENKATESWARA DENTAL COLLEGE & HOSPITAL
DEPARTMENT OF ORAL & MAXILLOFACIAL SURGERY
THALAMBUR, CHENNAI - 103

→ Patients with valvular and congenital heart disease who are at high risk of endocarditis should receive prophylactic antibiotics before undergoing any procedure.

→ Cardiac lesions for which antibiotic prophylaxis is recommended befor dental procedures are:
- Previous episode of endocarditis
- Patients with prosthestic heart valves
- Cyanotic congenital heart disease.

3. Biopsy

→ The process of obtaining tissue for the diagnosis is called biopsy.

→ There are various types of biopsies.

1) Fine needle aspiration cytology / biopsy (FNAC / FNAB)
- Cells are identified here. hence the name.
- A fine needle of 23 or 24 gauze is used. to introduce into tumour or swelling.
- without removing, it is passed 3-4 times within lesion in different direction.
- Cells are stuck into the needle or syringe.
- 3-4 smears are made and are dipped in 95% ethyl alcohol solution

- Eg: thyroid swellings, breast, parotid swell
  lymph nodal swelling

2) Tru Cut biopsy / core needle biopsy.
   - Yeilds sufficient tissue to achieve diagnosis
   - After giving LA, 1-2ml of a small skin nick is made.
   - Should not be done in thyroid swellings because thyroid is very vascular.

3) Punch biopsy:
   - Long instrument called punch biopsy forceps are used
   - Done in cauliflower like lesions or exophytic lesions.

4) Wedge biopsy:
   - Done in malignant ulcer suspect
   - Edge is selected as it rapidly grows thus hence maximum cancerous tissue is present.

5) Incision biopsy:
   - When lymphoma or tuberculosis with matted nodes is suspected.

6) Full thickness excision biopsy:
   - Suspected recommended and done for suspected malignant melanoma.

SRI VENKATESWARA DENTAL COLLEGE & HOSPITAL
DEPARTMENT OF ORAL & MAXILLOFACIAL SURGERY
THALAMBUR, CHENNAI-103

4. Tetanus

→ It is an infective condition caused by Clostridium Tetani leading to reflex muscle spasm.

Pathogenesis:

Spore
↓
enters wound
↓
It germinates in anaerobic media releasing bacteria, which multiply.
↓
Release of Exotoxins

- Tetanospasmin
  - Through peripheral sheath
  - Circulation
- Tetanolysin
  - ↓
  - Haemolysis

Clinical Features:

Symptoms: Jaw stiffness
Anxiousness.
Headache
Dysphagia
Dyspnoea

Signs: Trismus
Risus sardonicus
Neck rigidity

Tonic Clonic Convulsions
Hyperreflexia
Fever & tachycardia

Types : Early tetanus
Latent tetanus
Ascending tetanus
Descending tetanus
Cephalic tetanus

Different Postures in Tetanus :

→ opisthotonus
→ orthotonus
→ Emprosthotonus
→ Pleurosthotonus

Complications :

→ Fractured bone
→ Haematoma
→ Carditis
→ Toxaemia

Treatment :

→ Antitetanus globulin – 3000 units IM single dose
→ Antitetanus serum – 1000 units.
– ½ IM, ½ IV

SRIVENKATESWARA DENTAL COLLEGE & HOSPITAL
DEPARTMENT OF ORAL & MAXILLOFACIAL SURGERY
THALAMBUR, CHENNAI - 103

→ IV - diazepam 20mg - 6th hourly
IV phenobarbitone 30mg - 6th hourly
IV Chorpromazine 25mg - 6th hourly
→ Ventilator support

5. Cystic hygroma

→ Also called as Cavernous lymphangioma.
→ It is a cystic swelling due to sequestration of a portion of jugular lymph sac from lymphatic system during developmental period in utero.
→ Present at birth and may cause obstructed labour.
→ Also called as hydrocele of neck.

Sites: Posterior triangle of neck
Cheek
Axilla
Tongue
Groin

Pathology: Aggregation of cysts like soap bubbles.

Clinical Features:

→ Swelling is smooth, fluctuant, soft.

→ Swelling rapidly increases in size

Treatment :

→ Aspiration of contents.

→ Respiratory obstruction — aspiration and tracheostomy

6. Ludwigs angina

→ It is an inflammatory oedema of submandibular region and floor of mouth, commonly due to streptococcal infection

→ Causes diffuse swelling and brawy oedema of submandibular region.

→ It is common in severly ill and in advanced malignancy causing trismus.

Precipitating factors :

→ Caries tooth
→ Oral malignancy
→ Submandibular salivary infection
→ Chemotherapy

Clinical features

→ Fever
→ Toxicity
→ Trismus
→ Intra oral oedema
→ Putrid halitosis

Treatment : Antibiotics
IV fluids

DEPARTMENT OF ORAL & FACIAL SURGERY
THALAMBUR, CHENNAI - 103

7. Warthins tumor

→ It is called as Adenolymphoma
→ It is a benign tumour that occurs only in parotid.
→ It is composed of double layer of columnar epithelium, with papillary projections into cystic spaces.

Clinical Features :

→ Slow growing
→ Smooth, soft
→ Fluctuant swelling
→ Non tender
→ Common in males
→ Age : 60 years
→ Often bilateral.

Investigations :

→ Produces a hot spot in Technitium pertechnetate scan.
→ FNAC

Treatment :- Superficial parotidectomy

8- Tracheostomy

Types : Emergency tracheostomy
Elective tracheostomy

Tracheostomy tube :

→ Fullu biralved tracheostomy tube
→ Jacksons tracheostomy tube

Indications :

→ In head, neck, facial injuris
→ Tetanus
→ Tracheomalcia
→ laryngeal oedema

Technique :

→ neck of patient is hyperextended by placing sand bags under the shoulder.
→ vertical or horizontal incision is made.
→ Deep fascia is opened
→ Strap muscle are retracted laterally
→ 2nd and 3rd tracheal ring are opened and circular opening is made
→ Tube is placed. tied around neck.

SRI VENKATESWARA DENTAL COLLEGE & HOSPITAL
DEPARTMENT OF ORAL & MAXILLOFACIAL SURGERY
THALAMBUR CHENNAI - 103

9. Lymphoma

They are progressive neoplastic condition of lympho reticular system arising from stem cells.

Etiology :

→ Genetic
→ Sjogrens syndrome
→ HIV
→ Epstein bar virus

Types :

- Hodgkins lymphoma
- Non Hodgkins lymphoma.

Hodgkins lymphoma :

Clinical Features :

→ Sex - male predominance.
→ Age - 20-30 and >50 years.
→ Site - cervical lymph nodes
Axillary, mediastinal, abdomen.
→ Painless.
→ Smooth, firm, nontender, India rubber consistency

Investigations :

→ Blood – Hb%, ESR, peripheal smear.
→ FNAC
→ Biopsy
→ Chest x-ray, CT

Treatment :

→ Early favourable stage – extended field radiation
→ Early unfavourable stage – extended radiation plus chemotherapy
→ Advanced stage – chemotherapy + local radiation
→ Drugs : Mustine
Oncovine
Procarbazine
Prednisolone.

Non Hodgkins Lymphoma :

Clinical Features :

→ Age : 30 and above
→ Sex : No sex predilection
→ Site : Innumaldeyer ring, epitrochlear lymph nodes
→ Spleen is not commonly involved
→ Hepatomegaly is common

SRI VENKATESWARA DENTAL COLLEGE & HOSPITAL
DEPARTMENT OF ORAL & MAXILLOFACIAL SURGERY
THALAMBUR, CHENNAI - 103

Treatment :

→ Chemotherapy

- CHOPP – Chlorambucil, Oncorin, Procarbazine Prednisalone.

10. Carbuncle.

→ Infectious gangrene of skin and subcutaneous tissue

Etiopathogenesis :

Infection
↓
Development of small vesicles
↓
Sieve like pattern
↓
Red induration with discharge pus
↓
Many fuse together – 'rosette'
↓
Skin becomes black
↓
Disease spreads to adjacent skin

Clinical Features :

→ Age : >40 years
→ Sex : Males
→ Site : Nape of neck and back

Investigations : Urine sugar and urine ketone bodies

Blood sugar

Treatment :

→ Control of diabetes

→ Antibiotics like penicillins, cephalosporins

→ Skin grafting

GENERAL SURGERY

SHANMUGA PRIYA. K

SRI VENKATESWARA DENTAL COLLEGE & H
DEPARTMENT OF ORAL & MAXILLOFACIAL SURGERY
THALAMBUR, CHENNAI - 103

47/70

SHORT NOTES:

1. Trismus

→ Trismus refers to a sustained, tonic spasm of the masticatory muscles, particularly the masseter and temporalis, which results in forced jaw closure.

→ Normal Mouth opening

- Varies from patient ~~from~~ to patient, within a range of 40-60mm.

→ The width of the index finger at the nail bed is between 17 and 19mm.

→ Thus two finger's breadth (40mm) upto three fingers breadth (54-57mm) is the usual width of opening.

Measurement of mouth opening

→ Screening
- Three finger test

→ Measurement tools
- Boley gauge.
- Manufacturer's scale.

→ Influencing factors
- Dental alignment
- Age
- Gender
- Ramus length
- Gonial angle

Classification

→ Based on Range of mouth opening :-

- Mild trismus (30 - 40mm)
- Moderate trismus (15 - 30mm)
- Severe trismus (≤ 15mm)

→ Based on Duration :-

- Acute Trismus
- Subacute Trismus
- Chronic Trismus

→ Based on etiology :-

- Intra - articular
- Extra - articular

Trismus related to Dental procedures :-

→ Trismus may occur after any oral surgery that involves the pterygoid muscles or after which there is disuse of the TMJ.

→ Maxillectomy is the classical example of an oral operation that will lead to Trismus.

→ Extraction of teeth may cause trismus as a result of either inflammation involving muscles of mastication or direct trauma to the TMJ.

Management of Trismus :-

→ History taking, Examination, Investigations (Radiograph, CT, MRI)

→ Other diagnostic aids (Ultrasound, Biopsy, ESR, Full Blood picture)

→ Treatment :

- Heat therapy
- Soft diet
- Analgesics
- Muscle relaxants
  [Diazepam - 2.5 - 5 mg three times daily]
- Physiotherapy
- Surgery

Antibiotic prophylaxis of Infective Endocarditis

SRI VENKATESWARA DENTAL COLLEGE & HOSPITAL
THALAMBUR, CHENNAI - 103

Infective Endocarditis is much more likely to results from frequent exposure to random bacteremias associated with daily activities than bacteremia caused by a dental, GI tract or GU tract procedure.

→ Respiratory tract procedures:-

- Antibiotic prophylaxis may be considered for patients who undergo an invasive procedure of the respiratory tract that involves incision or Biopsy of the respiratory mucosa, such as tonsillectomy and adenoidectomy.

→ GI or GU procedures:-

- Recommended for patients who undergo GU or GI tract procedures, including diagnostic esophagogastroduodenoscopy or colonoscopy.

→ Cardiac Conditions for which prophylaxis is recommended:-

- Prosthetic cardiac valve
- Previous Infective Endocarditis
- Congenital heart disease
- Cardiac transplantation recipients who develop cardiac valvulopathy.

→ Dental procedures which require prophylaxis:-

- All dental procedures that involve manipulation of gingival tissue or the periapical region of teeth or perforation of the Oral mucosa.

Regimens for a Dental procedure

Biopsy

Situation	Agent	Regimen – Single dose 30–60 min. before Procedure. ADULTS	CHILDREN
Oral	Amoxicillin	2 gm.	50 mg/kg.
Unable to take oral medication	Ampicillin	2 gm IM or IV	50 mg/kg IM or IV
	Cephazolin or Cephtriaxone	1 gm IM or IV	
Allergic to Penicillin or Ampicillin [oral]	Cephalexin	2 gm	50 mg/kg
	Clindamycin	600 mg	20 mg/kg
	Azithromycin	500 mg	15 mg/kg
	Clarithromycin	500 mg	15 mg/kg.
Allergic to Penicillin or Ampicillin and unable to take oral medication	Cephazolin Cephtriazone	1 gm IM or IV	50 mg/kg IM or IV
	Clindamycin	600 mg IM or IV	20 mg/kg IM or IV.

→ Bacteremia resulting from daily activities is much more likely to cause IE than bacteremia associated with a Dental Procedure.

→ If the dosage of antibiotic is inadvertently not administered before the procedure, the dosage may be administered upto 2 hrs after the procedure.

→ Administration of the dosage after the procedure should be considered only when the patient did not receive the pre-procedure dose.

Biopsy

SRI VENKATESWARA DENTAL COLLEGE & HOSPITAL
DEPARTMENT OF ORAL & MAXILLOFACIAL SURGERY
THALAMBUR, CHENNAI - 103

→ The process of obtaining tissue for the diagnosis is called Biopsy.

* Fine needle aspiration cytology :-

→ also called fine needle aspiration biopsy.

→ In this a fine needle of 23 or 24 gauze, is introduced into the tumour or swelling.

→ without removing the needle out of skin over the lump, 3 to 4 times it is passed within the lesion in different directions.

→ cells are sucked into the needle or in the syringe.

→ Examples : Swellings of Thyroid, Breast, parotid.

→ Advantages : - Safe
- simple
- rapid
- pain free
- cost effective
- accurate

* Tru-cut Biopsy or core needle Biopsy :-

→ Many malignancies are not only require more tissue for the diagnosis but also require immunohistochemistry.

→ Tru-cut or core biopsy yields sufficient tissues to achieve this.

→ After giving LA, such as lignocaine 2%. about 1 to 2 ml, a small skin nick is made.

* Punch Biopsy :-

→ By using a Long instrument called punch Biopsy Forceps, Punch of the tissues is removed by closing the blades of the instrument.

→ This is done in proliferative or cauliflower like lesions or Exophytic lesions.

* Wedge Biopsy from the edge of the ulcer / growth :-

→ Examples : - malignancy developing in chronic ulcer.
- Epithelioma.

→ Edge is rapidly growing area hence maximum cancerous tissue is present, Centre has necrosis hence slough is more.

→ Hence edge is selected.

* Incision biopsy :-

- Examples : Lymphoma or Tuberculosis with matted nodes

- Incision is made over the swelling after giving LA and node is dissected all around and 1 lymph node is removed

* Excision biopsy :-

- It is strongly recommended and done for suspected malignant melanoma.

- It is important to know the depth of invasion for staging and the treatment

Tetanus

SRI VENKATESWARA DENTAL COLLEGE & HOSPITAL
DEPARTMENT OF ORAL & MAXILLOFACIAL SURGERY
THALAMBUR, CHENNAI - 103

→ Tetanus is a serious disorder with very high mortality even with treatment.

→ Causative agent : Clostridium tetani

Possible routes of Infection

→ umbilical Cord

→ Minor injuries with rusted nails, Piercing thro' ear lobes

→ tattooing

→ injections

→ GIT infections

Favourable conditions for development of tetanus

- No immunisation
- Foreign body
- Injury
- Improper sterilisation
- Devitalised tissues
- Anaerobic Conditions

Special types of Tetanus

→ Tetanus neonatorum

→ Local tetanus

→ Cephalic tetanus

→ Bulbar tetanus

→ Latent tetanus

→ Puerperal tetanus

→ postoperative tetanus

→ Otitis tetanus

Clinical Features

→ Autonomic dysfunction
- tachycardia
- Bradycardia
- Pallor
- Cardiac arrest

→ Pneumonia

→ Urinary tract infection

→ Trismus

→ Dysphagia

→ Neck Rigidity

→ Rigidity of Back muscles

→ Generalised Convulsions

Management [general]

- Admission & isolation
- Wound care
- Inj. tetanus toxoid 0.5ml to be given IM.
- Antitetanus Serum.
- antitetanus globulin (instead of Antitetanus Serum)
- Inj. Crystalline penicillin 10 lakh unit every 6 hrs.
- Metronidazole 500mg IV 8th hourly for 10 days.

Specific Management

- Mild cases ⇒ Inj. diazepam 10mg, tracheostomy set
- Seriously ill cases ⇒ nasogastric tube, Tracheostomy
- Dangerously ill cases ⇒ Ventilatory support and Bed sores avoided.

Causes of death:

i) Aspiration of pharyngeal contents into Lungs.
ii) Laryngeal spasm & respiratory arrest
iii) Autonomic disturbances

Cystic Hygroma

↦ Failure of one of the lymphatics to join the major lymph sac of the body results in a Lymphangioma

SRI VENKATESWARA DENTAL COLLEGE & HOSPITAL
DEPARTMENT OF ORAL & MAXILLOFACIAL SURGERY
THALAMBUR, CHENNAI - 103

→ In the neck, it is called Cystic Hygroma of the neck.

→ As the sac has no communications with lymphatics by the time swelling appears, the lymph is absorbed and is replaced by thin watery fluid secreted by Endothelium.

→ Hence it is also called ~~Hyg~~ Hydrocele of the neck.

Clinical features :-

→ mostly occurs in infancy or early childhood.

→ Present as small vesicles sometimes

→ When the child cries or strains, the swelling increases in size and become prominent due to increased intrathoracic pressure which is transmitted through root of the neck.

→ Locations : Lateral aspect of neck (posterior triangle).

→ Soft, cystic, fluctuant, partially compressible swelling

→ Lymphangioma is a multilocular swelling consisting of aggregation of multiple cysts.

→ These cysts may intercommunicate and sometimes may insinuate between muscle planes.

→ Hence, it gives the sign of compressibility.

→ Complete reducibility is not a feature.

→ Swelling is Brilliantly transilluminant because it contains Clear fluid

Treatment :

- Surgical excision
- All loculi or cysts should be removed.
- Sclerotherapy.
- Injection type of treatment is not favoured at present.

Differential diagnosis

- Haemangioma
- Lipoma
- Cold abscess.

Complications

- Difficulty in Breathing due to Large size (in neonates & infants).
- Secondary infection
- Lymphangioma in the mediastinum can give rise to dyspnoea, dysphagia due to Compression on the trachea / oesophagus.

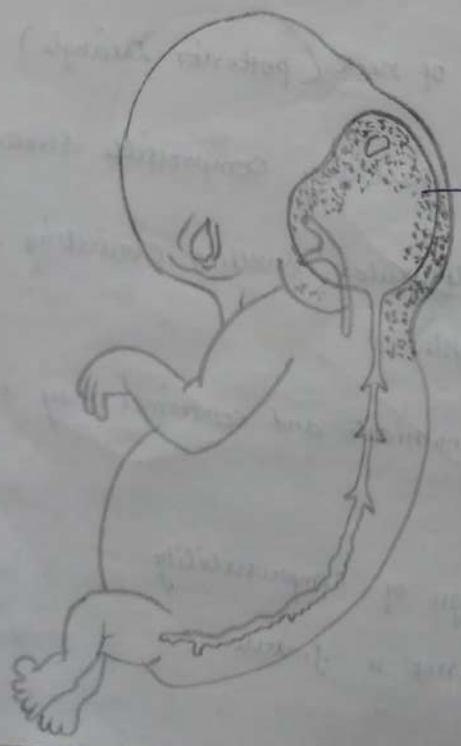

→ Fetal cystic hygroma.

Autonomic disturbances

Ludwig's Angina

SRI VENKATESWARA DENTAL COLLEGE & HOSPITAL
DEPARTMENT OF ORAL & MAXILLOFACIAL SURGERY
THALAMBUR, CHENNAI - 103

→ It refers to cellulitis of Submental and submandibular regions combined with inflammatory oedema of the mouth.

→ Virulent streptococcal organisms are responsible for infection surrounding Submandibular region

→ Anaerobes play a major role.

Clinical features

→ Elderly patient who presents with diffuse swelling in the Submandibular & submental region

→ Edema of the floor of the mouth, as a result of which tongue is pushed upwards resulting in difficulty in swallowing.

→ High grade fever with toxicity.

→ Putrid Halitosis is characteristic of this Condition.

Treatment

→ Rest and Hospitalisation

→ Appropriate antibiotics

→ Intravenous fluids to correct the dehydration and Ryle's tube feeding.

→ If it does not respond to conservative treatment, surgical intervention is recommended.

→ Surgery

Under general anaesthesia, 5-6cm curved incision is made

below the mandible in the submandibular region over most prominent part of the swelling.

- Submandibular gland is mobilised, mylohyoid muscle is divided and the pus is drained.
- Even if pus is not found, the edematous fluid comes out greatly improving the condition of patient.
- Wound is closed with loose sutures, after irrigating the cavity with antiseptic agents and a drainage tube is kept in place.

Complications

* Mediastinitis
* Septicemia
* Oedema of the glottis due to spread of the cellulitis via a tunnel occupied by Stylohyoid to submucosa of the glottis.

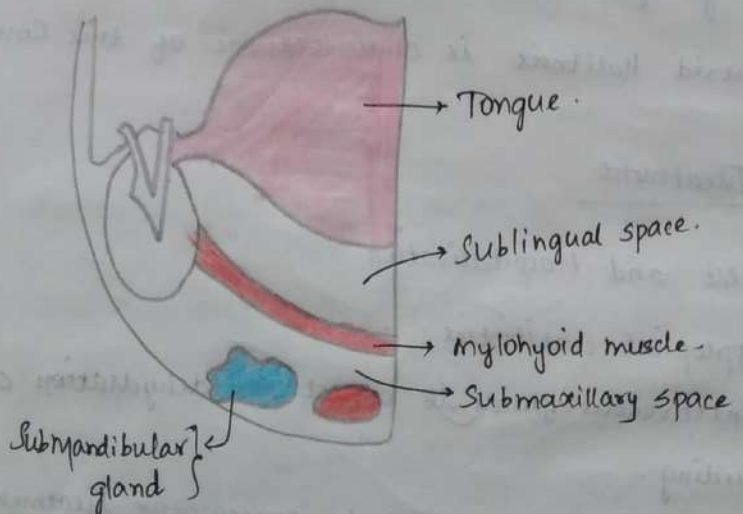

Warthin's Tumour

SRI VENKATESWARA DENTAL COLLEGE & HOSPITAL
DEPARTMENT OF ORAL & MAXILLOFACIAL SURGERY
THALAMBUR, CHENNAI - 603

Also called as papillary cystadenoma Lymphomatosum.

→ Adenolymphoma is not a Lymphoma.

→ It is a misnomer.

→ It is a Benign parotid Tumour and next Common to pleomorphic adenoma.

→ Origin: During development some parotid tissue gets included within Lymph nodes which are present within the parotid Sheath.

Histology:

→ It is composed of double layered eosinophilic epithelium, inner cells are columnar.

→ Presence of Lymphatic tissue in the stroma, and Lymph follicles is characteristic of adenolymphoma.

Clinical features

→ Age: middle aged / elderly males.

→ sex: males.

→ number: Sometimes multiple

→ Site: Bilateral.

→ Smooth surface, round Border with soft, cystic Consistency

→ Classically situated at the lower pole of parotid elevating the ear lobule.

→ May be multicentric.

→ This Tumour affects only parotid gland.

Treatment

→ well defined capsule present

→ Hence enucleation can be done.

8. Tracheostomy

Tracheostomy Tube

i) Fuller's bivalved tracheostomy tube.
   - It has got outer tube & inner tube
   - Outer tube is biflanged & so insertion is easier.

ii) Jackson's tracheostomy tube
   - It has got outer tube, inner tube & an obturator.

iii) Red - Rubber tracheostomy tube.

iv) PVC tracheostomy tube.

Indications for tracheostomy

→ In head, neck & facial injuries
→ Tetanus.
→ Tracheomalacia after thyroidectomy.
→ Laryngeal edema / spasm.
→ major head & neck surgeries like Commando's operation, block dissection, etc....

Tracheostomy. Types

→ Emergency tracheostomy
→ Elective tracheostomy.

Technique of Tracheostomy

→ Neck of the patient is hyperextended by placing sand Bags under the shoulder.

→ Vertical or Horizontal incision is made.

→ Deep fascia is opened.

→ Strap muscles are retracted laterally

→ Isthmus is divided or retracted below

→ 2nd and 3rd tracheal rings are opened

→ circular opening is made.

→ Tracheostomy tube is placed.

→ It is tied around the neck.

→ Endotracheal tube can be kept in situ only for 7 days.

Tracheostomy care

4 → Regular Suctioning of the tube.

→ Cleaning of Tracheostomy tube.

→ Humidification of the inspired air.

Complications of Tracheostomy

→ Tracheal stenosis

→ Bleeding

→ Aspiration

→ pneumothorax

→ Surgical emphysema in the neck.

→ Mediastinal Emphysema

→ Tracheostomy dependency.

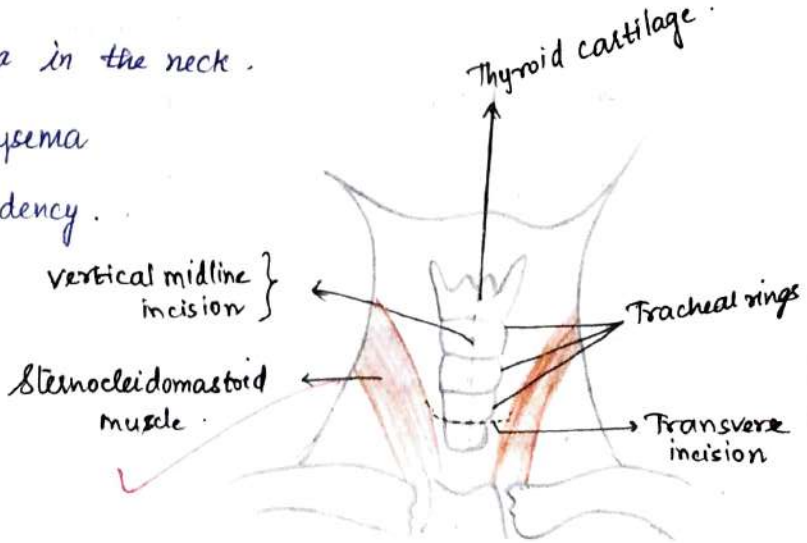

9. Lymphoma

→ Lymphomas are the progressive neoplastic condition of the Lymphoreticular system which arises from stem cells.

→ Lymphoma is the third most common malignancy among the children.

Classification

→ WHO modified REAL classification of Lymphoma

* B-cell neoplasms
  - Precursor B-cell neoplasm : ALL, LBL.
  - Precursor B cell neoplasm – It includes all B-related non-hodgkin's lymphomas.

* T-cell and putative NK cell neoplasms
  - Precursor B-cell neoplasm – ALL, LBL – T cell related.
  - Precursor T-cell and NK cell neoplasm.

* Hodgkin's Lymphoma.
  - Predominant Hodgkin's Lymphoma (nodular Lymphocyte type).
  - Classical Hodgkin's lymphoma.
    - Nodular Sclerosis
    - Lymphocyte rich
    - Mixed cellularity
    - Lymphocyte depletion

* Precursor lymphoid neoplasms

* Immunodeficiency associated Lymphoproliferative disorders.

Etiology:

- Genetic predisposition
- Sjogren's syndrome.
- HIV infection
- Virus etiology
- Bloom's syndrome
- celiac sprue.

Carbuncle

SRI VENKATESWARA DENTAL COLLEGE & HOSPITAL
DEPARTMENT OF ORAL & MAXILLOFACIAL SURGERY

→ This is an infective gangrene of the subcutaneous tissue caused by S. aureus.

→ It commonly occurs in diabetic patients.

→ Poor immunity, radiotherapy patients can develop carbuncle.

→ Sites :- - Nape of neck.
- Skin of these sites is coarse & has poor vascularity.

Pathology :-

→ Initial lesion is similar to a Boil in the form of hair follicle infection with perifolliculitis.

→ Since majority of patients are diabetics, infection takes a virulent course & results in necrosis of subcutaneous fat which gives rise to multiple abscess.

→ These abscesses are intercommunicating and they open to exterior by multiple openings which are called sieve-like openings.

→ This appearence is described as Cribriform appearence which is Pathognomic of Carbuncle.

Clinical features

→ Severe pain
→ Swelling in nape of neck.
→ Chills, rigors
→ Surface is red, looking a red hot coal.
→ Surrounding area is indurated.

→ centre of carbuncle softens

→ satellite vesicles appear.

→ end result is development of large crateriform ulcer with central slough.

Complications

→ Worsening of diabetic status resulting in Diabetic Ketoacidosis.

→ Extensive necrosis of skin overlying carbuncle.

→ Septicemia

→ toxaemia

Treatment

→ Diabetes control preferably with injectable insulin.

→ Parenteral antibiotics

eg. Vancomycin.
Cloxacillin.
Flucloxacillin.
Erythromycin.

→ Cruciate incision.

→ Practically, it amounts to excision of carbuncle.



CARBUNCLE

ESSAYS:

Levels of Cervical lymph node. Describe Lymphatic drainage of Head & Neck.

SRI VENKATESWARA HOSPITAL
DEPARTMENT OF ORAL & FACIAL SURGERY
THALAMBUR, CHENNAI - 103

Levels of Neck nodes.

Memorial Sloan - Kettering Cancer Centre levelling of neck nodes.

Level I : Submental (Ia) and Submandibular (Ib) lymph nodes.

Level II : Lymph nodes in upper deep cervical region

Level III : Lymph nodes in middle cervical region

Level IV : Lymph nodes in lower cervical region

Level V : Lymph nodes in posterior triangle including supraclavicular region.

Level VI : Lymph nodes in the midline neck - Pretracheal and prelaryngeal.

Level VII : Lymph nodes in the mediastinum.

Lymphatic Drainage of Head & neck:

* Waldeyer's Lymphatic Ring (Inner)
  - It consists of adenoids above, Lingual Tonsils below and two of palatine tonsils laterally one on each side.

* Outer circular chain of nodes (outer Waldeyer's ring)
  - Occipital, post-auricular, pre-auricular, parotid, facial, submandibular, submental, superficial cervical and anterior cervical.

Facial nodes are :-

1) Superficial
   - Upper - infra-orbital
   - Middle - buccinator
   - Lower - supramandibular

ii) Deep groups - in relation to pterygoids

Submandibular Lymph nodes drain:

- The side of the nose
- The cheek
- Angle of the mouth
- Entire upper lip
- Outer part of the lower lip
- The gums
- Side of the tongue

Submental lymph nodes -

→ Drain from
- Central part of the lower lip,

floor of the mouth & apex of the tongue.

Superficial ~~lymph~~ cervical nodes -

- They lie on outer surface of the [illegible] around the external jugular vein.
- They drain the parotid region and lower part of the ear

Deep cervical Lymph nodes -

- [illegible] cervical lymph nodes ⟶ Below the digastric and in front of Internal jugular vein

[illegible] nodes ⟶ Above the omohyoid and [illegible] vein

[illegible] finally from a [illegible] thoracic [illegible]

LYMPHATIC DRAINAGE OF NECK

SRI VENKATESWARA ... DEPARTMENT OF ORAL & ... TIRUPATI, ...

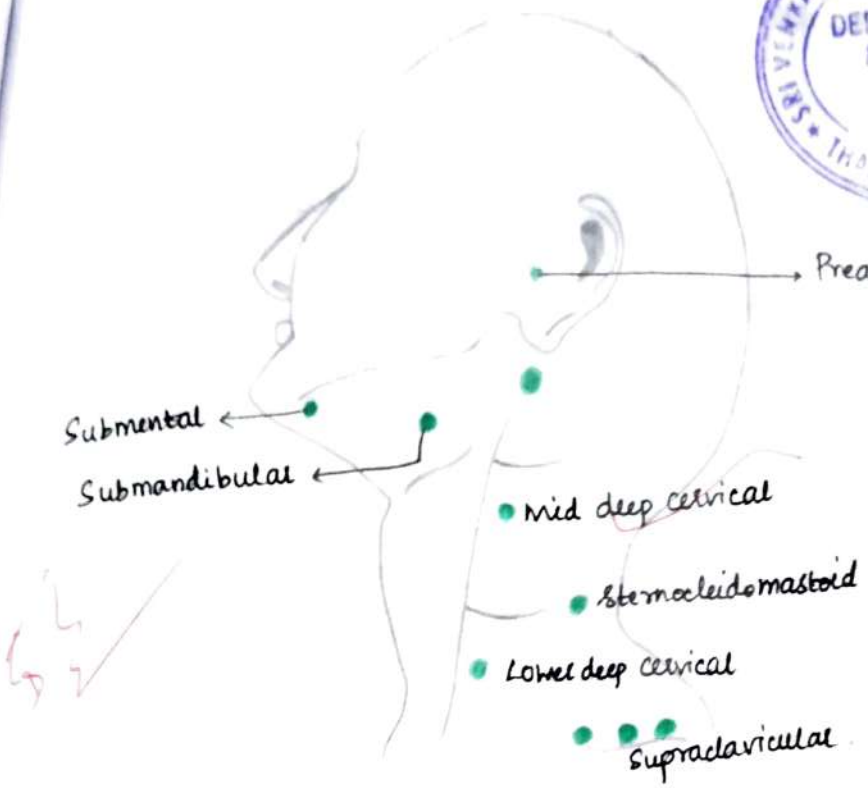

2. Define shock. Describe in detail about the pathophysiology, management of neurogenic shock.

→ Shock is defined as an acute clinical syndrome characterised by hypoperfusion and severe dysfunction of vital organs.

Classification

- Hypovolemic shock.
- neurogenic shock.
- Distributive shock.
- Cardiogenic shock.

Neurogenic shock

→ It is a life threatening condition caused by irregular blood circulation in the Body.

→ Trauma or injury to the spine can cause this disruption.

→ It can occur after damage to CNS such as Spinal cord injury.

Causes:

- High spinal cord injury
- Vagolytic shock.

Features:

- Hypotension without Tachycardia, may deteriorate to produce shock and cardiac arrest

Pathophysiology :-

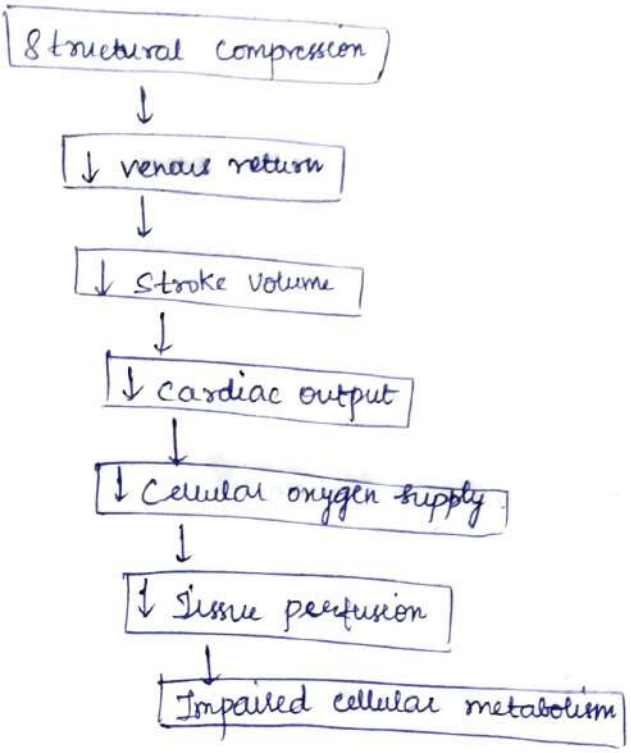

Medical management :-

⇒ Early acute Stage.

- maintaining ability to Breathe.
- Preventing shock,
- Immobilising neck to prevent further spinal cord damage.
- Medications ⇒ IV methylprednisolone.
- Immobilisation ⇒ To bring the spine into proper alignment or Both.
- Surgery.
- Experimental treatments

- IV fluids
- inotropes
- vagolytics as necessary.

SRI VENKATESWARA DENTAL COLLEGE & HOSPITAL
DEPARTMENT OF ORAL & MAXILLOFACIAL SURGERY
THALAMBUR, CHENNAI - 103

Clinical features

- History of emotional stress or pain of a sudden nature.
- Bradycardia
- Pallor.
- Tachypnea
- Fainting
- Reflexes are usually intact.
- Poikilothermia


Loss of consciousness


Dilated pupils


Hypotension


Heart rate slow

- Warm, dry extremities


Peripheral vasodilatation

ORAL SURGERY Sharath Sadasivan

SRI VENKATESWARA DENTAL COLLEGE & HOSPITAL
DEPARTMENT OF ORAL & MAXILLOFACIAL SURGERY
THALAMBUR, CHENNAI - 103

I Elaborate on.

1. Levels of cervical lymph node. Describe lymphatic drinage of head & neck.

38/40

Level I: Submental (Ia) and Submandibular (Ib) lymphnodes.

(Ia) drinage: floor of mouth, anterior oral region, tongue tip, anterior mandibular incisors region

(Ib) drinage: oral cavity, anterior nasal cavity, soft tissue of midface, submandibular gland.

Level II:
* upper deep cervical lymphnodes.
* Lymphonodes in sternocleido mastoid muscle and near spinal accessory nerve.

Drinage: oral cavity, nasal cavity, nasopharynx, oropharynx, hypopharynx, larynx, parotid gland.

Level - IV

* Lower deep cervical lymphnodes.

from hyoid bone to omohyoid muscle or cricoid membrane.

Drainage: Oral cavity, Oropharynx, nasopharynx, hypopharynx, larynx.

Level - IV lymph nodes in lower cervical region (lower jugular node). from omohyoid muscle to cricothyroid membrane to clavicle.

Drainage: Hypopharynx, thyroid, cervical, esophagus, larynx

Level - V lymph nodes in posterior triangle.

→ Supra clavicular region

→ anterior border of trapezius

→ sternocleidomastoid posterior border.

Drainage: scalp, Parotid gland, nasopharynx, thyroid gland etc..

Level VI: Lymph nodes in anterior midline of neck.

Pretracheal & Prelaryngeal region.

Drainage: Thyroid gland, glottis, & subglottic larynx, apex of Pyriform sinus, cervical oesophagus.

Level VII - Lymph nodes in the mediastinum inferior to suprasternal notch to innominate artery below

SRI VENKATESWARA DENTAL COLLEGE & HOSPITAL
DEPARTMENT OF ORAL & M... AL
THALAMBUR CHENNAI - 103

2. Define shock, Describe in detail about the Pathophysiology, management of neurogenic shock.

shock is defined as an acute clinical syndrome characterised by hypoperfusion and severe dysfunction of vital organ, It is the failure of the circulatory system to supply blood in sufficient quantities to organ for survival.

Classification:

* Hypovolemic shock.
* Cardiogenic shock.
* Distributive shock.
* Septic shock
* Anaphylactic Shock.
* neurogenic shock
*

Pathophysiology:

Decreased effective circulatory blood volume
↓
Decreased Cardiac output
↓
Decreased blood flow
↓
Decreased supply of oxygen.
↓
anoxia
↓
Shock

Neurogenic Shock:

Clinical features:-

* History of emotional stress of sudden nature.
* Bradycardia or pallor
* Tachypnea
* Fainting.
* Reflexes are usually intact.

Cause:

* It occur due to spinal cord injury which leads to dilation of Splenchnic Vessels.
* There will be bradycardia, hypotension, arrhythmias and decreased Cardiac output

Management:

* Vasoconstrictor administration
* Oxygen administered.
* Hemodynamics should be maintained
* Airways are cleared.
* fluid therapy should be given.
* Intravenous methylprednisolone therapy is done.
* Dopamine & phenylephrine can be used.

SRI VENKATESWARA DENTAL COLLEGE & HOSPITAL
DEPARTMENT OF ORAL & MAXIMUM ...AL
THALAMBUR, CHENNAI - 103

II

1. Trismus:

-> Trismus or 'lock jaw' is caused due to spasm of muscles of mastication.

-> Patients affected by trismus have an inability to open their mouth.

-> Normal mouth opening is about 4cm or 40mm.

-> Based on this measurement, trismus can be graded as

* mild > 30mm
* moderate 15-30mm
* severe < 15mm

Causes:

-> Spasm of muscles of mastication due to abnormality or disturbances in the trigeminal nerve.

-> Infection: This can be due to many reasons such as pulpal, periodontal origin around 3rd molar.

-> Trauma: Fracture of bones of jaws.

-> Tmj disorders.

-> Tumours.

-> Congenital problem.

Treatment:

-> Heat therapy

-> Analgesics, Anti inflammatory drugs.

-> Physiotherapy.

DEPARTMENT OF ORAL & MAXILLOFACIAL SURGERY
SRI VENKATESWARA DENTAL COLLEGE & HOSPITAL
IYYAPPANTHANGAL, CHENNAI - 103

11

1. Trismus:

→ Trismus or 'lock jaw' is caused due to spasm of muscles of mastication.

→ Patients affected by trismus have an inability to open their mouth.

→ Normal mouth opening is about 4cm or 40mm.

→ Based on this measurement, trismus can be graded as:

* mild > 30mm
* moderate 15-30mm
* severe < 15mm

Causes:

→ Spasm of muscles of mastication due to abnormality or disturbances in the trigeminal nerve.

→ Infection: This can be due to many reasons such as Pulpal, Periodontal origin around 3rd molar.

→ Trauma: Fracture of bones of jaws.

→ Tmj disorders.

→ Tumours.

→ Congenital problem.

Treatment:

→ Heat therapy

→ Analgesics, Antiinflammatory drugs.

→ Physiotherapy.

2. Antibiotic Prophylaxis for infective Endocarditis.

Drug	Dose	Route	Timing.
standard Amoxicillin.	2g	oral	1hr before Procedure
Penicillin allergy:			
Azithromycin	500mg	oral	1hr before Procedure
Cephalexin	2g	oral	1hr before Procedure.
Clindamycin	600mg	oral	1hr before Procedure.
Ampicillin	2g	I.V	1hr before Procedure

Risk groups:

* Patient with valvular heart disease
* Patient with Previous episode of infective endocarditis.
* Patient with prosthetic valve.
* Cyanotic Congenital heart disease.

SRI VENKATESWARA DENTAL COLLEGE & HOSPITAL
DEPARTMENT OF ORAL & ... IAL ... RY
THALAMBUR, CHENNAI - 103

3. Biopsy:

-> The Process of obtaining tissue for the diagnosis is called biopsy.

-> The Various types of biopsies are.

* Fine needle aspiration biopsy (FNAC)

• A fine needle is pierced in the swelling and the exudate is exacted and tested for the types of cells in it.
Eg: thyroid swelling

* True cut biopsy:

• After giving L.A part of the lesion a small tisue is taken by incision.

* Punch biopsy:

• Long instruments called punch biopsy forceps are used.
• Done in Cauliflower like lesion or Exophytic lesion.

* Wedge biopsy:

• Done in malignant ulcer suspect
• edge is selected as it rapidly grows there hence maximum cancerous tissue is present.

5. Incision biopsy:

• when lymphoma or tuberculosis with melted no[illegible] is suspected.

6. Full thickness Excision biopsy:

• Suspected recommended and done for suspected malignant melanoma.

---

4. Tetanus:

→ It is infective condition caused by Clostridium tetani leading to reflex muscle spasm.

Pathogenesis:

Spore
↓
enters wound
↓
it germinates in anaerobic media releasing bacteria, which multiply.
↓
Releasing of Exotoxin
- Tetanospasmin
  - Through pheripheral sheath
  - Circulation.
- Tetanolysin
  - Haemolysis

SRI VENKATESWARA DENTAL COLLEGE & HOSPITAL
DEPARTMENT OF ORAL & MAXILLOFACIAL
THALAMBUR, CHENNAI - 103

Clinical features:

Symptoms : Jaw stiffness.
Anxiousness
Headache
Dysphagia.
Dyspnoea.

Signs : Trismus.
Risus Sardonicus.
neck rigidity
: Tonic clonic convulsions

Types: Early tetanus, Latent tetanus, Ascending tetanus, Decending tetanus, Cephalic tetanus.

Different Postures.

-> opisthotonus, Orthotonus, Emprosthotonus, Pleurosthotonus.

Complication:

-> Fractured bone, Heamatoma, Carditis, Toxaemia.

Treatment:

-> Antitetanus globulin - 3000 units Im Single dose.

-> Antitetanus Serum - 1000 units ½ Im, ½ IV.

→ IV – diazepam 2omg – 6HR hourly
IM – phenobarbitone 3omg – 6HR hourly.
IV – Chlorpromazine 25mg – 6HR hourly.
→ Ventilator support.

5. Cystic hygroma:

→ Also called as Cavernous lymphangioma.

→ It is a cystic swelling due to sequestration of a portion of jugular lymph sac from lymphatic system during developmental period in utero.

→ Present at birth and may cause obstructed labour.

→ Also called as hydrocele of neck.

Sites: Posterior triangle of neck.
Cheek.
Axilla
Tongue
Groin.

Pathology: Aggregation of cysts like soap bubbles.

Clinical features:

→ Swelling is smooth, fluctuant, soft.

→ Swelling rapidly increases in size.

SRI VENKATESWARA DENTAL COLLEGE & HOSPITAL
DEPARTMENT OF ORAL
THALAMBUR, CHENNAI - 103

Treatment:

-> Aspiration of Content.

-> Respiratory obstruction - aspiration x
Tracheostomy.

6. Ludwig's angina:

-> It is an inflammatory oedema of submandibular region and floor of mouth. Commonly due to Streptococcal infection.

-> Causes diffuse swelling and brawny oedema of Submandibular region.

-> It is common in Severely ill and in advanced malignancy causing trismus.

Precipitating factors:

-> Carious tooth
-> Oral malignancy.
-> Submandibular salivary infection.
-> Chemotherapy.

Clinical features:

-> Fever.
-> Toxicity
-> Trismus

→ Intra oral oedema.

→ Putrid halitosis

Treatment: : Antibiotics
: IV fluids.

7. Warthin's tumor:

→ It is called as Adenolymphoma.

→ It is a benign tumour that occurs only in Parotid.

→ It is composed of double layer of columnar epithelium, with papillary projection into cystic spaces

Clinical features:

→ Slow growing.

→ Smooth, soft

→ fluctuant swelling.

→ non tender.

→ common in males.

→ Age: 60 year.

→ Often bilateral.

Investigation:

→ Produces a hot spot in Technitium pertechnetate scan

→ FNAC.

Treatment: Superificial parotidectomy.

8. Tracheostomy:

SRI VENKATESWARA DENTAL COLLEGE & HOSPITAL
DEPARTMENT OF ORAL
THALAMBUR, CHENNAI - 103

Types: Emergency tracheostomy.
Elective tracheostomy.

Tracheostomy tube:

→ fully bivalved tracheostomy tube
→ Jackson's tracheostomy tube.

Indications:

→ In head, neck, facial injuries.
→ Tetanus.
→ Tracheomalacia.
→ Laryngeal oedema.

Technique:

→ neck of patient is hyperextended by placing Pillows under the shoulder.
→ Vertical or horizontal inlision is made.
→ Deep fascia is opened.
→ Sharp muscles are retracted laterally
→ 2nd & 3rd tracheal ring are opened and Circular opening is made.
→ Tube is placed, tied around neck.

SRI VENKATESWARA DENTAL COLLEGE & HOSPITAL
DEPARTMENT OF ORAL
THALAMBUR, CHENNAI - 103

1. Lymphoma:

* It is a primary malignant lymphoproliferative disease involving lymphnodes, liver, spleen or bone marrow.

* Occasionally seen in any other organs

* It can be either Hodgkin lymphoma or non Hodgkin lymphoma.

Classification of lymphoma:

1. B-cell neoplasms:
   * Precursor B-cell neoplasm
   * Peripheral B-cell neoplasm → all non Hodgkin lymphoma of B-cell origin.
2. T-cell and putative NK cell neoplasms:
   * Precursor T-cell lymphoma.
   * peripheral T-cell & NK cell neoplasms.
3. Hodgkin lymphoma.
   * Predominant Hodgkin lymphoma - nodular type.
   * Classical Hodgkin lymphoma.
     - nodular sclerosis
     - lymphocyte rich
     - mixed cellularity
     - lymphocyte depletion

10. Carbuncle.

→ It is an infective gangrene of skin & subcutaneous tissue.

→ Organism causative - staphylococcus.

→ Site common: back nape of neck.

→ Common in male.

Pathophysiology:-

infection.

↓

Small vesicle develop.

↓

Sieve like pattern

↓

Red indurated skin with discharging pus.

↓

Many vesicle fuse together to form a central necrotic ulcer with fresh peripheral vesicle looking like a rosette.

↓

Skin becomes black due to blockage of cutaneous vessels.

↓

Disease spread to adjacent skin rapidly.

SRI VENKATESWARA DENTAL COLLEGE & HOSPITAL
DEPARTMENT OF ORAL & MAXILLOFACIAL SURGERY
THALAMBUR CHENNAI - 103

Complication:

* Extensive necrosis of skin
* septicemia.

Treatment:

* Proper Control of diabetes
* Antibiotics like penicillins, Cephalosporins, or depending on Culture sensitivity
* Drainage is done by Cruciate incision & debridement all dead tissue is done Excision is done later.
* Once wound granulates well, skin grafting may be required.

SRI VENKATESWARA DENTAL COLLEGE & HOSPITAL
Shalaa. S.I
DEPARTMENT OF ORAL & MAXILLOFACIAL SURGERY
THALAMBUR, CHENNAI - 103

I. Elaborate on:-

1. Level of cervical lymph nodes. Describe lymphatic drainage of Head & neck

45/70

According to Memorial Sloan-kettering Cancer Centre leveling of neck nodes

Level I: Submental (Ia) & submandibular lymphnode

Level II:- Lymphnodes in upper deep cervical region. It extends from base of Skull to hyoid bone and from lateral margin of Sternohyoid to posterior margin of Sternomastoid muscle. Level IIa is below & in front of line of Spinal accessory nerve in the upper part & Level Ib is above & posterior to line of spinal accessory

Level III:- Lymphnodes in middle cervical region (Middle Jugular node) ie from omohyoid muscle / Cricothyroid membrane to Clavicle

Level IV:- Lymph nodes in lower cervical region from omohyoid to Clavicle

Level V:- Lymphnodes in posterior triangle (posterior cervical region from posterior border of Sternocleidomastoid muscle to anterior border of trapezius muscle Level Va is above the line of spinal

accessory nerve in the lower part: Vb is below the level of spinal accessory nerve

Level VI :- Lymph nodes in the midline neck (Anterior compartment nodes) - pretracheal & prelaryngeal from hyoid bone above to suprasternal notch below medial border of carotid sheath on either side

Level VII :- Lymphnodes in the mediastinum (upper mediastinal nodes) inferior to suprasternal notch to innominate artery below

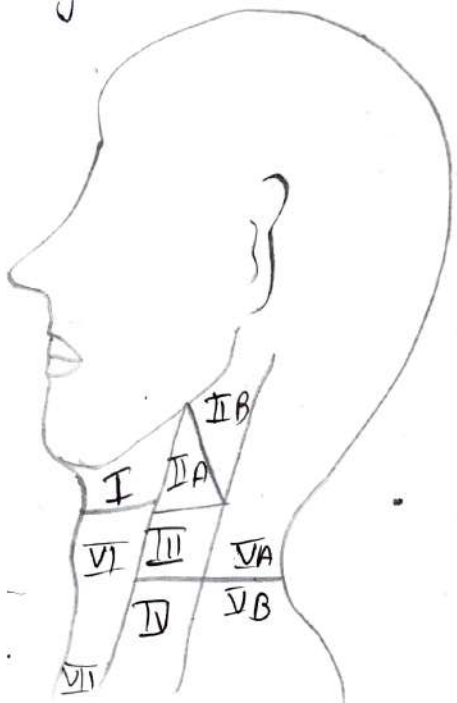

Levels of lymphnodes

Drainage area of lymphnodes

Level Ia lymphnodes :- Floor of mouth, anterior oral tongue, anterior mandibular alveolar ridge, lower lip

Level Ib lymphnode :- Oral cavity, anterior nasal cavity, soft tissue of midface, Submandibular gland.

Level IIa & IIb lymph nodes:- Oral cavity, nasopharynx, hypopharynx, nasal cavity, oropharynx, larynx, parotid gland

Level III lymphnodes:- Oral cavity, oropharynx, nasopharynx, hypopharynx, larynx

Level IV lymphnodes:- Hypopharynx, thyroid, cervical esophagus, larynx

Level V lymphnods:- Scalp, parotid gland, nasopharynx, thyroid gland etc.

Level VI lymphnodes:- Thyroid gland, glottis & subglottic larynx, apex of pyriform, SMG, cervical esophagus

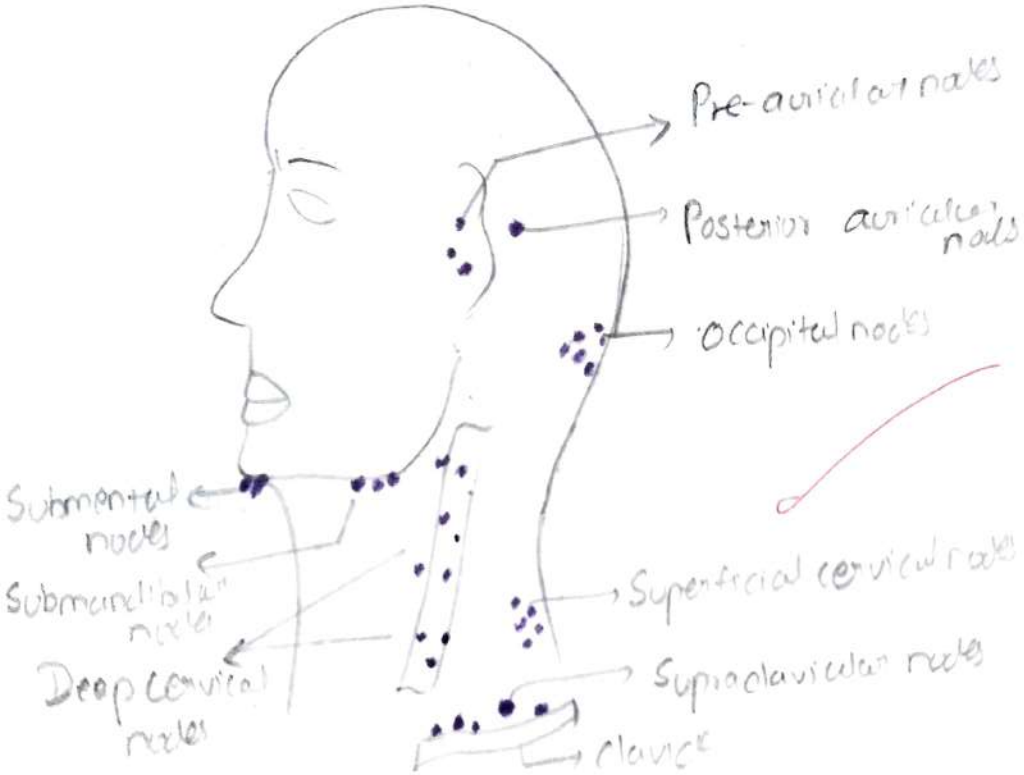

2. Define shock. Describe in detail about the pathophysiology, management of neurogenic shock

Shock is defined as an acute clinical syndrome characterized by significant, systemic reduction in tissue perfusion, resulting in decreased tissue oxygen delivery & insufficient removal of cellular metabolic products, resulting in tissue injury & severe dysfunction of vital organs

Neurogenic Shock:-

It is a type of distributive shock is caused by suppression (or) loss of sympathetic tone caused by disruption of sympathetic nervous system like spinal injury, spinal anaesthesia & drugs

Pathophysiology:-

Disruption of sympathetic nervous system

↓

Loss of sympathetic tone → Parasympathetic nervous system response

↓

Venous & arterial vasodilation

↓

↓ Heart rate

↓

Decrease in Blood pressure

↓

Decrease in venous return

SRI VENKATESWARA DENTAL COLLEGE & HOSPITAL
DEPARTMENT OF ORAL & MAXILLOFACIAL SURGERY
IYALAMBUR, CHENNAI - 103

↓
Decrease in Stroke volume
↓
Decrease in cardiac output
↓
Decrease in cellular oxygen supply
↓
Decrease in Tissue perfusion
↓
Impaired cellular metabolism

Clinical features:-

- History of emotional stress or) pain of a sudden nature
- Bradycardia or) pallor
- Tachypnea
- Fainting
- Reflexes are usually intact

Etiology:- Spinal cord injury which leads to dilatation of splanchnic vessels

Management:-

- Blood pressure should be controlled by giving vasoconstrictors
- Fluid replacement Therapy:-
  Plasma, normal saline, dextrose, Ringer's lactate, plasma expander (Haemaccel). Dosage is maximum 12 can be given in 24 hrs.
  Initially crystalloids then colloids are given, Blood transfusion is done

- Inotropic agents like Dopamine, dobutamine, adrenaline
- Steroid is often life saving 500mg - 1000mg of hydrocortisone can be given. It improves the perfusion, reduces the capillary leakage & systemic inflammatory effects
- Central venous pressure line to perfuse adequately & to monitor the fluid balance
- Ventilator & ICU critical care management
- Military antishock trouser (MAST) provides circumferential external pressure of 40mm Hg. It is wrapped around lower limbs & abdomen & Inflated with required pressure It redistributes the existing blood & fluid towards centre. It should be deflated carefully & gradually

SRI VEN... DEPARTMENT OF ORAL & ... IAL ... ERY THALAMBUR, CHENNAI - 103

IV. Write notes on

1. Trismus :-

Tonic contraction of muscles of jaw causes restricted mouth opening

Etiology :-

i) Inflammatory

- Pericoronitis
- Dentoalveolar abscess
- odontogenic infection
- TMJ Ankylosis
- Parotitis
- Quinsy

ii) Traumatic :-

- Infection after 3rd molar extraction
- Edema from surgery
- Fracture of mandible
- Fracture of Zygomatic arch

iii) Neoplastic :-

- Submucous fibrosis
- Carcinoma of oral cavity

iv) Neurogenic

- Tetanus
- Tetany
- Hysteria

Pathophysiology :-

Muscle damage
↓
Pain reflex
↓
Muscle contraction
↓
Loss of range of motion

Clinical features:

- Spasm & rigidity of all muscles of jaw
- Jaw stiffness & pain
- Presence of Headache, depressed
- Presence of dysphagia

Management:-

Most commonly resolves in 2 weeks

Acute phase:-

- Soft diet
- Heat therapy
- Analgesics → non-steroidal anti inflammatory agents (acetaminophen 325 mg, Ibuprofen 200 mg every 6hrs)
- Muscle relaxants, Benzodiazepines (diazepam 2-5mg, 3 times/day)

Post operative:- Stretching exercise, multiple session per day, massaging of masticatory muscles & other jaw stretching

Chronic cases:- Intensive physiotherapy, Micro-current therapy. Rehabilitation devices

SRI VENKATESWARA DENTAL COLLEGE & HOSPITAL
DEPARTMENT OF ORAL
MEDICINE & RADIOLOGY
CHENNAI - 103

2. Antibiotic prophylaxis of infective endocarditis

Antibiotic regimen for prophylaxis of endocarditis in adults at moderate (or) high risk is as follow

- Oral cavity, respiratory tract, (or) esophageal procedures (in patients at high risk, administer a half dose after the initial dose)

- Standard regimen:-

  Amoxicillin 2g oral 1 hour before procedure

- Inability to take oral medication of Standard regimen :-

  Ampicillin 2g IV or IM within 30mn of procedure

- If patient is allergic to penicillin:-

  Clarithromycin 500mg (or) Azithromycin 500mg orally 1 hour before procedure

(or)

Cephalexin or) cefadroxil 2g orally 1hr before procedure

(or)

Clindamycin 600mg oral 1hr before procedure

- If patient is allergic to penicillin & is unable to take oral medication

Clindamycin 600mg IV 30 min before procedure

(or)

Cefazolin 1.0g IV or IM 30mn before procedure

3. Biopsy

Biopsy is defined as the piece of tissue taken from the body to examine it closely

Types of biopsies:-

- Incision biopsy
- Excision biopsy
- Trucut biopsy
- Pap smear
- FNAC
- Ultrasound-guided biopsy
- Brush biopsy

Incision biopsy:

- This is the excision of a portion of lesion for microscopic examination
- This method is employed on large, diffuse lesions which has size of 2cm in its greatest dimension
- Suspected for malignancy

DEPARTMENT OF ORAL & MAXILLOFACIAL SURGERY

Types of incision biopsy:-

- Punch biopsy:- This is done using a surgical punch of diameter 1.5 to 8 mm. This is incisional biopsy is done
- Wedge biopsy:- It is done by making wedge shaped incision which begins 2-3mm from normal tissue

Excision Biopsy:-

- For small lesions clinically benign
- Complete lesion should be removed for examination & diagnosis

Trucut biopsy:-

Specialized device wherein gun with trucut tip is inserted into soft tissue organ & gun is fired to drive the punching needle of to catch & cut the adequate tissue. Done in prostate, breast, & surface tumors

FNAC:-

- To find whether it is malignant or not
- cytological study of tumor cells
- Done by 23 (or 24 gauge needle
- negative pressure by aspiration & contents smeared on glass slide

Frozen Section biopsy:-

- It is an unfixed fresh tissue is frozen in a metal & sections are made
- Advantage of technique is that; it surgeon can decide further steps

Ultrasound-guided (or) CT-guide

- large needle with assisted CT-scan equipment
- Simultaneous CT scan allow identification & visualization of exact size of tumor on computer screen

Brush Biopsy :-

- Brush biopsy instrument, bar-coded glass slide, alcohol-based fixative & protective plastic case for mailing
- nylon brush is designed to collect cells from cell layer of epithelium
- Slide is analyzed by computer program designed for pathological review

4. Tetanus:-

It is a disease of nervous system characterized by intensive activity of motor neuron & resulting in severe muscle spasm

Etiology:-

Anaerobic gram positive Bacilli Clostridium tetani

Clinical Features:-

- Trismus is common
- Jaw stiffness spasm
- Headache, delirium & sleeplessness
- dysphagia & dyspnea

Signs :-

- Spasm & rigidity of all muscles
- Hyperpyrexia
- Respiratory changes due to laryngeal muscle spasm, infection aspiration

- Abdominal wall rigidity
- Tonic clonic convulsions
- Retention of urine & constipation
- Cardiac arrest & death
- Symptoms will be aggravated by stimuli - like light & noise

Differential diagnosis:
- Strychnine poisoning
- Epilepsy
- Meningitis

Treatment:
- Antitetanus globulin (ATG), 3000 units IM
  Single dose is given

5. Cystic hygroma

- It is also called as lymphangioma of neck (or) cavernous lymphangioma (or) hydrocele of neck
- Congenital cystic swelling, which contains multiple lobules of clear lymph
- It gets filled up with lymph in early week of childhood
- Each lobule is lined by single layer of endothelium

Clinical features:
- Swelling is present at birth in the posterior triangle of neck causing obstructed labour
- Swelling is smooth, soft, fluctant, partially, compressible, brilliantly transilluminant.

- Disfigurement of face of child which is more worrying factor for the patients
- It may get infected forming an abscess which is a tender, warm soft swelling
- Rupture with lymph ooze can occur.

Complications:
- Infection, abscess, septicemia
- Recurrence of cyst in 15% of cases

Treatment:-
- Aspiration of cyst is done
- Drainage of abscess is done
- Pre-operative injection of sclerosants is given

b. Ludwig's angina

Polymicrobial cellulitis of sublingual & submandibular spaces involving the floor of mouth & suprahyoid area on both sides of the neck

Precipitating factors:-
- Tooth extraction
- Submandibular sialadenitis
- Trauma
- Peritonsillar abscess

Predisposing factors:
- Diabetes
- Chemotherapy
- Oral cancer
- Alcohol

Microscopic organisms

Peptostreptococcus, Prevotella species

Clinical features:-

- Diffuse painful swelling, with redness, tenderness
- Suprahyoid area with bull's neck appearance
- Fever, tachycardia, tachypnea
- Difficulty in speech, earache, drooling of saliva & putrid halitosis
- Infection spread via fascial planes
- Air-obstruction, dysphagia & odynophagia

Investigations:-

- CT scan, MRI
- Ultrasound neck

Differential Diagnosis:-

- Sialadenitis
- Lymphadenitis

Complications:-

- Emergency tracheostomy needed for Laryngeal edema
- Septicemia
- Parapharyngeal space infection

Management:-

- Airway maintance
- Parenteral antibiotics
- Hydration & patient
- Removal of cause

SRIVENKATESWARA DENTAL COLLEGE & HOSPITAL
DEPARTMENT OF ORAL & MAXILLOFACIAL SURGERY
THALAMBUR, CHENNAI - 103

7. Warthin's tumor

- Warthins tumor is also called adenolymphoma
- It is a benign parotid tumor, It constitute about 10% of parotid tumors
- It involves only superficial lobe of parotid gland

Etiology :- Smoking & radiation exposer can be cause

Clinical features :-

- Middle aged or elderly males are affected
- Can be bilateral
- Smooth surface, round border with soft, cystic fluctuant swelling in lower pole
- Tumor affects only parotid gland

Investigations :-

- FNAC can be done
- Biopsy done & histology reveals cyst is lined by a bilayered oncocytic epithelium
- An eosinophilic coagulum is present within cyst space

Treatment :-

Superficial parotidectomy which spares facial nerve

SRM DENTAL COLLEGE & HOSPITAL
DEPARTMENT OF ORAL & MAXILLOFACIAL SURGERY
CHENNAI - 133

2. Tracheostomy

Tracheostomy refers to a surgical procedure into trachea through anterior wall to secure airway for oxygenation

Classification:

- Method of insertion: Surgical
  Percutaneous (needle)
- Depending on intended duration
  Temporary & permanent
- Depending on situation demanding the procedure: Emergent tracheostomy
  Urgent tracheostomy
  Elective tracheostomy

Indications:

- Secure & Maintain clear airway in upper respiratory tract obstruction
- Facilitate the removal of bronchial secretions where there is poor cough effort with sputum retention
- To protect airway of patients to prevent aspiration
- Incompetent laryngeal movement during swallowing

Contraindications

- Children under 5 years of age
- Cervical trauma
- Pre-exsisting pathology of larynx eg. carcinoma
- Lack of knowledge about cricothyroidotomy

Procedure :

Step I : Skin from the chin to below the clavicle is sterilizing prepared

Step II : Local anesthesia with vasoconstrictor is infiltrated in skin & deeper tissues

Step III : Skin of the neck over second tracheal ring is identified and an incision is placed horizontally along natural cervical skin crease

Step IV :- Sharp dissection following skin incision is done to cut across platysma muscle

Step V :- Blunt dissection is given parallel to long axis of trachea

Step VI :- A cricoids hook engages the space between cricoids & first tracheal ring pull trachea upward.

Step VII :- Entrance in trachea



Tracheostomy tube

9.

Lymphoma:-

Lymphoma are progressive neoplastic condition of lymphoreticular system which originate from stem cells

Classification:-

- B cell neoplasms
  - Precursor B cell neoplasm:- ALL, LBL
  - Precursor B-cell neoplasm:- Non-Hodgkin lymphoma
- T cell & putative cell neoplasm
- Hodgkin lymphoma
  - Nodular sclerosis
  - Lymphocyte rich
  - Mixed cellularity
  - Lymphocyte depletion

Etiology:-

- Genetic predisposition
- EBV → Epstein barr virus
- Ionizing radiation
- HIV infection

Clinical features:-

- Occurs 20-30 yrs of life
- Enlargement of one group of lymphnodes
- Discrete & rubber in consistency with overlying skin purely mobile
- Dyspnea, & anorexia
- Cyclic fever with severe pruritus
- Intrabony lesion

Investigations

- Blood test
- Lymph node biopsy
- Imaging
- USG

Management :-

Radiotherapy

MOPP Regimen

- Mechlorethamine
- Oncovine
- Procarbazine
- Prednisolone

Ex. Carbuncle

- Caused by extensive infectious gangrene of adjacent hair follicle & subcutaneous tissue by Staphylococcus aureus
- Commonsite followed by Shoulder region

Pathology :

Infection
↓
Development of small vesicles
↓
Sieve like pattern
↓
Red indurated skin with discharging pus
↓
Many fuse together to form a central necrotic ulcer with peripheral fresh vesicle looking like a rosette (or) cribriform pattern

VENKATESWARA DENTAL COLLEGE & HOSPITAL
DEPARTMENT OF ORAL & MAXILLOFACIAL SURGERY
THALAMBUR, CHENNAI - 103

↓

Skin becomes blocked due to blockage of cutaneous vessels

↓

Disease spread to adjacent skin rapidly

Clinical features :-

- Diabetes after 40 years of age
- Surface is red & looks like a red-hot coal
- Fever with chills
- Severe pain & swelling in nape of neck
- Skin on corner of carbuncle
- Large Crater like form ulcer

Complications :-

- Diabetic ketoacidosis
- Septicemia
- Toxemia

Management :-

- Control of diabetes
- Parenteral antibiotics
- Surgical management

Vijaya Priya Harshini

SRI VENKATESWARA DENTAL COLLEGE & ... DEPARTMENT OF ORAL & MAXILLO-FACIAL SURGERY THALAMBUR, CHENNAI - 103

36 1/2 / 10

(11)

(1) TRISMUS:

Trismus (or) "Lock Jaw" is caused due to spasm of muscles of mastication

patients affected by Trismus have Inability to open their mouth.

Normal mouth opening is about 4 cm (or) 40 mm

Based on this measurement, Trismus can be graded as

- ☆ mild >30 mm
- ☆ Moderate 15-30 mm
- ☆ severe <15 mm

Causes:

Spasm of muscles of mastication due to abnormality (or) disturbance in Trigeminal nerve

Infection: This is due to many reasons such as pulpal, periodontal origin around third molar.

Trauma: Fracture of Bone of Jaws

TMJ disorder

Treatment:

Heat Therapy

Analgesics, Anticinflammatory drugs

Physiotherapy

Antibiotic prophylaxis for Infective Endocarditis

Drug	Dose	Route	Timing
Standard Regimen: Amoxicillin	2g	oral	1 hr before procedure
Penicillin allergy:			
Azithromycin	500 mg	oral	1 hr before procedure
Cephalexin	2g	oral	
Clindamycin	600 mg	oral	
Ampicillin	2g	IV	1 hr before procedure

Patients with valvular / Congenital heart Disease who are at high risk of endocarditis should receive prophylactic Antibiotics before undergoing any procedure

Cardiac lesions for which Antibiotic prophylaxis is recommended before Dental procedures are:

- ★ Previous episode of endocarditis
- ★ Patients with prosthetic heart Valves
- ★ Cyanotic Congenital heart Disease

DEPA... ORAL
&
...AL
...ERY
SRI VEN... THALAMUR CHENNAI - 103

5) Biopsy:

Process of obtaining Tissue for diagnosis is Biopsy.

Types.

1) Fine needle Aspiration cytology / FNAC

Cells are Identified here. Hence the name fine needle of 23(or) 24 gauze is used to Introduce into tumor (or) swelling

Without removing, it is passed 3-4 times within lesion in different Directi

Cells are stuck into needle (or) syringe

3-4 smears are made / are dipped in 95% ethyl alcohol solution

eg) Thyroid swelling, (Breast) parotid swelling, lymph nodal swelling

② The Cut Biopsy / Core needle Biopsy.

Yields sufficient tissue to achieve diagnosis

After giving LA, 1-2ml of small skin neck is made

Should not be done in thyroid swellings because thyroid is very vascular

③ Punch Biopsy.

Long Instrument called punch Biopsy forceps used

Done in Cauliflower like lesions (or) exophytic lesions

④ Wedge Biopsy:

Done in malignant ulcer suspect

Edge is selected as it rapidly grows thus hence maximum Cancerous Tissue is present

b) Incision Biopsy
When lymphoma (or) Tuberculosis with matted nodes is suspected

c) Full thickness Excision Biopsy
Suspected recommended & done for suspected malignant melanoma

(4) Tetanus:
Infection Condition Caused by Clostridium Tetanus leading to reflex muscle spasm

Pathogenesis.

Spore
↓
Enters wound
↓
It germinates in anaerobic media releasing Bacteria which multiply
↓
Release of Exotoxins

- Tetanospasmin
  - Through peripheral sheath
  - Circulation
- Tetanolysin
  - ↓ Haemolysin

Clinical features:

Symptoms: Jaw stiffness
Anxiousness
Headache
Dysphagia
Dyspnoea

Signs:
- Trismus
- Risus Sarcodicus
- Neck Rigidity
- Toxic Clonic Convulsion
- Hyperreflexia
- Fenal Tachycardia

Types:
- Early Tetanus
- Latent Tetanus
- Ascending Tetanus
- Descending Tetanus
- Cephalic Tetanus

Different postures in Tetanus:
- Opisthotonus
- Orthotonus
- Empiosthotonus
- Pleurothotonus

Complications:
- Fractured Bone
- Haematoma
- Cauditis
- Toxaemia

Treatment:
- Antitetanus globulin => 3000 units IM single dose
- Antitetanus Serum => 1000 units
  => 1/2 IM, 1/2 IV

IV diazepam 20 mg - 6th hourly
IV Phenobarbitone 30 mg - 6th hourly
IV Chlorpromazine 25 mg => 6th hourly

Ventilator support

5) Cystic Hygroma:

Cavernous lymphangioma

Cystic swelling due to segmentation of portion of Jugular lymph sac from lymphatic system during developmental period.

Present at Birth & Causes obstructed labour

Also called hydrocele of neck

Sites:

Posterior triangle of neck

Cheek

Axilla

Tongue

Groin.

Pathology: Aggregation of cyst like soap bubbles

Clinical feature:

Swelling is smooth, fluctuant soft

Swelling is rapidly increase in size

Treatment:

Aspiration of Contents

Repeated Obstruction ⇒ Aspiration & Tracheostomy

↳ Inflammatory odema of Submandibular region / floor of mouth, commonly due to streptococcal infection

↳ Cause diffuse swelling & Boardy oedema of submandibular Region.

↳ It is Common & severely dl of its advanced malignancy & Causes Trismus.

Precipitating factors:

Carie tooth &
Oral Malignancy
Submandibular Salivary Infection
Chemotherapy

Clinical features:

Fever
Toxicity
Trismus
Intraoral oedema
Pulsed fluctuation

(7) Warthin's Tumor

It is called as Adenolymphoma.

It is Benign Tumor that occurs only in Parotid

It is composed of double layer of Columnar Epithelium

with Papillary Projection into Cystic Space

Clinical feature:

→ Slow growing

→ Smooth, soft

→ Fluctuant swelling

→ Non Tender

→ Common in male

→ Age: 60 years

→ often bilateral

Investigation:

Produces a hot spot in Technetium pertechnetate scan

FNAC.

Treatment: Superficial Parotidectomy

(8) Tracheostomy:

Types: Emergency Tracheostomy

Elective Tracheostomy

Tracheostomy Tube:

Fallen Bivalved Tracheostomy Tube

Jackson's Tracheostomy Tube

Indication:

Co head, neck, facial Injuries

Tetanus

Tracheomalacia

Laryngeal edema.

Technique

Neck of Patient is hyperextended by placing sand bags under shoulder

Vertical (or) horizontal Incision is made

Deep fascia is opened

Strap muscles are retracted laterally

2nd & 3rd tracheal ring are opened & circular opening is made

Tube is placed, tied around neck

Complication:

Early:

Bleeding

Injury to oesophagus

Injury to Recurrent laryngeal nerve

Wrong Placement of Tracheostomy Tube

Intermediate:

Secondary Infection of Wound.

Blockage of Tube

Late:

Tracheal Stenosis

Scar & heloid.

ORAL
AL
THALAMBUR, CHENNAI - 10

(9) Lymphoma

Malignant neoplasm originating in Bone marrow of lymphatic stuctes resulting in proliferation of Lymphocyte

Classification:

Hodgkin's Lymphoma

Non-Hodgkin's Lymphoma.

Etiology:

Infection with Epstein Barr Virus, HIV,

Genetic Predisposition

Clinical feature:

Lymph node Enlargement

Weight loss

Fatigue

Severe Itchy & fever

Weakness

Tachycardia

Anaemia

Shortness of Breath.

Red patche on Skin

Management.

① Chemotherapy

ABVD regimen (Adriamycin, Bleomycin, Vinblastin, Dacarbazine)

Oncovin, cyclophosphoamide, prednisone.

Radiation therapy

Biological therapy: used to help Immune system recognise & attack leukemic cell

eg) Rituximab

Surgical management

Severe affected lymph nodes

Lymphadenectomy

10) Carbuncle:

This is an infective gangrene of Subcutaneous tissue caused by Staphylococcus Aureus

Site

Nape of neck is Commonest site

Skin of site is Coarse & has poor blood supply

Clinical feature:

Patient is diabetic

Severe pain / swelling in neck

Surface is Red, Angry [illegible]

Coal.

Discharging pus [illegible] [illegible] appearance

Development of large [illegible] [illegible] [illegible]

Slough

Treatment

Trimethoprim / sulfamethoxazole - 160/800 mg to 320/1600 mg

Orally 2 time a day

Clindamycin is given

Antibiotic will help in required in [illegible] of [illegible]

surgery is required

Crucible Incision is Preferred because of multiple abscess & extensive subcutaneous [illegible]

Elaborate on.

Levels of Cervical lymph nodes

Level I : Ia → submental lymph nodes
Ib → submandibular lymph nodes

Level II : Lymph node in upper deep cervical region
IIa → Below l in front of line of spinal accessory nerve in upper part
IIb → Above l posterior to line of spinal accessory nerve

Level III : Lymph node in middle cervical region

Level IV : Lymph nodes in lower cervical region

Level V : Lymph node in posterior Triangle Including Supraclavicular Region
V A → Above level of spinal accessory nerve
V B → Below level of spinal accessory nerve

Level VI : Lymph node in midline node

Level VII : Lymph node in mediastinum

Drainage area of lymph nodes.

Level In lymph nodes
Floor of mouth, Anterior Oral Tongue, Anterior mandibular Alveolar Ridge, lower lip.

Level In Lymph node
Oral Cavity, Anterior Nasal Cavity, Soft tissue of midface, Submandibular gland

Certified

A. [signature]
PRINCIPAL
SRI VENKATESWARA DENTAL COLLEGE & HOSPITAL
OFF. OMR NEAR - NAVALUR
THALAMBUR, CHENNAI-600 130.

Level Ia & Ib lymph nodes:
Oral Cavity, Nasal Cavity, Oesophagus, Nasopharynx, Larynx, Parotid gland

Level II lymph node:
Oral Cavity, Oesophagus, Nasopharynx, larynx

Level III lymph node:
Scalp, Parotid gland, Nasopharynx, Thyroid gland

Level IV lymph nodes:
Scalp, Parotid gland, Nasopharynx, Thyroid gland

Level VI lymph nodes:
Thyroid gland, glottis & subglottis larynx, apex of pyriform sinus, Cervical esophagus

2) Shock:
→ Acute clinical Syndrome characterised by hypoperfusion & severe dysfunction of vital organs

Pathophysiology of cardiogenic shock

Decreased effective Circulatory blood volume

↓

Decreased Cardiac output

↓

Certified

PRINCIPAL
SRI VENKATESWARA DENTAL COLLEGE & HOSPITAL
OFF. OMR NEAR - NAVALUR
THALAMBUR, CHENNAI-600 130

Decreased Blood flow

↓

Decreased supply of oxygen

↓

Anoxia & ischemia

↓

Neurogenic Shock.

If occurs due to spinal cord injury which lead to dilation of splanchic vessels

There will be bradycardia, hypotension, Arythmia, decreased Cardiac output

Clinical feature:

History of emotional stress

Bradycardia

Tachypnea

Pacing

Treatment:

Control BP using Vasoconstrictor

Oxygen Administration

Haemodynamic should be Maintained

Accident dead

Certified

PRINCIPAL
SRI VENKATESWARA DENTAL COLLEGE & HOSPITAL
OFF. OMR NEAR - NAVALUR
THALAMBUR, CHENNAI-600 130.

Fluid Therapy given

Intravenous Methylprednisolone Therapy done

Dopamine & phenylephrine used

Certified

PRINCIPAL
SRI VENKATESWARA DENTAL COLLEGE & HOSPITAL
OFF. OMR NEAR - NAVALUR
THALAMBUR, CHENNAI-600 130.